

An audit of IO6 YAG Laser capsulotomies done between January 2017-December 2017 in St. Joseph Eye hospital, Mgbirichi, Owerri, Imo state and Viandra Eye clinic, Port Harcourt, Rivers State of Nigeria

Abstract

Aim: To audit the YAG Laser Capsulotomy procedures done over a 12 month period from January to December 2017.

Objective: To review YAG LASER capsulotomies done over a 12 months period from January 2017 –December 2017

Method

The audit was retrospective in nature , involving collation of parameters such as age, sex, presenting visual acuity, post laser visual acuity, complications and post operative management from the patient records .The lasers were performed with SYL 9000 Ophthalmic yttrium aluminum garnet (YAG) Laser systems [Lightmed Corporation, Taiwan]. This is a class 3b Laser with a wavelength of 1064nm and Q-switched operational mode and a spot size of 8 um.

Results:

The audit involved 106 subjects. The mean age was 56.76 years. Fifty nine (55.7%) subjects were females while 44.3% were males. Eleven (10.4%) subjects had bilateral neodymium-doped yttrium aluminum garnet ND YAG laser treatment while 89.6% had unilateral treatment. Seventy five (72.8%) of the subjects had visual improvement following

treatment. Seventy four (69.8%) had less than 3mJ quantum of energy and only 5.7% required repeat treatment. Fifty (47.2%) had between one to three days post op treatment with anti-inflammatory and/or pressure reducing drugs.

Conclusion:

Use of low energy in ND YAG laser treatment of Posterior Capsule Opacification offers good visual outcome, precludes the complication associated with higher energy treatment and does not necessarily lead to repeat treatment.

Key Words

Opacification, Posterior capsule, Q-switched, YAG Laser

Introduction:

Posterior capsule opacification (PCO) is the most common complication following cataract surgery. ^[1, 2] It can occur between few months and many years after implantation of intraocular lenses (IOLs), with incidence figures ranging from <5% to as high as 50%. ^[1] It results from the proliferation and migration of residual lenticular epithelial cells. ^[3-4] It commonly affects younger patients due to higher cell proliferation rates. ^[5]

Neodymium:yttrium-aluminum-garnet (Nd:YAG) laser capsulotomy is the standard treatment for PCO ^[6-7]. Nd:YAG laser capsulotomy has been found to be safe and effective, but the procedure could be complicated by retinal detachment ^[8-9], cystoid macular edema ^[9], and rise in intraocular pressure (IOP) ^[10,11]. Rise in IOP was said to be due to an increased amount of aqueous particles following Nd:YAG laser capsulotomy ^[12].

The amount of energy used could be associated with some complications. A high amount of energy may increase the risk of retinal detachment ^[13]. Ari et al. ^[14] stated that when a total energy

level less than 80 mj is used, the severity and duration of increased IOP and macular thickness are less. A study showed that the visual improvement of PCO following treatment with ND-YAG laser is significant¹⁵.

The visual outcome and extent of complications may be affected by the size of the capsulotomy and amount of energy used .For instance, larger capsulotomy openings may increase risk of cystoid macular edema, vitreous prolapse, and retinal detachment^[13,16]or cause posterior IOL dislocation leading to hyperopia^[17].

Consensus on Yag laser capsulotomy procedures include waiting until 3 months post cataract surgery before it is performed, and checking the pre operative visual acuity which should be 6/9 or worse. A dilated pupil with eye drop is recommended such as Tropicamide 1% and or Phenylephrine 2.5% prior to the laser procedure. It is also recommended that low energy is used (1-3mj)with Q-switched, single pulse of less than 10-20 nanoseconds. Pre and post laser intraocular pressures should be checked and a drop of apraclonidine or other intra ocular pressure lowering drop should be used. An anti-inflammatory eye drop can be used for 3-5days.^[18].

Methods

All patients that underwent Nd:YAG Laser capsulotomy procedure in St. Joseph Eye hospital, Mgbirichi.Owerri Imo State and Viandra Eye clinic Port harcourt Rivers State of Nigeria were included from January 2017 to December 2017. The lasers were performed with SYL 9000 Ophthalmic YAG Laser systems [Lightmed Corporation, Taiwan]. This is a class 3b Laser with a wavelength of 1064nm and Q-switched operational mode and a spot size of 8 um.

Preoperatively:This was done as an outpatient procedure.The procedure to be carried out was properly explained to the patient.Visual acuity was assessed after which eyes were dilated with 0.5% Tropicamide

Intraoperatively:

Patient was comfortably seated with head placed on chin rest. Procedure was done without contact lens. Local anaesthetic agent (Proxymethacaine 0.5%) was instilled into the eye. Laser setting was at low energy and titrated upwards

Post operatively:

Intraocular pressure was checked and if raised above 21mmHg, a drop of Apraclonidine was instilled. Steroidal eyedrop (Dexamethasone 0.1%) was instilled for 3-5 days

Our audit was retrospective in nature, involving collation from the patient records of the parameters such as age, sex, presenting visual acuity, post laser visual acuity, complications and post operative management. The procedures were performed by 2 Surgeons, VO and CU, and only patients who attended post operative follow were included. The initial list was obtained from the Laser record book, and case notes retrieved from medical records unit.

Results

Table 1 showed that a total of 106 patients who had posterior capsular opacification underwent ND Yag Laser capsulotomy in the one year period of this study. The ratio of male to female in the study was 5:4. The mean age of patients was 56.79 ± 23.83 years while the age range was 5-88 years.

Table 1: Sociodemography

	Frequency (n = 106)	Percent (%)
Sex distribution		
Female	59	55.7
Male	47	44.3

Age(Mean and Range)	Mean (Standard deviation)	Range
Age of Patients	56.79 years (23.83years)	5 – 88 years

Table 2 showed that of all the patients in the study,67.9% presented with co-morbidities in addition to PCO .The commonest comorbidity was Glaucoma (23.6%) followed by macular degeneration and Diabetic retinopathy which both constituted 18.9%.

Co-Morbidity Type	Frequency (n = 106)	Percent
No Co-morbidity	34	32.1
Glaucoma	25	23.6
Macular degeneration	20	18.9
Diabetic Retinopathy	20	18.9
Ocular Hypertension	3	2.8
Exotropia	2	1.9
Uveitis	2	1.9
Optic Atrophy	1	0.9
Anisometric Amblyopia	1	0.9
Hyphaema	1	0.9
Anterior Synaechiae	1	0.9
Bilateral esotropia	1	0.9
Bilateral Pseudophakia	2	1.9
Optic Neuropathy	1	0.9
Bnd Keratopath	1	0.9
Retinal tear	2	1.9

The commonest post op medication taken by subjects were Efemoline(47.2%), Timolol(38.7) and Optodex (13.2%) as shown in table 3.

Table 3:Post-operative Medication

Post-operative Medication	Frequency (n = 106)	Percent
Efemoline	50	47.2
Timolol	41	38.7
OPTodex	14	13.2
Dexipro	2	1.9
Diamox	1	0.9
Mydriacyl	1	0.9
Optimal	1	0.9

Table 4 showed that 47.2% of the subjects had the post op medication between 1-3 days while 52.8% had it for more than 3 days while the mean quantum of energy used was 2.7mJ and mean frequency of shots was 91.0 times. Sixty nine(69.8%) of subjects had less than 3mJ quantum of energy

Table 4: Mean, standard deviation and range of continuous variables in the Audit


Characteristics	Mean (Standard deviation)	Range
Quantum of Energy	2.7mJ (1.0mJ)	0.9 – 8.3mJ
Frequency of Shots	91.0 times	13 – 279 times

(59.0times)

Percentage of Recipients	Energy Quantum	Percentage
	>3mJ	20.2%
	<3mJ	69.8%

Fig 1 showed that the age range of 61-80 years constituted more than half of the entire study population followed by those less than 20 years(17%)

Fig 1:Age Distribution of Patients



20.00%

10.00%

0.00%

Less than 20
years

21 – 40
years

41 – 60
years

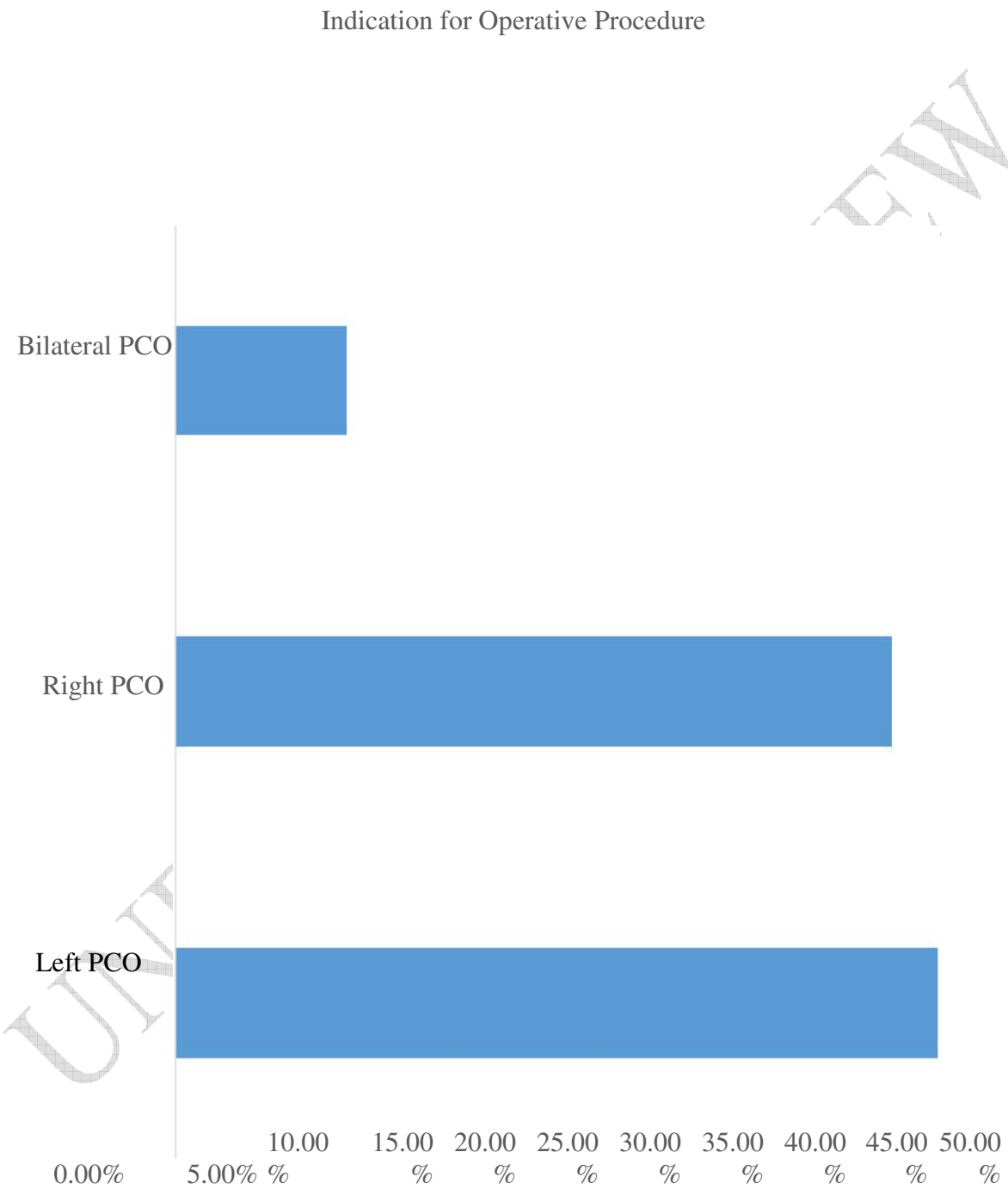
61 – 80
years

Greater
than 80
years

UNDER PEER REVIEW

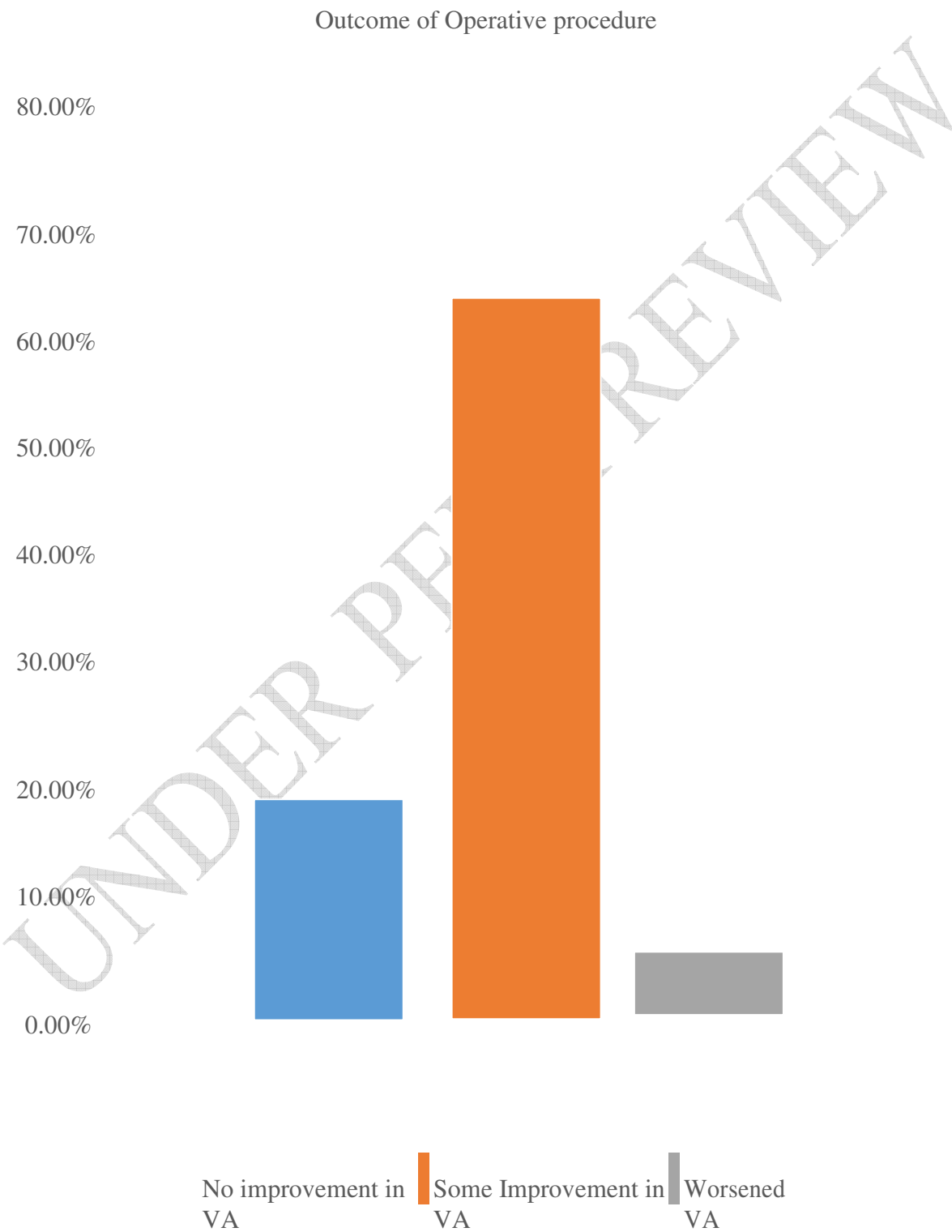
Fig 2 showed that 46.2% had left PCO, 43.4% had right PCO while 10.4% had bilateral PCO

Fig 2: Indication for Operative procedure



Following ND Yag Laser capsulotomy, 72.8% had improvement of visual acuity, 22.3% had no improvement while 4.9% had worsened visual acuity as shown in fig 3.

Fig 3: Outcome of operative procedure



Discussion:

The twelve months audit of Nd: YAG laser showed that 106 patients went through the treatment. The mean age was 56.79 years, this is similar to the age group in a similar study.¹⁶ This is expected because senile cataract is common in this age group and the common indication of Nd:YAG laser therapy when surgery is complicated by PCO.¹ Though PCO is common among children but the commonest age group to undergo this procedure were 61-80 years because the audit cut across 5-88 years age range. The patients grouped as less than 20 years of age were however the second most treated aged group.

There were more females in this study. The higher female cohort may be a reflection of demographics of the larger population, and the fact that women tend to access health services more than males and have a higher life expectancy. Seventy five (72.8%) subjects had visual improvement following the procedure as has been established in previous study¹⁵. The later findings are due to the presence of co-morbidities. To achieve this, the energy level had to be kept at less than 3mJ in 69.8% of the subjects since it has been reported that higher energy levels may be associated with complications like retinal detachment,¹³ increased severity and duration of increased IOP and macular thickness¹⁴ The use of low energy level followed the standard international guideline for Nd: YAG laser which stated that low energy should be used [1-3mj], using Q-switched single pulse. Higher amount of energy and increased number of shots could not have conferred any advantage as 94.3% of subject did not need a repeat procedure.

Fifty (47.2 %) subjects had about 3 days post op treatment which is still in keeping with international guideline that stipulates 3-5 days of post op anti-inflammatory drops with a two weeks review. The difference in duration of use of anti-inflammatory agents is in cases where the procedure is prolonged and higher energy had been used. The use of post op anti-inflammatory

and pressure reducing drops was to reduce pressure which had been reported to be due to release of vitreous particles following laser shots.¹²

The audit did not look at the intra-ocular pressure measurements pre-operatively and post operatively, however 38.7% of our cohort required post operative Timolol eye drops, which was used as a prophylactic due to the difficulty in obtaining Apraclonidine eyedrops in our environment. These were patients whose procedures were prolonged and higher energy was used.

Majority of the patients had satisfactory visual outcomes, whilst the presence of co-morbidities such as macular degeneration , diabetic retinopathy and chronic glaucoma were responsible for poor outcome in those with poor post operative result. The audit revealed areas where the guidelines are being followed such as criteria for performing capsulotomy and indeed areas that require improvement clinically such as recording of pre and post operative intraocular pressures and stream lining the use of post operative medications. A re-audit is planned for 1 year.

CONCLUSION:

Our audit has shown that the guidelines for performing and managing patients are being followed, there are certain areas that required improvement, such as checking pre-op and post op intra ocular pressures, thus identifying those requiring pressure lowering eyedrops.

Reference

1. Raj SM, Vasavada AR, Johar SRK, Vasavada VA, Vasavada VA. Post-operative capsular opacification: a review. Int J Biomed Sci Master Publ Group. 2007;3:237–50.
2. Vasavada A, Shetal MR, Shah GD, Nanavaty MA. Posterior Capsule Opacification After Lens Implantation. Expert Rev Ophthalmol. 2013;8:141–9.

3 Apple DJ, Solomon KD, Tetz MR, Assia EI, Holland EY, Legler UF, Tsai JC, Castaneda VE, Hoggatt JP, Kostick AM. Posterior capsule opacification. *Surv Ophthalmol.* 1992;37(2):73-116.

4 Argento C, Zarate J. Study of the lens epithelial cell density in cataractous eye operated on with extracapsular and intracapsular techniques. *J Cataract Refract Surg.* 1990; 16(2):207-10.

5 Mackool R, Chatiawala H. Pediatric cataract surgery and intraocular lens implantation: A new technique for preventing or excising postoperative secondary membranes. *J Cataract Refract Surg.* 1991;17(1):62-6.

6. Fankhauser F, Roussel P, Steffen J. Clinical studies on the efficiency of high power laser radiation upon some structures of the anterior segment of the eye. First experiences of the treatment of some pathological conditions of the anterior segment of the human eye by means of a Q-switched laser system. *International Ophthalmology.* 1981; 3(3)129-39.

7 Murrill C, Stanfield D, Van Brocklin M. Capsulotomy. *Optometry Clinics* 1995; 4(4): 69-83.

8 Javitt J, Tielsch J, Canner J et al. National outcomes of cataract extraction: increased risk of retinal complications associated with Nd : YAG laser capsulotomy. *Ophthalmology.* 1992;99(10):1487-98.

9 Steinert R, Puliafito C, Kumar R, Dudak S, Patel S. Cystoid macular edema, retinal detachment, and glaucoma after Nd : YAG laser posterior capsulotomy. *The American Journal of Ophthalmology.* 1991;112(4): 373-80

10 Channell M, Beckman M. Intraocular pressure changes after neodymium-YAG laser posterior capsulotomy. *Archives of Ophthalmology.* 1984;102(7):1024-26

- 11 Stark W, Worthen D, Holladay J, Murray G. Neodymium : YAG lasers: an FDA report. *Ophthalmology*.1985 ;92(2). 209–12.
- 12 Lee M, Lass J. Rapid response of cystoid macular edema related to Nd : YAG laser capsulotomy to 0.5% Ketorolac. *Ophthalmic Surgery Lasers and Imaging*.2004; 35(2): 162–4.
- 13 Ranta P, Tommila P, Kivela T. Retinal breaks and detachment after neodymium: YAG laser posterior capsulotomy: five years incidence in a prospective cohort. *J Cataract Refract Surg*. 2004;30(1):65-73.
- 14 Ari S, Cingü A, Sahin A, Çinar Y, Çaçı I. The effects of Nd : YAG laser posterior capsulotomy on macular thickness, intraocular pressure, and visual acuity. *Ophthalmic Surg Lasers Imaging*2012; 43: 395–400.
- 15 Oztas, Z. , Palamar, M. , Afrashi, F. and Yagci, A. Posterior capsulotomy and anterior segment. *Clin Exp Optom*.2015; 98: 168-71
16. Patton N, Aslam T, Bennett H, Dhillon B. Does a small central Nd:YAG posterior capsulotomy improve peripheral fundal visualisation for the vitreoretinal surgeon? *BMC Ophthalmol*. 2004;4:8.
17. Findl O, Drexler W, Menapace R, Georgopoulos M, Rainer G, Hitzemberger CK, et al. Changes in intraocular lens position after neodymium:YAG capsulotomy. *J Cataract Refract Surg*. 2000;26(1):5-6
18. Operators manual for the SYL 9000 Ophthalmic YAG Laser System .51-57.
19. Servet C, Yasemin F, Halil I, Eynep D, Muammer O, Nursen O. The influence of size and shape of Nd:YAG capsulotomy on visual acuity and refraction. *Arq. Bras. Oftalmol*.2015;78(4)