

# Original Research Article

## FREQUENCY OF SATISFACTORY OUTCOME AFTER SURGICAL MANAGEMENT IN ISOLATED ORBITOZYGOMATIC FRACTURES”

**Objective:** To determine the frequency of satisfactory outcome after Surgical Management in Isolated Orbitozygomatic fractures.

**Study Design:** Descriptive study.

**Place and Duration:** Oral Maxillofacial Surgery Department of Dentistry, Liaquat University of Medical Health Science, Jamshoro, from 11<sup>th</sup> August 2020 to 10<sup>th</sup> March 2021.

**Methodology:** Total 87 patients of Isolated Orbitozygomatic fractures with Enophthalmos and or Diplopia were included. All patients were operated, open reduction and internal fixation of zygoma at 3 points. Postoperatively Diplopia was ruled out by a range of eye movements and Enophthalmos was measured by Hertel Exophthalmometer. Final assessment was done after six weeks postoperatively. Descriptive statistics were calculated. Stratification was done and poststratification chi square test or t-test was applied. P-value  $\leq 0.05$  was considered as significant.

**Results:** There was 85.1% male and 14.9% female. Mean age was  $33.45 \pm 7.93$  years. 73.6% were classified as ASA-I and 26.4% were classified as ASA-II. At first, third and sixth week, 4.6% patients were found with positive upward gaze, 2.3% with positive down gaze, 0% with positive horizontal gaze and 2.3% with positive secondary peripheral gaze while 85.1% with  $< 3$  mm Enophthalmoson Hertel Exophthalmometer and 13(14.9%) with  $> 3$  mm Enophthalmoson Hertel Exophthalmometer. The satisfactory outcome was 88.5%.

**Conclusion:** Our study results showed 88.5% satisfactory outcome. The long-term prognosis after repair of zygomaticomaxillary complex fractures is very good.

**Keywords:** Satisfactory Outcome, Surgical Management, Isolated Orbitozygomatic Fractures

### 1. INTRODUCTION:

The orbit is an integral part of the Zygomatic complex. A vast majority of zygomatic fractures involve the Orbit. Fractures involving the orbit are divided into isolated (pure) and complex (impure) fractures, isolated only involve the orbital wall, which account for 4% to 16% of all facial fractures, complex fractures are those that extend outside the orbit, such as zygomatic complex fracture and nasoethmoidal fracture. They have been reported to account for 30% to 55% of all facial fractures. The zygomatic complex fracture with orbit involvement may cause Enophthalmos and Diplopia [1] [2].

The prominent and convex shape of zygoma make it possible to traumatic injury and these fractures are most commonly occurring fractures of the orbit [3]. Latha et al reported (66%) had satisfactory results with respect to Diplopia and Enophthalmos after surgical management in blowout fractures [4]. Khreisat M. H in 2011 reported in fifty study group patients out of these nine patients presented with Diplopia, resolved within three weeks after surgical intervention for six patients (66.7%). Two cases took one week (22.2%) to resolve, and one patient recovery occurred after twelve weeks [3].

Amrith S, et al reported in 2010, 63 study group of patients out of these 10(15.6%) patients had Diplopia but none after surgery and Enophthalmos was documented in 12 (20%) patients preoperatively, surgery made significant improvement to Enophthalmos (P  $< 0.001$ , McNemar test). Diplopia could be related to

entrapment of the fibrous intermuscular septa or the muscle itself in the fracture site. Occasionally it could be related to muscle trauma or muscle paralysis due to trauma to a cranial nerve [5].

In developing nations road traffic accidents are most frequent etiology and in developed countries assaults are most frequent Etiology[6]. Ocular trauma may involve the eye lids, lacrimal canaliculi, orbital wall, periorbital structures, conjunctival, cornea, sclera, extraocular muscles [7]. Diplopia and Enophthalmos, or restriction of gaze are often used to determine the necessity for repair of an orbital wall fracture, such ocular injuries are inspected and examined by complete Ophthalmic examination including Ocular Motility and computed tomography (CT) scan. A Hertel Exophthalmometer standard method for measuring the degree of Enophthalmos [8].

Surgical intervention is recommended usually within two weeks, to replace the fractured bone segments and correct soft tissue distortion. Even after the surgical repair, patients may suffer from permanent complications such as persistent Diplopia, visual loss dystopia, Enophthalmos, scarring, and Sensory disturbances [9].

There is limited published data by Oral Maxillofacial surgeons in our local literature regarding the Enophthalmos and Diplopia in association with Orbitozygomatic fractures and outcome of the surgical management, it as we have different lifestyles in terms of dietary habits, socio-economic status as compare to other population it may give us different results in our population. This study carried out to illustrate our experience in patients who managed with surgery for their Orbitozygomaticfractures and described the patient characteristics in relation to the Ocular Motility and Enophthalmos after surgical repair. If the results of my study will show high frequency of satisfactory outcomes the practice of this technique will be applied in my future.

## 2. MATERIAL AND METHODS

This prospective cross-sectional study was conducted from 11<sup>th</sup>August 2020 to10<sup>th</sup> March 2021,after gaining approval of the Ethical Research Committee of Liaquat University of Medical and Health Sciences Jamshoro, Hyderabad Pakistan. Non-probability consecutive sampling was used for the study. The Inclusion Criteria was clinically and radio graphically confirmed isolated Orbitozygomatic fractures with Enophthalmos and or Diplopia, patients report within 72 hours of injury , age range from 12 to 60 years of either gender and the exclusion of cases done if patients not willing to participate for this study, patients having any systematic illness as per criteria of ASA III , IV which hampers the general anesthesia or surgical intervention on the basis of medical record and history, any previous history of maxillofacial trauma.

All patients were operated under general anesthesia, open reduction, and internal fixation of zygoma at 3 points (across frontozygomatic suture, the inferior orbital rim, and lateral midfacial buttress) was done. The orbital contents supported as for simple orbital floor fracture if the size of orbital floor fracture was large, repaired with preformed titanium mesh.

Postoperatively Diplopia was ruled out by a range of eye movements in all directions of gaze where patient fixed one eye at 9 points of gaze and by Diplopia charting, and Enophthalmos was measured by Hertel Exophthalmometer. All data was recorded in pre-designed proforma, preoperatively and postoperatively one week, postoperatively three weeks and final assessment after six weeks postoperatively.

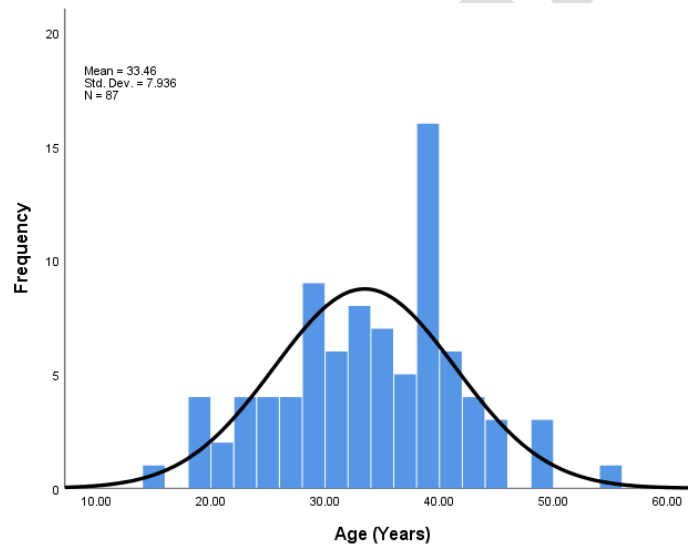
## 2.1. DATA ANALYSIS PROCEDURE

Data were entered and analyzed using computer software SPSS version 20.0. The Mean and Standard deviation were calculated for quantitative variables like age and duration of disease. If the data were not normally distributed, then median was calculated. Frequency and percentage were calculated for qualitative variables like gender, recovery of Diplopia and recovery of **Enophthalmos**. Effect modifier like age, gender and duration of disease were controlled through stratification, post stratification chi-square and T-test were applied by taking P-value  $<0.05$  or  $<0.01$  as significant. Total 87 patients of either gender with age 12 years to 60 years meeting inclusion criteria of study were evaluated to determine the frequency of satisfactory outcome after surgical management in Isolated Orbitozygomaticfractures.

Descriptive statistics were calculated using SPSS version 22. Stratification was done and post stratification Chi square test was applied to observe the effect of modifiers on outcome. P value  $\leq 0.05$  was considered as significant.

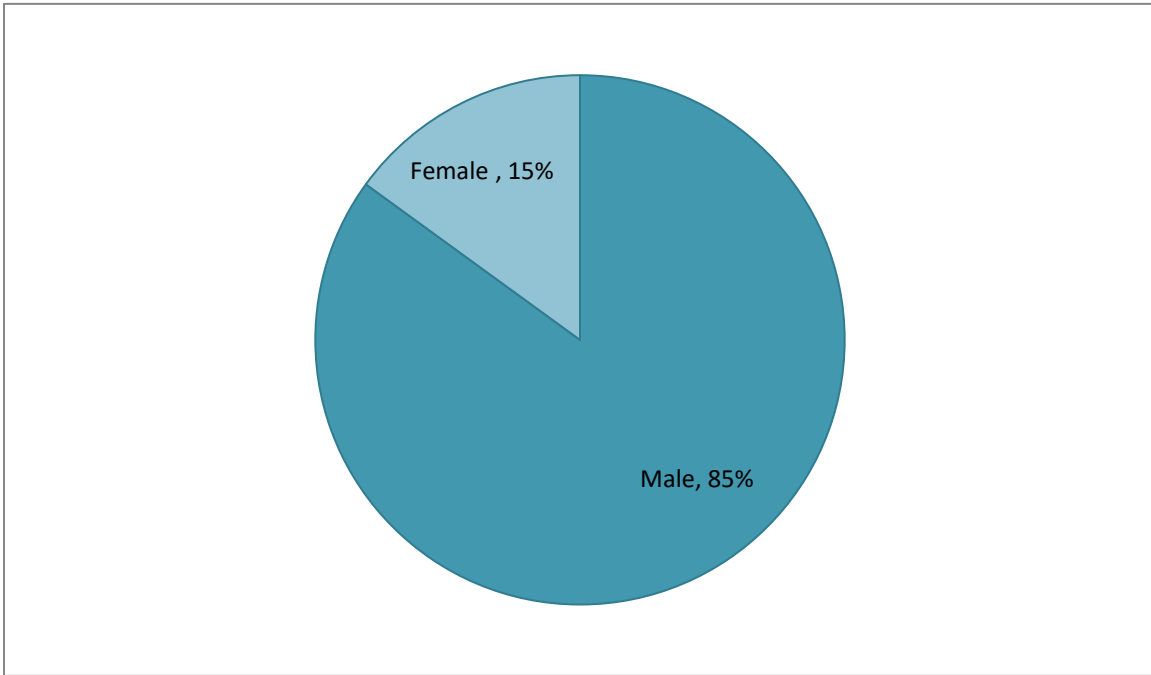
## 3. RESULTS

The mean age of patients presented in this study as the overall mean age of patients was  $33.45 \pm 7.93$  years (Figure 1).



**Fig.1. Age Distribution**

In this study male were 74 (85.1) while females were 13(14.9). Male female ration 6:1 (Figure 2).



**Fig. 2. Frequency Distribution of Gender (n = 87)**

The cause of facial injuries are documented in Table 1 and accounted as 70(81%) occurred due to road traffic accidents ,followed by assault 9(10.3%) and fall 5(5.7%) respectively.

**Table 1. Frequency Distribution of Etiology (n= 87)**

	<b>Frequency (%)</b>
<b>Road Traffic Accident</b>	70(80.5)
<b>Assault</b>	9(10.3)
<b>Fall</b>	5(5.7)
<b>Sports</b>	2(2.3)
<b>Gunshot</b>	1(1.1)
<b>TOTAL</b>	<b>87</b>

Details of Diplopia and Enophthalmos are presented in Table 2 and 3. Diplopiapre operative assessment, 44.8% were found with positive upward gaze, 18.4% with positive down gaze, 0% with positive horizontal gaze and 31% with positive secondary peripheral gaze while 62.1% with < 3 mm Enophthalmos and 37.9% with > 3 mm Enophthalmos seen preoperatively.

At first week, 4.6% patients were found with positive upward gaze, 2.3% with positive down gaze, 0% with positive horizontal gaze and 2.3% with positive secondary peripheral gaze while 85.1% with < 3 mm Enophthalmos and 13(14.9%) with > 3 mm observed.

**Table 2. Frequency Distribution of Diplopia Pre And PostOperative Assessment (n=87)**

<b>Gaze</b>	<b>Condition</b>	<b>PreOperative</b>	<b>PostOperative 1<sup>st</sup> week</b>	<b>Post Operative 3<sup>rd</sup> week</b>	<b>PostOperative 6<sup>th</sup> week</b>
<b>Upward</b>	<b>Positive</b>	39 (44.8)	4 (4.6)	4 (4.6)	4 (4.6)
	<b>Negative</b>	48 (55.2)	83 (95.4)	83 (95.4)	85 (97.7)
<b>Down</b>	<b>Positive</b>	16 (18.4)	2 (2.3)	2 (2.3)	2 (2.3)
	<b>Negative</b>	71 (81.6)	85 (97.7)	85 (97.7)	85 (97.7)
<b>Horizontal</b>	<b>Positive</b>	0 (0)	0 (0)	0 (0)	0 (0)
	<b>Negative</b>	87 (100)	87 (100)	87 (100)	87 (100)
<b>Secondary Peripheral Gaze</b>	<b>Positive</b>	27 (31)	2 (2.3)	2 (2.3)	2 (2.3)
	<b>Negative</b>	60 (69)	85 (97.7)	85 (97.7)	85 (97.7)

**Table 3. Frequency Distribution of Pre and PostOperative Enophthalmos (n=87)**

<b>Enophthalmos</b>	<b>PreOperative (%)</b>	<b>1<sup>st</sup> week (%)</b>	<b>3<sup>rd</sup> week (%)</b>	<b>6<sup>th</sup> week (%)</b>
<b>&lt;3 mm</b>	54 (62.1)	74 (85.1)	74 (85.1)	74 (85.1)
<b>&gt;3 mm</b>	33 (37.9)	13 (14.9)	13 (14.9)	13 (14.9)
<b>TOTAL</b>	<b>87</b>	<b>87</b>	<b>87</b>	<b>87</b>

At third week, 4.6% were found with positive upward gaze, 2.3% with positive down gaze, 0% with positive horizontal gaze and 2.3% with positive secondary peripheral gaze while 85.1% with < 3 mm Enophthalmos and 14.9% with > 3 mm Enophthalmos respectively.

At sixth week, 4.6% were found with positive upward gaze, 2.3% with positive down gaze, 0% with positive horizontal gaze and 2.3% with positive secondary peripheral gaze while 85.1% with < 3 mm Enophthalmos and 14.9% with > 3 mm Enophthalmos respectively.

In our study, satisfactory outcome was found for 88.5% patients as presented in Table-4.

**Table 4. Frequency Distribution of Satisfactory Outcome (n= 87)**

	Frequency (%)
<b>Yes</b>	77 (88.5)
<b>No</b>	10 (11.5)
<b>TOTAL</b>	<b>87</b>

The detailed descriptive statistics of age according to satisfactory outcome are also calculated and presented in Table-5. Stratification with respect to gender, age was done to observe effect of these modifiers on satisfactory outcome. P-value  $\leq 0.05$  was considered as significant.

**Table 5. Descriptive Statistics of Age According to Satisfactory Outcome (n= 87)**

	Yes (n=77)	No (n=10)
<b>Mean</b>	33.70	31.60
<b>SD</b>	8.17	5.79
<b>Median</b>	35.00	32.50
<b>Range</b>	39	18
<b>Minimum</b>	15	21
<b>Maximum</b>	54	39

The results showed that there was no significant association of satisfactory outcome with gender ( $p=0.159$ ), age ( $p=0.354$ ) are presented from Table-6 and Table-7.

**Table 6. Frequency and Association of Satisfactory Outcome According to Gender (n= 87)**

	SATISFACTORY OUTCOME			P-Value
	Yes	No	Total	
<b>Male</b>	64 (86.5)	10 (13.5)	74	0.159**
<b>Female</b>	13 (100)	0 (0)	13	
<b>TOTAL</b>	77	10	87	

Chi Square Test was applied.

P-value  $\leq 0.05$  considered as significant.

\*\*Not Significant at 0.05 levels

**Table 7. Frequency and Association of Satisfactory Outcome According to Age Group (n=87)**

	SATISFACTORY OUTCOME			P-Value
	Yes	No	Total	
≤35 years	42 (85.7)	7 (14.3)	49	0.354**
>35 years	35 (92.1)	3 (7.9)	38	
<b>TOTAL</b>	<b>77</b>	<b>10</b>	<b>87</b>	

Chi Square Test was applied.

P-value≤0.05 considered as significant.

\*\*Not Significant at 0.05 levels.

#### 4. DISCUSSION:

The most common indications for open reduction and internal fixation of **Orbitozygomatic** fractures are facial asymmetry, trismus, orbital deformities (i.e., enophthalmos, hypophthalmus), and Diplopia. These signs and symptoms usually indicate a sufficient displacement of the zygomatic bone or orbital floor to warrant surgical management. Simple, nondisplaced fractures can often be treated conservatively with careful observation and reexamination after the posttraumatic swelling decreases [10].

The presence of Diplopia, enophthalmos, or restriction of gaze are often used as criteria for repair of fractures of the orbital wall [11] [12]. Enophthalmos rarely occurs in the early stage of trauma, but it is the most valuable indicator for deciding on surgical reconstruction of the orbital wall fracture. Diplopia and restriction of Eye Motility may be temporary findings that occur as a result of swelling, contusion, or intramuscular hematoma, both of which resolved with time. However, there is a lack of valid diagnostic criteria for predicting whether orbital wall fracture may result in functional impairment [13].

According to several studies, quantifying the area of the bone defect on CT scans in patients with orbital wall fracture is essential for deciding on a treatment approach and is often used for deciding whether to perform surgery. Attempts have also been made to identify the correlation of enophthalmos with such factors as Diplopia, Eye Motility, and the size of the bone fracture. It has been shown, however, that the degree of enophthalmos only had a correlation with the size of the bone fracture [13]. In an actual clinical setting, however, it is not easy to collect data from many cases of orbital fracture that have been left untreated for long periods of time [5]. Chuong and Kaban [14] have reported that 58% of their OZC maxillary complex fractures required an open reduction and orbital floor exploration. Enophthalmos was a presenting symptom in 20% of the patients.

The higher frequency of maxillofacial injuries among males compared to females is a universal finding in all previous studies [15] [16] [17] [18] [19] [20]. The male:female ratio (3.16:1) in a study [6] was lower than what has been reported by Cavalcanti et al. [17], Cheema and Amin [18] and Ugboko et al. [21] and this finding is in accordance with previous studies from India [20] [22] as well as from other parts of the world [16] and [23]. This may be due to the active participation of females in society and consequently they are more susceptible to road traffic accidents and assault. Cultural and socioeconomic characteristics have significant influence in gender distribution of maxillofacial injuries.

In countries such as Austria [24], Japan [23] and Jordan [16] where females participate widely in social activities, the male-to-female ratios for the occurrence of maxillofacial trauma were reduced to 2:1. Conversely, Ahmed et al. [15] reported higher ratio of men to women than other studies (11:1), mostly due to cultural features of the United Arab Emirates, where men usually do outdoor work, and few women drive.

A study [6] revealed that the peak incidence of maxillofacial fractures occurred in the 21-30-year age group, with mean age of 29.6 years. Many surveys of maxillofacial fractures reported the same results concerning age [15] [16] [17][25][26]. The possible explanation for this was that younger persons involved in intense social interaction and higher rate of mobility, drive motor vehicles carelessly making them more susceptible to road transport accident and interpersonal assault. Road traffic accidents remain the most frequent cause in the many developing countries, including India [17] [18] [20] [21] [26] [27] [28].

Previous studies have reported that the degree of enophthalmos can be predicted to be approximately 2 mm when the area of the bone defect is 1.9 cm<sup>2</sup> in cases of medial orbital wall fracture [5] [13]. Diplopia, or double vision, does not in itself mean entrapment of an extraocular muscle, as global orbital edema may diminish eye movement. Back et al have shown that >80% of cases that initially present with decreased eye excursion resolve within a short period of time [29].

In a study [11], zygomatic fractures were managed with closed reduction in 12% cases. The literature indicates that 10%–50% of all zygomaticomaxillary complex fractures require no surgical intervention [11]. Mohammadinezhad C resorted to minimal invasive treatment for isolated zygoma fractures in the form of hook reduction and fixation with single miniplates. He demonstrated good aesthetic results in his case series of 17 patients [31].

Bezuhly M et al., have shown in their study that Gillies elevation combined with percutaneous Kirschner wire fixation provides facial contour restoration that is not significantly different from that of open reduction and internal fixation, with less soft-tissue morbidity. The technique is safe, easy to learn, and easy to perform, and should be considered in cases of isolated simple zygoma fractures [32]. In most countries, traffic accidents are the leading cause of orbital fractures [33].

## **5. STUDY LIMITATIONS:**

The main limitation of our study was the small sample size. Other limitations of the present study include a single-center experience and nonrandomized study design. It was conducted with urban environment; therefore, the results might not be general to larger populations.

## **6. CONCLUSION:**

Orbitozygomatic fractures injuries are very common in trauma patients. Thorough multidisciplinary evaluation is a must to rule out concomitant injuries. Our study results showed 88.5% satisfactory outcome. So, it can be concluded that, the long-term prognosis after repair of zygomaticomaxillary complex (ZMC) fractures is very good.

## **7. ETHICAL APPROVAL**

The ethical permission was sought from the Ethical Review Committee (ERC) of The Liaquat University of Medical and Health Sciences, Jamshoro.



## 8. CONSENT

Consent from patient was already taken in their medical file for procedure of surgery and to use their data for any research purpose.

## REFERENCES

1. Lynham A. Maxillofacial trauma. *AustfamilPhysici*. 2012;41(4):172-80.
2. Kim HS, Jeong EC. Orbital floor fracture. *Arch Craniofac Surg*. 2016;17(3):111-8.
3. Khereisat MH. Diplopia in Zygomatic-complex fracture. *Pak Oral Den J*. 2011;31(1):27-32.
4. Latha KS, Waheedanazir KV, Paneerselvam P, Mani KV, Alagusundaram A. A study on orbital wall fractures and its outcome. *J Evid Based Med Healthc*. 2016;3(74):4006-12.
5. Amrith S, Almousa R, Wong W, Sundar G. Blowout fractures: surgical outcome in relation to age, time of intervention, and other preoperative risk factors. *CranioMaxilloTrauReconst*. 2010;3(3):131-6.
6. Septa D, Vilas P, Newaskar, Agrawal D, Tibra S. Etiology, incidence and patterns of mid-face fractures and associated ocular injuries. *J Maxillofac Oral Surg*. 2014;13(2):115–9.
7. Muralidhar P, Chowdary NL. Ocular manifestations in road traffic accidents: a study done at a medical college hospital in south India. *Interna J Contem Med Res*. 2016;3(8):2337-3239.
8. Sung YS, Chung CM, Hong IP. The correlation between the degree of enophthalmos and the extent of fracture in medial orbital wall fracture left untreated for over six months: a retrospective analysis of 81 cases at a single institution. *Arch Plast Surg*. 2013;40(4):335-40.
9. Choi WK, Kim YJ, Nam SH, Choi YW. Ocular complications in assault-related blowout Fracture. *Arch Craniofac Surg*. 2016;17(3):128-34.
10. Carr RM, Mathog RH. Early and delayed repair of orbitozygomatic complex fractures. *J oral maxillofac surg*. 1997 Mar 1;55(3):253-8.
11. Joseph JM, Glavas IP. Orbital fractures: a review. *ClinOphthalmol* 2011;5:95-100.
12. Mathog RH. Management of orbital blow-out fractures. *OtolaryngolClin North Am* 1991;24:79-91.
13. Jin HR, Shin SO, ChooMJ. Relationship between the extent of fracture and the degree of enophthalmos in isolated blowout fractures of the medial orbital wall. *J Oral MaxillofacSurg* 2000;58:617-20.
14. Chuong R, KabanLB: Fractures of the zygomatic complex. *JOralMaxillofacSurg* 1986; 44:283
15. Al Ahmed HE, Jaber MA, Salem H, KarasM . The pattern of maxillofacial fractures in Sharjah, United Arab Emirates: a review of 230 cases. *Oral Surg Oral Med Oral Pathol Oral RadiolEndod* 2004; 98(2):166–70
16. Bataineh AB. Etiology and incidence of maxillofacial fractures in the north of Jordan. *Oral Surg Oral Med Oral Pathol Oral RadiolEndod* 1998; 86:31–5
17. Cavalcanti AL, BezerraPKM, Moraes de Oliveira DM, Granville-Garcia AF Maxillofacial injuries and dental trauma in patients aged 19–80 years, Recife, Brazil, *Rev Esp Cir Oral Maxilofac* 2010; 32:11–6

18. Cheema SA, Amin F. Incidence and causes of maxillofacial skeletal injuries at the Mayo Hospital in Lahore, Pakistan. *Br J Oral Maxillofac Surg* 2006; 44:232–4
19. Erol B, Tanrikulu R, Gořrguřn . Analysis of demographic distribution and treatment in 2,901 patients (25-year experience). *J Craniomaxillofac Surg* 2004; 32:308–13
20. Subhashraj K, Ramkumar S, Ravindran C. Pattern of mandibular fractures in Chennai, India. *Br J Oral Maxillofac Surg* 2008; 46:126–7
21. Ugboko VIC, Udoye C, Olateju SO, Amole AOD. Blindness and visual impairment from severe midface trauma in Nigerians. *Int J Oral Maxillofac Surg* 2006; 35:127–31
22. Gupta AK, Garg R, Gupta A, Bajaj K. A retrospective analysis of 189 patients of maxillofacial injuries presenting to a tertiary care hospital in Punjab, India. *J Maxillofac Oral Surg* 2009; 8:241–5
23. Iida S, Kogo M, Sugiura T, Mima T, Matsuya T. Retrospective analysis of 1,502 patients with facial fractures. *Int J Oral Maxillofac Surg* 2001; 30:286–90
24. Gassner R, Tuli T, Moreira R, Hęachl O, Ulmer H. Craniomaxillofacial trauma in children: a review of 3,385 cases with 6,060 injuries in 10 years. *J Oral Maxillofac Surg* 2004; 62:399–407.
25. Ansari MH. Blindness after facial fractures: a 19-year retrospective study. *J Oral Maxillofac Surg* 2005; 63:229–37
26. Ravindran V, Nair KSR. Metaanalysis of maxillofacial trauma in the northern districts of Kerala: one year prospective study. *J Maxillofac Oral Surg* 2011; 10:321–7
27. Sawhney CP, Ahuja RB. Faciomaxillary fractures in North India: a statistical analysis and review of management. *Br J Oral Maxillofac Surg* 1998; 26:430–4
28. Wood GD. Blindness following fracture of the zygomatic bone. *Br J Oral Maxillofac Surg* 1986; 24:12–6
29. Back CPN, McLean NR, Anderson PJ, David DJ. The conservative management of facial fractures: indications and outcomes. *J Plast Reconstr Aesthet Surg* 2007; 60:146–51
30. Ramneesh G, Gulzar G, Sanjeev U, Rajinder M, Ranabir P, Nikhil G. A retrospective audit of hundred patients of orbitozygomatic fractures with brain injury. *J Clin Diagn Res JCDR*. 2014 Jul; 8(7):NC04.
31. Mohammadinezhad C. Evaluation of a single miniplate use in treatment of zygomatic bone fracture. *J Craniofac Surg*. 2009; 20(5):1398-402.
32. Bezuhly M, Lalonde J, Alqahtani M, Sparkes G, Lalonde DH. Gillies elevation and percutaneous Kirschner wire fixation in the treatment of simple zygoma fractures: long-term quantitative outcomes. *Plast Reconstr Surg*. 2008; 121(3):948-55.
33. Cruz AA, Eichenberger GC. Epidemiology and management of orbital fractures. *Curr Opin Ophthalmol*. 2004; 15(5):416-21.