

A study of Three Cases of Removing Warts using Medorrhinum and Natrum muriaticum in Combination

ABSTRACT

Warts are the results of human papillomavirus infection on the skin. Warts usually occur on humans' hands, feet, and also in other locations of the body. We report here a study of three warts cases treated with homeopathic medicines. Two medicines (Medorrhinum and Natrum muriaticum) combinedly were administered orally for treating all three patients. Within 3-14 weeks of treatment, warts disappeared relieving all the patients from suffering. The result of this study is encouraging because the warts were removed without harming the patients and in a cost-effective way. This study would help to develop awareness among medical practitioners regarding the available homeopathic treatment options for warts.

Keywords: Warts, human papillomavirus, dermatological diseases, spontaneous healing, and homeopathic therapy.

1. INTRODUCTION

A subset of human papillomavirus (HPV) is known to cause benign cutaneous warts. Various factors may increase the risk of HPV-mediated warts including the use of common showers, sharing of towels/razors, developing eczema, and having a weakened immune system [1, 2]. Though these viruses do not produce severe complications but induce a focal expansion of epithelial cells [3]. The prevalence of HPV infection is significantly higher in developing countries with no significant difference between urban and rural people [4]. It is contagious and can affect people irrespective of age and sex with high prevalence in children and young adults. Among the different forms of warts, the 'common' warts are most often seen on the hands and present as skin-colored papules with a rough verrucous surface; 'flat' warts are most often seen on the backs of the hands characterized by light brown small plaques and 'planter' warts occur on the soles of the feet and look like very thick callouses [1, 5]. These warts may remain subclinical for many years or may grow too large fulminating masses.

In many cases, treatment of warts is needed as several complications arise. Different treatment options including topical therapies, cryotherapy, laser vaporization, surgical excision, etc. can improve the chances of getting rid of warts faster [6]; however, they do not always work. Warts on the soles and feet are very hard to treat because they are sometimes pushed inward. In addition, these local modalities are

not practical for patients with a large number of warts [7]. Also, new warts may arise again after successful treatment because the virus may still be present in a latent form in the skin cells. Homeopathy treatment might be a very good alternative for warts treatment. The effectiveness of this treatment is depended on patients' condition as a whole which includes external signs and symptoms, mental makeup, and general physical state [8]. Homeopathy medicines mostly follow a curative approach to treat warts rather than suppressing them [9]. Various homeopathic medicines like Thuja, Medorrhinum, Natrum muriaticum, Antim crude, etc. are prescribing for curing different kinds of warts [10-11]. However, it usually takes 6 months to even several years to get complete removal of warts by using any of those medicines. Even though homeopathic medicine is cost-effective, sometimes many patients become irregular in taking medicines due to this long treatment process and some patients even give up before the treatment has been completed. So, it will be effective and very beneficial if the patients get relief in a shorter period than usual. In this current study, we applied a combination of two medicines, Medorrhinum and Natrum muriaticum for the treatment of warts. Here, we represent 3 different case studies (1 female and 2 male) who were suffering from warts in different areas of the body. The patients get rid of warts completely within 3 to 14 weeks after applying the combination of two drugs.

2. PRESENTATION OF CASES

Patient 1 (P1): A female, 19 years of age came with 2 medium-sized warts on her left palm. The warts were rough, dry, and cracked (Fig. 1. Before treatment). She lived in a slum area and had been suffering for 2 years. She used Salicylic acid topically (6% Salicylic acid ointments, two times in a day, for consecutive 4 weeks), but didn't get relief from these warts.

Patient 2 (P2): A 21-year-old male was suffering from multiple warts on his right foot for more than 2 years. The warts were rough, dry and cockscomb like (Fig. 2. Before treatment). The patient did not undergo any sort of treatment.

Patient 3 (P3): A 31 years male, came with multiple warts on his face, behind the neck, and left hand. All the warts were typically presented in dry, cracked with cockscomb appearance (Fig. 3. Before treatment). He was suffering from these warts for about 10 years. Some warts from his face were removed surgically 6 years back, however, the condition becomes even worse.

All of the patients were diagnosed clinically. None of the patients were suffering from any chronic diseases including hypertension, diabetes mellitus, and any dermatological diseases. All the patients were non-alcoholic and non-smoker, although P3 was known to take betel leaf (*Piper betle*) every day (5-6 times/24 hours, along with *Areca nut*).

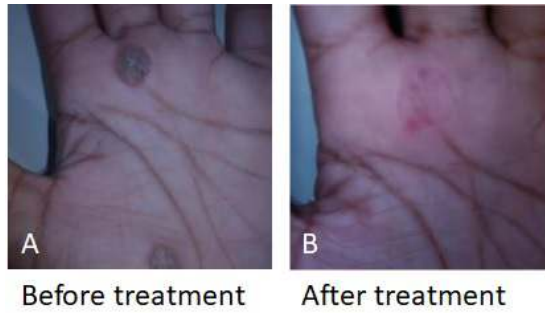


Fig. 1. Patient 1 (P1) Before treatment: Warts on the left palm (A). After treatment: Cured after 3 weeks (B).

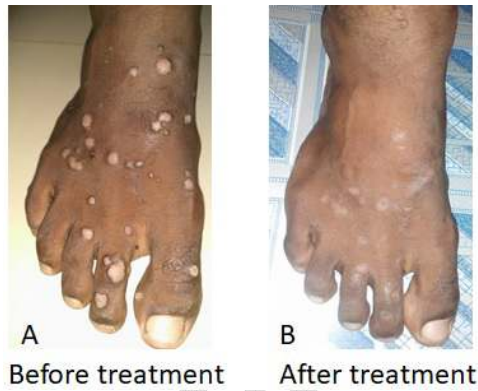

Fig. 2. Patient 2 (P2) Before treatment: Multiple warts on the right foot (A). After treatment: Cured after 8 weeks (B).

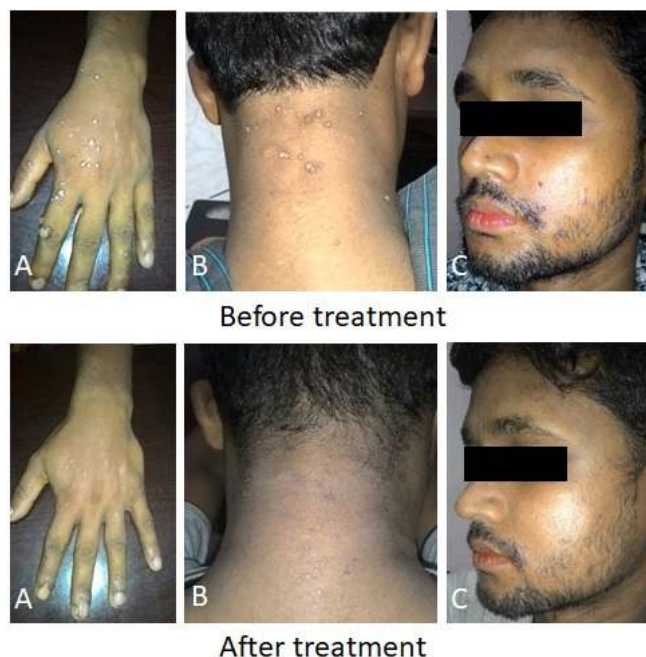

Fig. 3. Patient 3 (P3) Before treatment: Warts on the left hand (A), the neck (B), and the face (C). After treatment: Disappearance of warts from the left hand (A), the neck (B), and the face(C), within 14 weeks

The appearance of warts was rough, dry, cracked, and like cockscomb, observed in all the above patients.

MEDICINES AND DOSE

With the aseptic method, all the patients were examined and periodic images of the lesion area were captured from the beginning to the end of the treatment period. Physical appearances of the warts were compared with previously captured images on each re-visit.

After clinical diagnosis, the patients were advised to take Medorrhinum (Neisseria gonorrhoea pus extract) orally in 30C dilution (0.5 ml dissolved with 60 ml distilled water) and distributed in 15 equal doses (4 ml/24 hours, 2 ml in the morning and 2 ml at night, before meal) and Natrum muriaticum (NaCl) orally in 30C dilution (0.5 ml dissolved with 60 ml distilled water) and distributed in 15 equal doses (4 ml/24 hours, once at night, after meal). Both of the medicines were suggested to be continued in the same doses for all the patients. During 3 to 14 weeks of the continuous treatment period, topical applications of any homeopathic or other drugs were not advised.

All the patients were advised to maintain personal hygiene. The patients were also advised strictly not to scratch the lesion areas and not to apply for any topical medicine. Patient 3 (P3) was specifically instructed not to take betel leaves in any form.

RESULTS

Two warts on the left palm (Fig. 1. Before treatment) of P1 disappeared (Fig. 1. After treatment) within 3 weeks. In the case of P2, 8 weeks were needed to cure multiple warts on the foot (Fig. 2. After treatment). It took 14 weeks to cure multiple warts on the left hand and neck of P3 (Fig. 3. After treatment).

3. DISCUSSION

Sometimes warts may resolve spontaneously which may take a long time, but the patients want to get faster relieved. Among the various treatment options, low-cost homeopathic treatment might be very effective for warts treatment. In homeopathy, the selection of medicines is made in accordance with the symptoms, however several medicines, including Thuja, Medorinham, or Natram Muriticum, are typically advised in these cases. Medorrhinum had been used in various clinical conditions along with dermatological complaints like wart and corn; dry, nasty-looking, soft, and spongy excrescences in the form of cockscomb or cauliflower are common treated with this medicine [9-13]. Nat Mur has a dry and cracked appearance on the skin with soft and spongy like warts, mostly found in the palm and hand region [14-15]. The use of single drugs is well appreciated in homeopathy [16], though now-a-days, in some cases, the application of two or more drugs at a time is practiced to reduce the duration of the curing period of a particular disease [17]. In our study, we used Medorrhinum and Natrum muriaticum for warts treatment. We observed that the combination of these two drugs removed warts in all three cases within 3-14 weeks. The period required to cure warts varied from case to case. This might be due to the patient's individual immune status, area, and severity of warts formation.

The homeopathic principle is mostly based on the theory that a lower degree of dilution of a drug shows more potent activity and therefore, a very small quantity of a drug usually would suffice for remedial action [16]. Although recommended dilution is not always fixed, however, 30C is used in many cases and could be given frequently without any adverse reaction [18]. In our case study, we used the 30C dilution of two drugs (Medorrhinum and Natrum muriaticum) throughout the treatment. Sometimes it takes a few months to even years for complete removal of warts by using homeopathic medicines [19]. We observed in this study that combined action of Medorrhinum and Natrum muriaticum diminished warts in a few weeks. The findings of this case study may help to practice a new treatment option to reduce the curing time of warts.

4. CONCLUSION

Although the bioactive components present in Medorrhinum and natrum muriaticum act in an effective way to achieve early recovery, however, the exact mechanism of action of these medicines is still not known. The medicines might boost up the immunity of the patients or caused some changes in molecular pathways and receptors that might relay the signals for early recovery. Further study is needed to

understand the detailed mechanism and possible correlation of using combinatorial homeopathic drugs for warts treatment.

STATEMENT OF ETHICS

All authors declare that written consent was obtained from the patients to publish the case information and related images.

REFERENCE

1. Loo SK, Tang WY. Warts (non-genital). *BMJ clinical evidence*. 2009;2009.
2. InformedHealth.org [Internet]. Institute for Quality and Efficiency in Health Care (IQWiG); 2006-. Warts: Overview. 2014 Jul 30 [Updated 2019 Nov 7]. [cited 2020 Jan 26]. Available from: <https://www.ncbi.nlm.nih.gov/books/NBK279586>
3. Alam M. Fitzpatrick's dermatology in general medicine. *Arch. Dermatol*. 2004 Mar 1;140(3):372-.
4. Nahar Q, Sultana F, Alam A, Islam JY, Rahman M, Khatun F *et al*. A. Genital human papillomavirus infection among women in Bangladesh: findings from a population-based survey. *PloS one*. 2014 Oct 1;9(10):e107675.
5. Semprimoznik K, Sult R, Gorsic M. Treatment of warts with 1064 nm Nd: YAG. *J. LA&HA*. 2012 May;2012(1):90-3.
6. Gerlero P, Hernández-Martín Á. Treatment of Warts in Children: An Update. *Actas Dermo-Sifiliográficas (English Edition)*. 2016 Sep 30;107(7):551-8.
7. Aldahan AS, Mlacker S, Shah VV, Kamath P, Alsaidan M, Samarkandy S *et al*. Efficacy of intralesional immunotherapy for the treatment of warts: A review of the literature. *Dermatologic therapy*. 2016 May 1;29(3):197-207.
8. Sterling JC, Gibbs S, Haque Hussain SS, Mohd Mustapa MF, Handfield-Jones SE. British Association of Dermatologists' guidelines for the management of cutaneous warts 2014. *Brit J Dermatol*. 2014 Oct 1;171(4):696-712.
9. Vermeulen F. *Concordant MateriaMedica*. Dev Nagar, New Delhi: Indian Books & Periodicals Publishers; 2001
10. Mercaldo M. How to prescribe Medorrhinum: the frequency of symptoms and signs in homeopathic patients. *British Homoeopathic Journal*. 1999 Apr 1;88(2):69-77.
11. *The Homeopathic Physician, A monthly journal of Homeopathic materia medica and clinical medicine*, Vol. IX. JUNE, 1889. No. 6.
12. Abdel-Hadi OB, Kennedy CO, Jenkins MD. Case reports of the use of Medorrhinum in three patients suffering from exfoliative dermatitis and one patient with porphyria. *British Homoeopathic Journal*. 1980 Apr 1;69(2):105-7.
13. Mercaldo M. Medorrhinum: Review of clinical uses and listing in Kent's Repertory. *British Homoeopathic Journal*. 1996 Jul 1;85(3):149-60.
14. Chifflet S, Hernandez JA. The Epithelial Sodium Channel and the Processes of Wound Healing. *BioMed Res. Int*. 2016 Jul 14;2016.
15. Sukul S, Mondal S, Sukul NC. *Sepia 200cH at 1: 1000 dilution ameliorates salt stress in cowpea seedlings but its medium 90% ethanol proves ineffective at the same dilution*. *Int J High Dilution Res*. 2012 Dec 12;11(41):237-46.
16. Hahnemann HC, Boericke W. *Organon of Medicine*. 6th ed. New Delhi: B. Jain Publishers; 2012.
17. Thinesse-Mallwitz M, Maydannik V, Keller T, Klement P. A homeopathic combination preparation in the treatment of feverish upper respiratory tract infections: an international randomized controlled trial. *Complementary Medicine Research*. 2015;22(3):163-70.

18. Rawat PS, Select Your Dose and Potency, 11th impression, New Delhi: B. Jain Publishers; 2011.
19. Oza PM. Homeopathic management of warts. Indian Journal of Drugs in Dermatology. 2016 Jan 1;2(1):45.

UNDER PEER REVIEW