

Patterns of Scrotal Sonographic Findings in Suspected Subfertile Males in Enugu, Nigeria

ABSTRACT

Introduction: There are varied scrotal findings in subfertile males of which ultrasonography is a readily available, non-ionizing and reproducible imaging modality of choice for proper assessment.

Aim: To identify the patterns of scrotal ultrasonographic findings in suspected subfertile males in Enugu.

Study Design: A comparative cross sectional prospective study.

Place and Duration of Study: Department of Radiation Medicine University of Nigeria Teaching Hospital (UNTH) Enugu, between July 2019 and February 2020.

Methodology: 130 adult males comprising 65 suspected subfertile male and 65 normal adult males were recruited for this study. Ultrasound scanning was done on research participants using 5.0-7.5 MHz linear transducer on a mobile "ALOKA" ultrasound machine. The obtained data were coded, validated, and analyzed using Statistical Package for the Social Sciences SPSS software, version 24, percentage, analysis of variance (ANOVA) and t test. A *P*-value of less than 0.05 was considered statistically significant.

Results: A total of 130 subjects were scanned. The mean age was 41.2years. The mean testicular volume was $10.01 \pm 4.09 \text{cm}^3$. There was a wide variety of findings in the assessed subfertile males ranging from normal to inhomogeneous testicular echotexture and varicocoele. Varicocoele was the commonest finding accounting for 50% of other findings, followed by hydrocoele (22%), then 10% had inhomogeneous echotexture while microlithiasis, undescended testis as well as epididymal cyst all had 6%.

Conclusion: Ultrasonographic evaluation of testis is invaluable in the assessment of patterns of findings in male subfertility. Varicocoele was the commonest sonologic finding among the suspected subfertile males. This is reassuring as varicocoele is readily treatable cause of subfertility compared to complex multifactorial causes of female subfertility.

Keywords: Subfertility; ultrasound; testis; scrotal.

1. INTRODUCTION

The incidence of subfertility has been on the rise in Nigeria with male causes alone accounting for about 42% in the south east zone of the country. This has great socio-cultural as well as economic impact in terms of work force in a state like Enugu where procreation is taken as one of the most important priorities of marriage.

There are varied scrotal findings in subfertile males of which ultrasonography is a readily available, non-ionizing and reproducible imaging modality of choice for proper assessment.

The testes vary in size with age, body mass index, race, geographic distribution, prevalent ambient temperature and marriage type-monogamy and polygamy [1]. The testis is an organ that belongs to two systems in the body in terms of function: endocrine and reproductive systems. As an endocrine organ it produces testosterone which is responsible for the development of male sexual characteristics. It produces spermatozoa which are the male gametes [2].

The male reproductive system develops embryologically under the influence of the "Y" chromosome, testosterone, and female inhibitory substances. The most important diseases of

testes/scrotum are: orchitis, testicular cancer, testicular torsion, varicocele, etc. [3].

As the seminiferous tubules comprise approximately 90% of the testicular mass, testicular volume is largely a reflection of spermatogenesis [4, 5].

Ultrasonography (US) is a readily available noninvasive and cost-effective imaging modality that can fairly accurately evaluate organs like the testis. Its use of sound waves (non-ionizing) makes it invaluable in the repeated evaluation of scrotal findings without fear of adverse effects of radiation on patients. Operator dependence of US can be overcome by having a single sonologist take the measurements [6].

Although the most accurate method for measuring testicular volume is still debated, US is generally recognized as the most reliable means of measuring *in situ* testicular volume [7,8,9]. Paltiel *et al* [10] compared the accuracy and precision of the three most commonly quoted formulas in the literature, and concluded that the most accurate formula for US estimates was length (L) x width (W) x height (H) x 0.71.

2. METHODOLOGY

This was a comparative cross-sectional prospective study. The study was conducted in Enugu metropolis of Enugu state in Southeast Nigeria and data collection was from July 2019 to February 2020. Subjects between the ages of 30 and 65 years were randomly selected from different parts of the city and scanned.

Subfertile males were assessed through the Urology and Gynecology clinics of the University of Nigeria Teaching Hospital, Enugu.

A sample size of 65 subfertile males was chosen to have a more representative number of the population.

Also 65 age, height and weight matched healthy adult males without history of subfertility, made up of patients' relations, staff and other patients were evaluated.

The total sample size for the study was 130.

2.1 Data Collection

The procedure was clearly explained to subjects and informed consent obtained. The subject's age, occupation, marital status, weight, height and other health data were then documented in the Study Data Sheet. The scan was carried

out by the author to eliminate interobserver bias.

Ultrasound scan was done using a grey scale real time mobile 'ALOKA' machine with a high frequency 5-7.5 MHz linear probe.

2.2 Testicular Scanning

The privacy of the subject was first ensured because of the sensitivity of the research. The subjects were made to lie comfortably on a couch in supine position with the legs slightly abducted. The scrotum was supported by a soft support to aid cooperation by subject.

Coupling gel was applied on the scrotum. Each testis was scanned in orthogonal views i.e. longitudinal and transverse planes. Gentle pressure was applied to the testis so as not to compress it or inflict pain on the subject. For consistency, the right testis was scanned followed by the left. The general anatomy of the testis was evaluated. The echotexture, echogenicity, margins of the testes. The scrotal wall, tunica vaginalis, epididymis was examined for masses and abnormalities. Doppler flow was used to evaluate the testes and pampiniform plexus of veins.

The following dimensions were measured for each testis was: The volume was then calculated using the most accurate [13] formula of Lambert: $L \times W \times H \times 0.71$. The weight was measured with standard weighing scale while height with standard meter rules. The testicular volumes obtained were then compared with age, weight, height and body mass index (BMI) of research participants.

Images were obtained as shown in Figs. 1-3.

Inclusion criteria for healthy adults: Male subjects between 30 and 65 years. Subjects, who did not have any scrotal or testicular symptoms like swelling, pain etc.

Inclusion criteria for adults with subfertility: Subjects who have not been able to achieve pregnancy in their spouses in spite of regular unprotected intercourse for at least 1year. Subjects whose spouses have been medically proven not to be the cause of the subfertility.

Exclusion criteria healthy adults: Subjects that were below 30years or above 65years of age. Subjects with prior history of testicular or scrotal lesion(s). Subjects who had undergone orchiectomy with or without prosthetic testis. Established cases of male subfertility. Congenital

anomalies like ambiguous genitalia, hermaphroditism, and undescended testis. Nigerians who have not been resident in the country in the last 10 years and non-Nigerians.

Exclusion criteria for adults with subfertility: Established cases of fertile men (Normal male function test).

2.3 Statistical Analysis

Statistical Package for the Social Sciences (SPSS) version 24 for windows software was used for analysis of the data. Analysis of variance (ANOVA) and t test was used to find any statistically significant difference between the subjects. A p -value of <0.05 was considered as statistically significant. Pearson correlation (r), Receiver operating characteristics (ROC) analysis and curve was used to generate the specificity and sensitivity of each variable.

2.4 Ethical Consideration

Approval for the research was obtained from the Health Research Ethics Committee of the University of Nigeria Teaching Hospital Ituku-Ozalla, Enugu State, Nigeria.

To ensure confidentiality, the subjects' names and places of residence were excluded from the data sheet. Participation of subjects was on voluntary basis after explaining the benefits of the study and safety of the procedure to the subjects in order to obtain informed consent. Participants were also adequately counseled pre and post procedure.

Study was done at no cost to participant as a privately arranged mobile "ALOKA" ultrasound unit was used for imaging. The overall benefit to the participant was the opportunity to have a scrotal scan done at no cost and also any abnormality detected was reported and immediately referred for appropriate management.

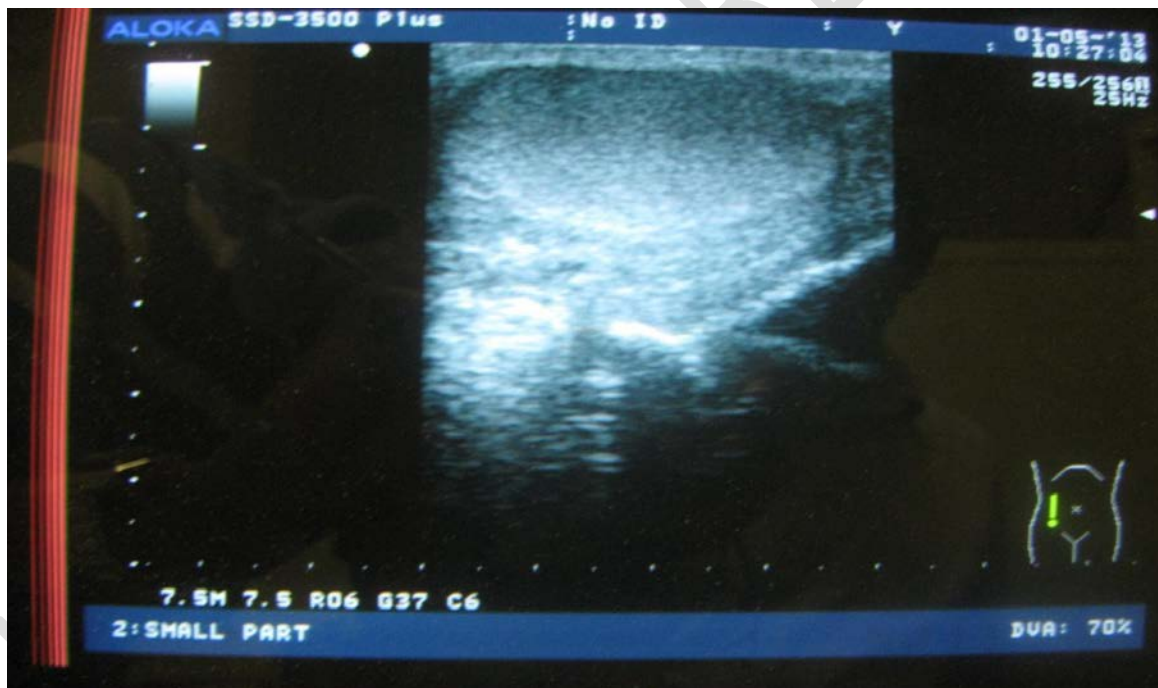

Fig. 1. A longitudinal ultrasound scan of the left testis showing the length (line between "+") and width (line between "x")

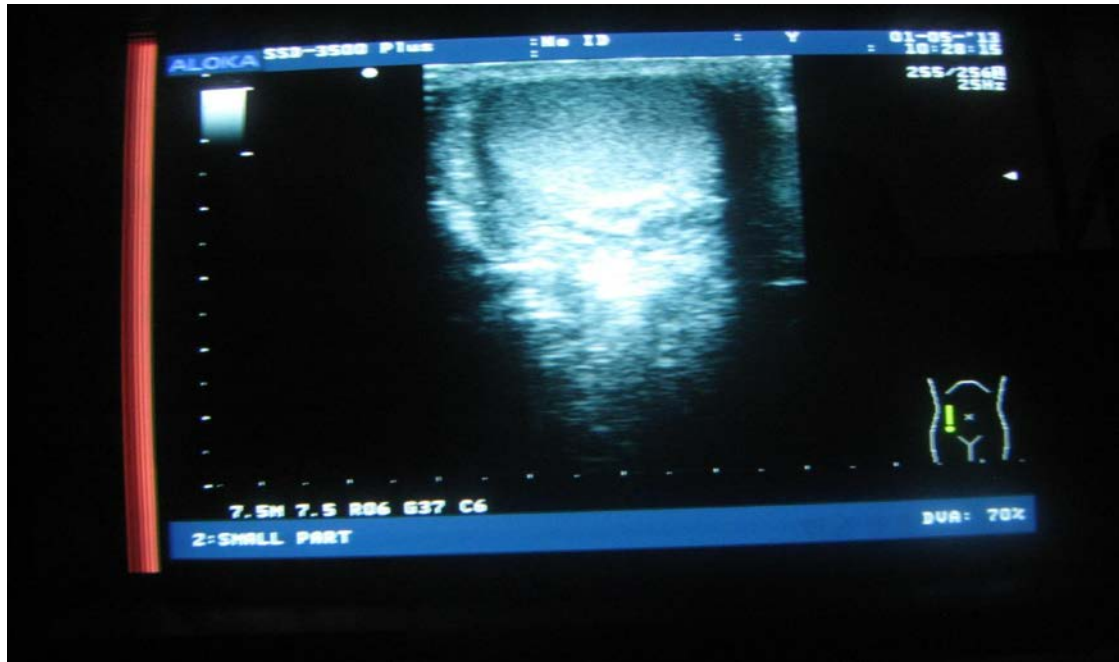

Fig. 2. A transverse ultrasound scan of the left testis showing the height (line between “+”)

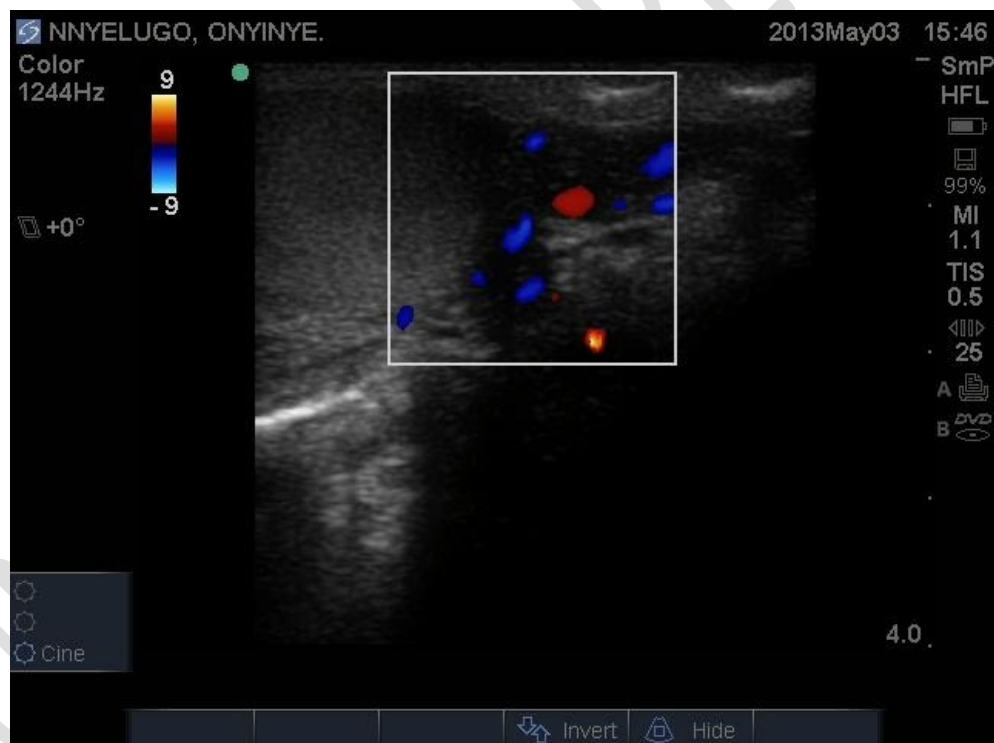


Fig. 3. Doppler ultrasound of the testis

3. RESULTS

A total of 65 normal adult males, and 65 adult males with subfertility, were evaluated for their testicular volume by ultrasonography. The mean ages of normal and subfertile subjects were 42.1 ± 16.3 years and 41.2 ± 8.5 years respectively as shown in Table 1. Their mean weights were

68.40 ± 12.47 kg and 71.26 ± 11.38 kg respectively. The mean heights of normal and subfertile subjects were 1.69 ± 0.09 m and 1.73 ± 0.40 m respectively.

The testicular dimensions with respect to age, weight, height, BMI for normal and subfertile subjects are shown in table.

Table 2 indicates the mean testicular dimensions of both testes in the normal and subfertile subjects. Although the testicular dimensions of the right were higher than that of the left, there was no significant difference except for the length ($p=0.001$) in normal subjects.

The average testicular volume of both testes (shown in Fig. 4) was $15.53 \pm 5.37 \text{ cm}^3$ and $10.01 \pm 4.09 \text{ cm}^3$ for normal and subfertile subjects respectively. There was significant difference in

all the testicular dimensions between normal and subfertile ($p=0.01$).

There was a wide variety of findings in the assessed subfertile males ranging from normal to inhomogeneous testicular echotexture and varicocele. Varicocele was the commonest finding accounting for 50% of findings, followed by hydrocoele (22%), then 10% had inhomogeneous echotexture while microlithiasis, undescended testis as well as epididymal cyst all had 6%. This is illustrated in Fig. 5.

Table 1. Age distribution of research participants

Age(yrs)	Normal.		Subfertile	
	Frequency	%	Frequency	%
30 – 39	32	49.3	31	47.0
40 -49	21	31.5	25	39.2
50 – 59	9	13.8	6	10.0
60 +	3	5.4	3	3.8
Total	65	100	65	100
Mean age(yrs.)	42.2±16.3		41.2±8.5	

Table 2. The mean testicular dimensions of both testes in normal and subfertile subjects

Normal	Right Mean±SD	Left Mean±SD	p value
Length(cm)	4.04±0.56	3.82±0.41	0.001
Width(cm)	2.49±0.63	2.50±0.47	0.574
Height(cm)	2.29±0.44	2.25±0.48	0.903
Testicular Volume (cm ³)	15.65±6.01	15.40±5.02	0.078
Subfertile			
Length(cm)	3.32±0.56	3.29±0.55	0.691
Width(cm)	2.17±0.47	2.24±0.49	0.986
Height(cm)	1.85±0.46	1.85±0.46	0.301
Testicular Volume(cm ³)	9.92±4.34	10.10±4.59	0.689

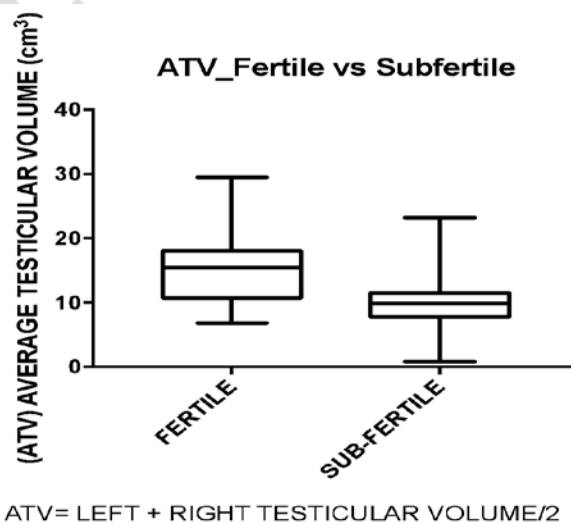


Fig. 4. Box plot showing the distribution of average testicular volumes (ATV) amongst the fertile (controls) and sub-fertile groups.

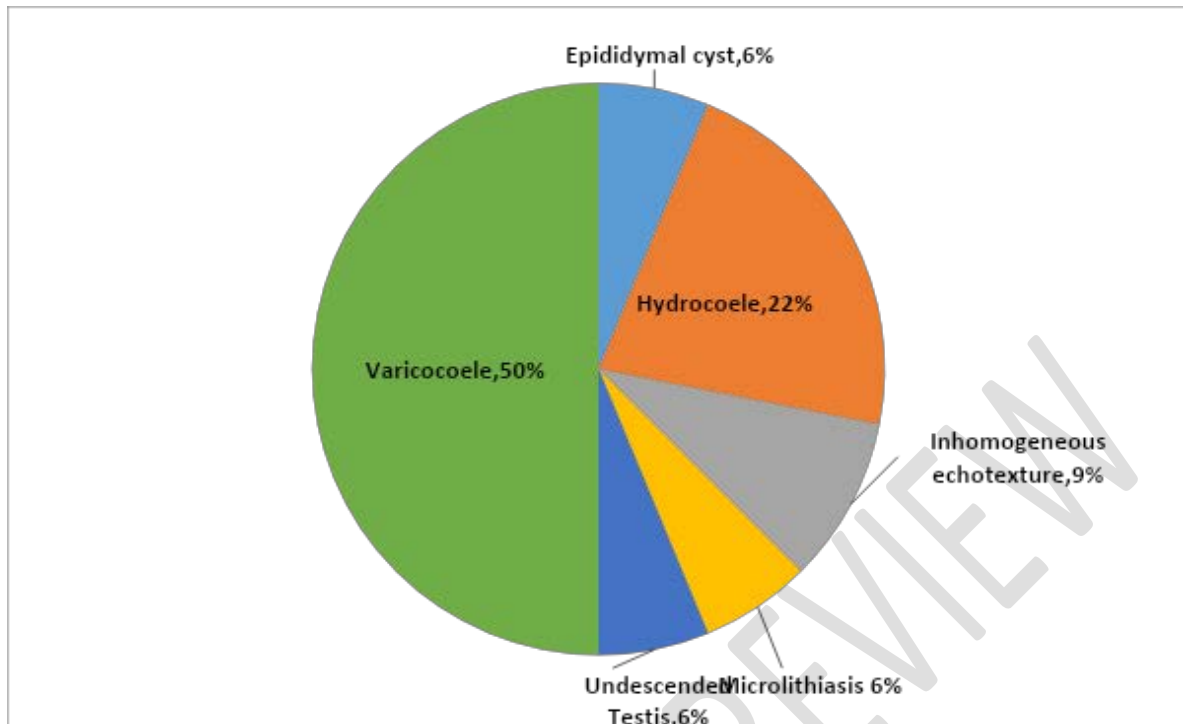


Fig. 5. Pie chart indicating the findings in subfertile subjects

4. DISCUSSION

Ultrasonography is a readily available, non-invasive, non-ionizing radiation and cost-effective imaging modality that can fairly accurately evaluate organs like the testis. Colour Doppler is useful in accurate evaluation of the anatomy of the testes and scrotal pathologies [11].

Paltiel *et al* showed that length (L) x width (W) x thickness (T) x 0.71 was the most accurate formula for ultrasonologic evaluation of testicular volume.

In the study, the mean age for subfertile and fertile was 41.18 years and 42.1 years respectively. This is higher than the age found in the work done in Abuja by Kolade *et al* [12] with the mean age of sub-fertile and fertile subjects studied as 29 years and 34 years, respectively. Also in contrast with the study done in Sudan by Marwa, *et al* [13], having infertility more common in age group 36-46 years (41.33%) but the mean age of infertility was 36.43±8.50 years.

The average of both testes was 15.53±5.37 cm³ and 10.01±4.09cm³ for normal and subfertile subjects respectively. The testicular dimensions of the subfertile subjects were significantly lower than that of the normal subjects (p=0.01). This is corroborated by studies by Sigma and Jarow[14], Lenz *et al*[15], Zini *et al*[16], Zucchi *et al*[17]done

in different parts of the world. The reason for this difference agrees with the fact that testicular volume is composed predominantly of seminiferous tubules which are responsible for sperm production which is invariable proportional to fertility [4, 5].

The mean testicular volume of this study 10.01±4.09cm³ was however larger than the size of 7.55cm³ obtained by Pethiyagoda [18] in Sri Lanka using 86 subfertile men. Enighe [19] in Nigeria found that the mean testicular volume (MTV) for infertile male was 13.14 ± 5.16 cm³. There variations may be due to difference in geographic locations and ethnicity [20]

The appearance of varicoceles on ultrasound is serpiginous anechoic tubular structures with diameters larger than 2 mm [21]. On Valsalva manoeuvre, they often enlarge and with blood flow reversal [21.22] Varicocele was most predominant finding among subfertile participants in this study. This is similar to the study by Tijani *et al*. [23] in Nigeria and the one done by Qublan *et al* [22] in India. Majority of researches observed varicoceles to be more common on the left in subfertile men, a finding attributed to the drainage pattern of the more tortuous left internal spermatic vein into the left renal vein.[23] Findings from this study were consistent with these reports. Varicocele has been generally reported by many authors to have an overall prevalence of 29–40% in all infertile men. [23,

24, 25, 26] These finding corroborates our study in which prevalence was 50%.

The second commonest finding in this study was hydrocele which appears as fluid in the tunica vaginalis. It may be due to inflammatory process i.e. reactive of idiopathic. Awad in Saudi Arabia [24] Mohammad *et al* [27] in Zaria and Tijani *et al.* in Lagos [23] all had similar observations. This finding is important because Mihmanli and Kantarci [28] showed that idiopathic hydrocele may lead to testicular enlargement and increased vascular resistance in the intratesticular arteries, which invariably adversely affect function of the testis.

Inhomogeneous testicular echogenicity as seen in this study may reflect chronic testicular insults from trauma, infections/ inflammation and in extreme cases may reflect infarction. These findings show chronicity which may contribute to reduction in testicular function. [29]

Other relatively less common abnormalities such as, undescended testis, epididymal cysts and microlithiasis seen in this study have been reported to be associated with subfertility. Epididymal cysts are thought to lead to obstruction while microlithiasis is causes impair testicular function by immunological mechanism. [30]. Prabudh *et al* [31] recognized that androgen dependent transformation defects of gonocytes into adult dark spermatogonia in cryptorchidism is recognized as the primary cause of sub-fertility in patients. Therefore, even though these less common abnormalities were seen in our study , they may have probably contributed alongside other co morbidities to reduce fertility

5. CONCLUSION

Ultrasonographic evaluation of testis is invaluable in the assessment of patterns of findings in male subfertility. Varicocele was the commonest sonologic finding among the suspected subfertile males. This is reassuring as varicocele is readily treatable cause of subfertility compared to complex multifactorial causes of female subfertility.

6. RECOMMENDATION

Ultrasonographic testicular volume assessment should be included in the routine investigation for subfertility in males. This is because the result is reproducible and the procedure is non-invasive and has a good yield of diagnostic information with the use of Doppler.

DISCLAIMER

The products used for this research are commonly and predominantly use products in our area of research and country. There is absolutely no conflict of interest between the authors and producers of the products because we do not intend to use these products as an avenue for any litigation but for the advancement of knowledge. Also, the research was not funded by the producing company rather it was funded by personal efforts of the authors.

REFERENCES

1. Jerome H B, Leda C, John T, The Adapted mind-Evolutionary Psychology and the Generation of Culture, 1st ed., New York;1992:299.
2. Guyton A, Hall J E, Guyton and Hall Textbook of Medical Physiology, 11th ed., Philadelphia; 2006, 996- 1009.
3. Cotran RS, Kumar V, Robbins SL. The Male Reproductive System. In: Robbins Pathological Basis of Disease, 4th ed., Edinburgh: W.B Saunders; 1989:101-134.
4. MacManus I. Scrotal asymmetry in man and in ancient sculpture. Nature.1976;259:426.
5. Anderson JE. Grant's Atlas of Anatomy, 8th ed., Baltimore MD: Williams & Wilkins; 1983:860.
6. Lenz S, Thomsen Jk, Giwerzman A, Hertel NT, Hertel NT, Hertz J, Skakkebaek NE..Ultrasonic texture and volume of testicles in infertile men. Hum Reprod. 1994;9(5):878-881
7. Ikechebelun JI, Adinma JI, Ori E, Ikegwonu SO. High prevalence of male infertility in southeastern Nigeria. Jobstet Gynaecol 2003 Nov; 23 (6):657-659.
8. Rivkees SA, Hall DA, Boepple PA, Crawford JD. Accuracy and reproducibility of clinical measures of testicular volume. J Pediatr. 1987; 110: 914–917.
9. Behre HM, Nishan D, Nieschlag E. Objective measurement of testicular volume by ultrasonography: evaluation of the technique and comparison with orchidometer estimates. Int J Androl. 1989; 12: 395–403.
10. Paltiel HJ, Diamond DA, Di Canzio J, Zurakowski D, Borer JG, Atala A. Testicular volume: comparison of orchidometer and US measurements in dogs. Radiology 2002; 222:114–119.
11. Yasser AM, Said AA. Acute torsion of the testis in children and young adults: Role of high resolution and color Doppler

- ultrasonography. *Egypt J Radiol Nucl Med* 2015;46:151-7
12. Kolade-Yunusa Oluseyi and Thairu Yunusa (2019): Sonography of scrotal abnormality among subfertile and fertile males in Abuja, Nigeria. *Sub-Saharan African Journal of Medicine*(Vol. 6, Issue 2)
 13. Marwa, et al.; (2019): Assessment of Scrotum in Infertile Male with Abnormality Detected in Ultrasound in Correlate to Semen Analysis and Hormonal Count. *Scholars Journal of Applied Medical Science*; ISSN 2347-954X.
 14. Sigman M, Jarow JP, Wein AJ, Kavoussi LR, Novick AC, Partin AW, Peters CA, editors. *Male infertility Campbell-Walsh Urology*. Philadelphia, PA: WB Saunders; 2007, :613 –614.
 15. Lenz S, Thomsen JK, Giwercman A, Hertel NT, Hertz J, Skakkebaek NE. Ultrasonic texture and volume of testicles in infertile men. *Hum Reprod*. 1994;9(5):878-881
 16. Zini A, Buckspan M, Berardinucci D, Jarvi K. Loss of left testicular volume in men with clinical left varicocele: correlation with grade of varicocele. *Arch Androl*. 1998;41:37–41
 17. Zucchi A, Mearini L, Mearini E, Fioretti F, Bini V, Porena M. Varicocele and fertility: relationship between testicular volume and seminal parameters before and after treatment. *J Androl*. 2006;27:548–551.
 18. Pethiyagoda, A.U and Pethiyagoda, K.T (2017): Scrotal ultrasonography in the assessment of subfertile males, *International Journal of Scientific and Research Publications, Volume 7, Issue 5, May 2017* 873 ISSN 2250-3153
 19. Enighe W Ugboma. Relationship between Testicular Volume and Sperm Count in Infertile Men in Southern Nigeria. *Asian Journal of Medicine and Health* 4(1): 1-6, 2017; Article no.AJMAH.29182
 20. Diamond JM. Ethnic-differences - variation in human testis size. *Nature* 1986;320:488-489.
 21. Kwak N, Siegel D. Imaging and interventional therapy for varicoceles. *Curr Urol Rep* 2014;15:399.
 22. Qublan HS, Al-Okoor K, Al-Ghoweri AS, Abu-Qamar A. Sonographic spectrum of scrotal abnormalities in infertile men. *J Clin Ultrasound* 2007;35:437-41
 23. Tijani KH, Oyende BO, Awosanya GO, Ojewola RW, Lawal AO, Yusuf AO. Scrotal abnormalities and infertility in West African men: A comparison of fertile and sub-fertile men using scrotal ultrasonography. *Afr J Urol* 2014;20:180-3.
 24. Awad ME. Ultrasonography diagnosis of scrotal pathologies. *J Pharm* 2015;5:1-4.
 25. Agarwal A, Deepinder F, Cocuzza M, Agarwal R, Short RA, Sabanegh E, et al. Efficacy of varicocelectomy in improving semen parameters: New meta-analytical approach. *Urology* 2007;70:532-8.
 26. Chen SS. Differences in the clinical characteristics between young and elderly men with varicocele. *Int J Androl* 2012;35:695-9.
 27. Muhammad Zaria Ibrahim, Abdulkadir Musa Tabari, Joseph Bako Igashi, Suleiman Lawal, Mohammed Ahmed. Scrotal doppler ultrasound evaluation in Zaria, Nigeria. *Nig journal of basic and clinical sciences* 2016;13(2) 89-93
 28. Mihmanli I, Kantarci F. Sonography of scrotal abnormalities in adults: An update. *Diagn Interv Radiol* 2009;15:64-73
 29. Prateek Sihag, Anupama Tandon, Raj Pal, Jain BK, Shuchi Bhatt, Simranjeet Kaur, Arpita Sinha. Sonography in male infertility: a look beyond the obvious, *Journal of Ultrasound*. 2018 Sep; 21(3): 265–276
 30. Holden A, List A. Extratesticular lesions: A radiological and pathological correlation. *Australas Radiol* 1994;38:99-105
 31. Prabudh Goel, Rawat J.D., Wakhlu A., Kureel S.N. Undescended testicle: An update on fertility in cryptorchid men, *Indian journal of Medical Research* 2015 Feb; 141(2): 163–171