

Extramural Jejunal GIST: A rare case report

ABSTRACT

Gastrointestinal stromal tumors (GISTs) of jejunum is a rare tumor arising from the interstitial cells of Cajal (ICC) present in the myenteric plexus of the muscularis propria in the intestinal wall. They usually present as small asymptomatic mass and a large exophytic mass causing pain is a relatively rare presentation of jejunal GIST. The tumor mass mainly consists of spindle cells arranged in layers or sheets and stain positive for CD117, CD34, and Vimentin on immunohistochemistry. CECT scan is the most common imaging modality used for staging of the tumor. Surgical resection with negative margins is the primary treatment for localized GIST, followed by adjuvant Imatinib in high risk cases. We present the case of a 65 year old male presenting with large extramural jejunal GIST.

KEY WORDS: GIST, Jejunum, abdominal lump, CD117, Imatinib.

INTRODUCTION

Gastrointestinal stromal tumors (GISTs) are rare mesenchymal tumors of the gastrointestinal tract. They comprise only 0.2% of all gastrointestinal tumors and are mainly found in the stomach. Small intestinal GISTs comprise only 20% of cases, with jejunal GISTs being the rarest subtype, accounting for 0.1-3% of all GI tumors¹. They are known to arise from the gastrointestinal pacemaker cells, the interstitial cells of Cajal (ICC) present in the myenteric plexus of the muscularis propria². GISTs usually occur in a sporadic form, but may present as a feature of multiple neoplastic syndromes³. They present as a spectrum of morphological and clinical features ranging from benign to malignant; with 10–30% of cases progressing to malignancy⁴. The diagnosis is established with the help of immuno histo chemistry (IHC) markers CD117, CD34, vimentin and mutational analysis for c-kit and platelet-derived growth factor receptor alpha (PDGFR α) genes⁵. The primary treatment for localized GISTs is complete surgical resection with microscopic negative margins⁶. Adjuvant treatment with Imatinib mesylate is recommended for patients with high risk features to decrease the rate of recurrence⁷. The risk stratification is done as per the National Institutes of Health (NIH) consensus criteria and UICC/AJCC TNM staging system⁸⁻⁹. Patients with unresectable, metastatic, or recurrent GISTs are also treated with imatinib mesylate¹⁰. We present a rare case of jejunal GIST with an unusual large size of presentation and with history of pain abdomen.

CASE REPORT

A 65 year old male presented with pain and fullness of abdomen for the last 1 month along with decreased appetite and mild breathlessness on walking for the last 10 days. The clinical examination showed an approximately 16 x 10 cm well defined firm lump in lower abdomen and pelvis with mild tenderness. All the routine biochemical investigations were normal. An Ultrasonography of abdomen showed 15.7 x 7.9 cm size well-defined solid mass occupying major part of lower abdomen causing displacement of the bowel loops. A subsequent CECT scan was done which showed large 17.4 x 17.1 x 9.5 cm heterogeneously enhancing hypodense soft tissue lesion involving pelvis and rt. Lower abdomen with an ill-defined fat plane with a short segment of distal ileum/ proximal jejunum. [Fig.1] An USG guided FNAC was done which was suggestive of benign mesenchymal tumor. So, a laparotomy was planned and done through rt. paramedian incision. There was a huge tumor arising from the mesenteric border of jejunum which was abutting sigmoid colon. Gross tumor along with the segment of jejunum from which it was arising was resected and end to end anastomosis was done. The abdomen was closed in layers and the mass sent for histopathological examination. [Fig.2] The post-operative period was uneventful. Gross pathological examination showed a large 14 x 13 x 9 cm nodular mass with separate multiple large areas of hemorrhage and necrosis, partly encapsulated by fibrous tissue. The jejunal segment showed a patch of grey-white thickening in the mucosa of size 0.8 x 0.8 cm. Microscopic examination showed a highly cellular spindle cell tumor with cells arranged in fascicles forming organized pattern and with abundant eosinophilic cytoplasm. Focal areas also showed spindle cells in sheets with sprinkled mononuclear cells and mitotic rate >5/HPF with 20-30% necrosis. The jejunal section showed stromal tumor arising from muscularis propria and reaching serosa. This was suggestive of Gastrointestinal stromal tumor (GIST) and the resection margins were uninvolved. The immunohistochemistry test was positive for CD117, DOG1, CD34 and negative for S-100., which confirmed the diagnosis of GIST.

DISCUSSION

The incidence for jejunal GIST is extremely rare, accounting for only 0.1-3% of all GI tumors¹. More than 80% of GISTs are primarily located in GI tract but may occur outside, known as extra-intestinal GIST in sites like omentum, mesentery, retroperitoneum, gallbladder and urinary bladder^{8,11}. The most common site in the GI tract is the stomach with 70% of the cases of GIST, followed by small-intestine with 20-30% cases and remaining 10% occurs in esophagus, colon and rectum¹². Over 90% of GISTs occur in adults over 40 years old with a slight male predominance but no association with geographic location or ethnicity¹³. GISTs usually arise from the intermuscular myenteric plexus region of the intestinal wall and may exhibit either an intramural expansile, extramural (peritoneal) or polypoid (exophytic) growth pattern or a combination, thus resulting in an extremely diverse gross and clinical presentation. They are usually small, asymptomatic and diagnosed incidentally on imaging or colonoscopy. Rarely, few cases grow large enough to present with abdominal pain, lump or intestinal obstruction. Other symptoms may include bleeding, anaemia, early satiety or bloating¹⁴. Large exophytic growths are usually diagnosed and staged by CECT scans. The differential diagnoses include retroperitoneal mesenchymal neoplasms. The

diagnosis is established by a combination of histological features showing spindle cells and immunohistochemical assay for CD117, an epitope of c-kit receptor tyrosine kinase. However, other GI tumors that may test positive for CD117 include metastatic melanoma, clear-cell sarcoma (30% to 50%), Ewing's sarcoma (50%), childhood neuroblastoma (30%), angiosarcoma (50%), and some carcinoma. Besides, these GI tumors other differential diagnosis for CD117 positive cancers include mastocytoma, seminoma, pulmonary small cell carcinoma, and extramedullary myeloid tumors¹⁵. GISTs are known to arise from activating mutations of proto-oncogenes c-KIT or PDGFR α which increase tyrosine kinase receptor activity, resulting in uncontrolled proliferation of cells⁵. Surgical resection without lymph node dissection is the primary treatment of choice¹⁶. Tumor size and mitotic index are the two most important risk defining factors. With a tumor size > 10cm and mitotic rate >5/HPF, our patient was in the high risk group as per NIH consensus and stage III B as per 7th UICC/AJCC staging guidelines⁸⁻⁹. So, he was started on adjuvant oral Imatinib mesylate (400mg/day) for 1 year. Imatinib, a small molecule inhibiting the tyrosinase kinase activity of c-kit, PDGFR α , and BCR-ABL, is the first and only approved treatment for GIST. It was first approved by the FDA in 2001 for unresectable, metastatic or recurrent GIST. The efficacy rate (complete response + partial response) of imatinib has been reported to be 53.8%, and the disease-control rate (complete response + partial response + stable disease) to be 84%¹⁰. As per ACOSOG Z9001 trial the use of imatinib after radical surgery in high-risk cases gives a 14% absolute reduction in recurrence rate, achieving 97% recurrence-free survival⁷. The use of imatinib as an adjuvant therapy for patients after complete resection of localized, primary GIST was approved by FDA in 2008¹⁷.

CONCLUSION

Large extramural GISTs of jejunum are rare tumors. Surgery is the primary treatment for resectable cases. The diagnosis should be established with the help of both morphological and an immunohistochemical characteristic as its adjuvant treatment is different from other intestinal carcinomas and sarcomas. The treatment of GIST has been revolutionized with the use of Imatinib. Localized and resectable GIST has a good prognosis.

Disclaimer regarding Consent and Ethical Approval:

As per university standard guideline, participant consent and ethical approval have been collected and preserved by the authors

REFERENCES

1. Dhull AK, Kaushal V, Dhankhar R, Atri R, Singh H, Marwah N. The inside mystery of jejunal gastrointestinal stromal tumor: a rare report and review of the literature. *Case Reports in Oncological Medicine*. 2011;2011:4 pages.

2. Kindblom LG, Remotti HE, Aldenborg F, Meis-Kindblom JM. Gastrointestinal pacemaker cell tumor (GIPACT): gastrointestinal stromal tumors show phenotypic characteristics of the interstitial cells of Cajal. *Am J Pathol*. 1998;152(5):1259–1269.
3. Li FP, Fletcher JA, Heinrich MC, et al. Familial gastrointestinal stromal tumor syndrome: phenotypic and molecular features in a kindred. *J Clin Oncol* 2005;23:2735-43
4. Choi, H. Response evaluation of gastrointestinal stromal tumors. *Oncologist*. 2008;1(13): 4-7
5. Miettinen M, Majidi M, Lasota J. Pathology and diagnostic criteria of gastrointestinal stromal tumors (GISTs): a review. *Eur J Cancer*. 2002;38 Suppl 5:S39–S51.
6. Miettinen M, Makhoul H, Sobin LH, et al. Gastrointestinal stromal tumors of the jejunum and ileum: a clinicopathologic, immunohistochemical, and molecular genetic study of 906 cases before imatinib with long-term follow-up. *Am J Surg Pathol* 2006;30:477-89
7. Dematteo RP, Ballman KV, Antonescu CR, et al. Adjuvant imatinib mesylate after resection of localised, primary gastrointestinal stromal tumour: a randomised, double-blind, placebo-controlled trial. *Lancet* 2009;373:1097-104
8. Fletcher CD, Berman JJ, Corless C, et al. Diagnosis of gastrointestinal stromal tumors: A consensus approach. *Hum Pathol* 2002;33:459-65
9. Agaimy A. Gastrointestinal stromal tumors (GIST) from risk stratification systems to the new TNM proposal: more questions than answers? A review emphasizing the need for a standardized GIST reporting. *Int J Clin Exp Pathol* 2010;3:461-71.
10. Kubota, T. Gastrointestinal stromal tumor (GIST) and imatinib. *Int J Clin Oncol* 2006;11:184–189.
11. Reith JD, Goldblum JR, Lyles RH, et al. Extragastrintestinal (soft tissue) stromal tumors: an analysis of 48 cases with emphasis on histologic predictors of outcome. *Mod Pathol* 2000;13:577-85
12. Shanmugam S, Vijaysekaran D, Marimuthu MG. Gastro intestinal stromal tumor: A case report. *Indian J Radiol Imaging*. 2006;16:373-6.
13. Sornmayura P. Gastrointestinal stromal tumors: a pathology view point. *J Med Assoc Thai* 2009;92:124–35
14. Jaison J, Joshi SR, Pathak S, Tekwani D, Nagare M. Gastrointestinal Stromal Tumour at An Unusual Site Jejunum: A Case Report. *Int J Sci Stud* 2014;2(4):80-83.
15. Miettinen M, Lasota L. Gastrointestinal stromal tumors: review on morphology, molecular pathology, prognosis, and differential diagnosis. *Archives of Pathology and Laboratory Medicine*. 2006;10(130):1466–1478.
16. Demetri GD, Benjamin RS, Blanke CD, et al. NCCN Task Force report: management of patients with gastrointestinal stromal tumor (GIST)--update of the NCCN clinical practice guidelines. *J Natl Compr Canc Netw* 2007;5:S1-29.
17. John T Vetto. Role of imatinib in the management of early, operable, and advanced GI stromal tumors (GISTs). *Onco Targets Ther*. 2009;2:151–159.

Figures

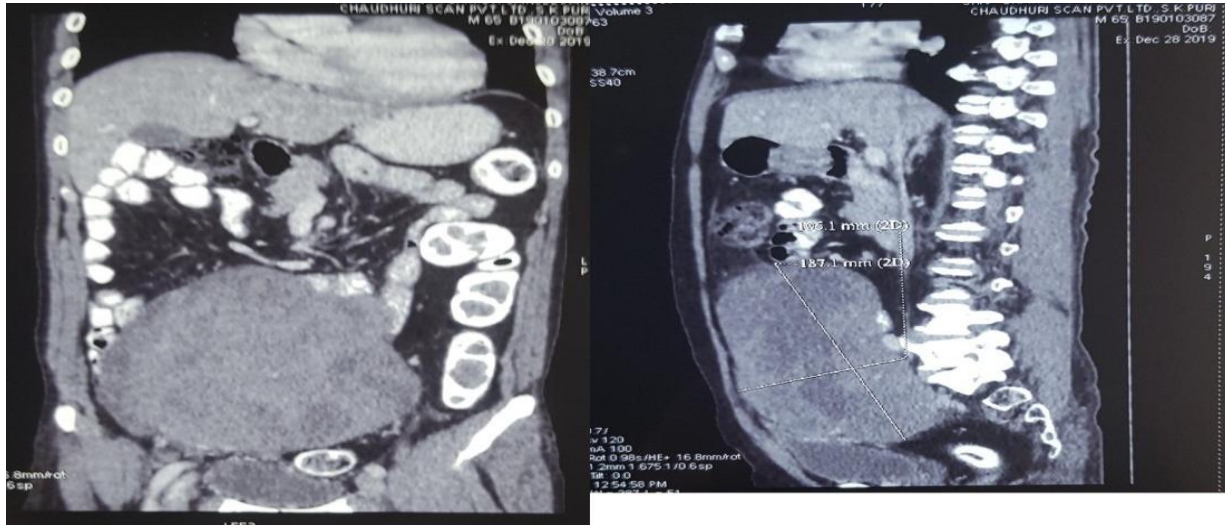


Figure 1: Coronal and Sagittal CECT Scan images showing large 17.4 x 17.1 x 9.5cm heterogeneously enhancing hypodense soft tissue lesion involving pelvis and rt. lower abdomen

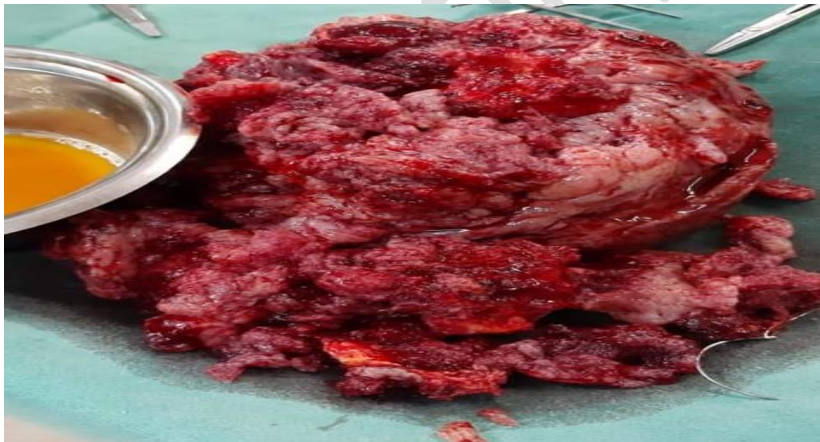


Figure 2: Post-op specimen showing a large nodular mass with separate multiple large areas of hemorrhage and necrosis, partly encapsulated by fibrous tissue.