

Ocular Chemical Injury: Role of Amphoteric Agents as An Alternative Irrigating Solution

ABSTRACT

Chemical eye injury is a true ocular emergency that requires a prompt decision and immediate management by using an irrigating solution to the eye. The development of a new solution, such as amphoteric agents are now used in comparison to conventional agents. This type of solution reacts rapidly with both acids and alkalis. It also has hypertonic properties, thus resulting in milder corneal edema and mobilizes the diffusion of corrosive agents out of the eye structure. Several studies indicated that the amphoteric solution had significantly better clinical and ocular outcomes compared to other irrigation fluids. Irrigation using amphoteric agents found to shorten the time of corneal reepithelization in Grade I-II chemical eye injury. It also resulted in a better outcome for visual acuity, pain intensity, severity of the injury, and less further complications. In conclusion, prompt eye irrigation using the amphoteric solution shown as a better alternative in chemical ocular injury. Thus, its usage may be suggested for future management for chemical eye injury.

Keywords: chemical eye injury, eye irrigation, amphoteric agents

1. INTRODUCTION

Chemical ocular injury is an emergency ocular condition that occurs when corrosive substances are introduced to the eye and its surrounding tissues.¹ Their occurrences may be due to the splash or spray of work-related and household chemicals, or even criminal assaults with strong alkali or acid.² Chemical injuries are a common cause of ocular trauma, accounting for an approximate prevalence of 8-18% of ocular traumas.^{3,4} In the United States, there are at least 35,996 visits per year in the emergency department due to chemical ocular injuries.⁵ Whereas in Germany, based on the emergency department registry data from two hospitals, an annual incidence of chemical ocular injury shows a number of 65-66 cases/year.⁶ This type of injury is most commonly found as an accident among the male industrial workers,⁷ although in a recent study it was found that these injuries may occur in individuals in the age range of 18-64 years and there was a significant increase in risk among infants aged 1-2 years.⁶

Despite the cause and circumstance of the injury, chemical exposure to the eye requires immediate management by performing irrigation to the affected eye.^{2,4} Irrigation is purposed to achieve a neutral intraocular pH before getting more advanced care by ophthalmologists.² Without the prompt treatment, the injury may cause an irreversible visual loss.⁴ Tap water and normal saline are the most frequently used solution due to its high availability and affordability.^{2,8} However, those solutions are hypotonic to the corneal stroma and might dilute the corneal tissue resulting in the possibility of further diffusion of the chemical agent to the cornea.^{8,9}

Nowadays, the use of amphoteric agents have currently become an innovative external irrigating solution in the management of chemical eye injury.⁶ Terminologically, an amphoteric compound is one that can react with both acids and bases.⁸ Several studies have shown that its usage revealed potential improvement of clinical outcomes in compared to the conventional buffers or electrolytic solutions.⁶ Amphoteric agents are known to have hypertonic properties, so it mobilizes water and corrosives out of the injured tissue.^{4,6,8,9}

Nevertheless, the clinical study regarding its usage among chemical eye injury patients is still quite limited. This review provides healthcare professionals with the new insight regarding the management strategies in chemical ocular injuries. This modern method is expected to result in better patient-related outcomes and lower risk of complications compared to conventional solutions alone.

2. PATHOPHYSIOLOGY OF OCULAR CHEMICAL INJURY

Corneal epithelium act as a protecting membrane that is localized between stroma and the medium of the corneal surface. The damage from chemical ocular injury initially progressed from the necrosis of the corneal epithelium, accompanied by the disruption and occlusion of limbal vasculature, so that the agent progressively invade stroma.⁹ It later causes burns followed by a surge of inflammatory cells to produce detergent enzymes, including matrix metalloproteinases (MMP), that further damaging the ocular structures.³ Breakdown of limbal stem cells results in conjunctivalization and vascularization of the corneal surface, persistent corneal defects, ulceration, and perforation. Due to the concentration gradient, water from the tear fluid or anterior chamber will penetrate the corneal layer, causing stromal edema.¹⁰ Deeper penetration may also cause the precipitation of glycosaminoglycans and stromal corneal opacification.⁹ The severity of injury depends on several factors, including the type, quantity, temperature, pH, concentration, site, and duration of exposure of the causative agent.^{1,3,4}

2.1 Acidic agents

Acid injuries tend to show less severe manifestation compared to alkali injuries.¹ It is because it has a lower pH value in the human eye and results in the precipitation of tissue proteins that acts as a barrier for deeper penetration.^{1,2,7} Acids also cause the shortening of collagen fibers, which subsequently result in a rapid increase of intraocular pressure. Sulfuric acid (battery, cleaner), acetic acid (vinegar), hydrochloric acid (laboratory chemical), sulfurous acid (refrigerant), hydrofluoric acid (glass polishing, gasoline alkylation, silicone production) and chromic acid are some high-concentrated acidic agents (pH 1.0-3.5) that commonly cause ocular trauma.^{3,7}

2.2 Alkaline agents

Alkalis cause proteolyzes, collagen synthesis damage, and saponification of fatty acid components within the tissue, and it does not form such a barrier that results in the rapid and deeper penetration to the ocular tissue.^{2,3,7} Alkalis are also responsible for the damage of the limbal stem cell, which leads to the opacification and neovascularization of the cornea. Shrinkage and contraction of the cornea also may occur, resulting in a rapid increase of intraocular pressure. Deep penetration may further alter the ocular structures, such as the iris, iridocorneal angle, ciliary body, and crystalline lens, causing extensive damage. Some examples of high-concentrated alkali substances (pH 12.0-14.0) that commonly found in ocular trauma are ammonia (fertilizer, refrigerant), sodium hypochlorite, lye, lime, sodium hydroxide, potassium hydroxide, and magnesium hydroxide.⁷

3. CLINICAL COURSE OF OCULAR CHEMICAL INJURY

Chemical ocular injury often manifests as corneal clouding, limbal whitening, and significant conjunctival chemosis.² This injury is often graded to determine the further treatments and prognosis.⁹ Grading is carried out using Hughes classification and then later modified by Roper-Hall system.^{11,12} This classification is based on the manifestation of corneal clarity and severity of limbal blanching or ischemia.^{7,9} Recent classification also has been proposed by Dua, which is based on the importance of the deficit of limbal stem cells to predict its impact on vision.¹³

Table 1. Hughes classification of chemical ocular injury¹¹, modified by Roper-Hall¹²

Grade	Corneal	Conjunctival Limbus	Prognosis
I	Clear cornea (epithelial damage only)	No limbal ischemia	Excellent
II	Hazy cornea with visible iris detail	Less than one-third limbal ischemia	Good
III	Total loss of corneal epithelium, stromal haze obscuring iris detail	Between one-third and one-half limbal ischemia	Guarded
IV	Opaque cornea	More than a half limbal ischemia	Poor

Table 2. Dua classification of chemical ocular injury¹³

Grade	Analogue Scale	Clinical Findings	Conjunctival Alteration (%)	Prognosis
I	0.0/0.0	0 clock hours of limbal involvement	0	Excellent
II	0.1-3.0/1.0-29.9	≤ 3 clock hours of limbal involvement	≤ 30	Good
III	3.1-6.0/31.0-50.0	>3-6 clock hours of limbal involvement	>30-50	Good
IV	6.1-9.0/51.0-75.0	>6-9 clock hours of limbal involvement	>50-75	Good to guarded
V	9.1-11.9/75.1-99.9	>9-<12 clock hours of limbal involvement	>75-<100	Guarded to poor
VI	12.0/100.0	Total limbus (12 clock hours) involvement	Total conjunctiva (100%) involvement	Very poor

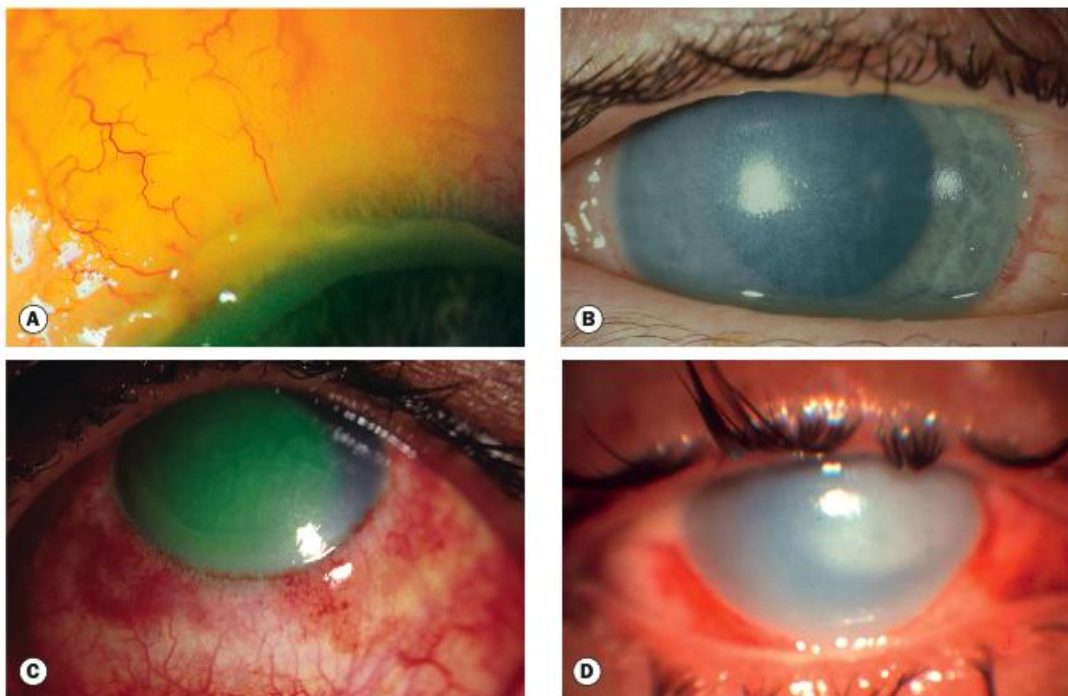


Fig. 1. Manifestation of ocular chemical injury. (A) Limbal ischemia; (B) Grade II ocular burn manifested as hazy cornea with visible iris details; (C) Grade III ocular burn manifested as hazy cornea obscuring iris details; (D) Grade IV ocular burn manifested as an opaque cornea.⁹

4. CONVENTIONAL IRRIGATION STRATEGIES

Immediate irrigation of chemically injured eyes prevents further damage to the eye in two ways, as it will dilute the harmful chemical agents and then continually neutralize the pH of the eye. However, the degree of effectiveness among various irrigation solutions are different. Buffer capacity, osmolarity, and availability are the factors that may determine the effectiveness of different irrigation solutions.¹⁰

Buffer capacity is the ability of the solution to absorb the high-concentration of acids or alkalis to maintain the neutral pH. Irrigating solution with high buffer capacity will initiate the swift binding of the harmful agent to achieve neutral pH. Osmolarity is defined as the concentration of osmotically active particles that influence the swelling and de-swelling capacity of the cornea. Difference of concentration gradient causes a diffusion of water from the lower side to the higher side of osmolarity.¹⁰

Irrigation using tap water remains the easiest step to be possibly done in the emergency management of ocular chemical injury.^{2,8,9} Some studies suggest a volume of 1.0-2.0 liters with an initial duration of no less than 15 minutes.^{3,7,8} Irrigation should continue to minimize the length of chemical exposure until the neutral pH has been achieved or definitive treatment has been provided. Determination of the type of chemical exposure is usually done after the initial irrigation using a pH litmus paper, as well as to evaluate the degree of acidity of the injured eye after irrigation.² When available, sterile normal saline, balanced salt solution (BSS), or Ringer's lactate are also commonly used to irrigate the affected eyes.^{3,9}

Water and normal saline have no to very low buffer capacity. These irrigating solutions also have a low concentration (hyposmolar) or almost iso-osmolar compared to corneal osmolarity (420 mOsm/L) and intraocular components.^{8,10} This may lead to an increase of diffusion of water and the corrosive agents, causing the swelling reaction to the cornea and further structural damage.¹⁰ Ringer's lactate and BSS are known to iso-osmolar in compare to aqueous humour^{3,8}, although they are known to have only low buffer capacity in compare to amphoteric agents.¹⁰ Phosphate buffer solution (PBS) is found to be an alternative, but an experimental study found that the phosphate reacts with the endogenous calcium released by injured cells resulting in stromal calcification.^{8,14}

5. EVIDENCES OF AMPHOTERIC AGENT USE IN IRRIGATION

Amphoteric agents are the newer and more effective neutralizing agents used for chemical ocular injury. This irrigating solution has a high-molecular amphoteric molecule that works as a buffer for both acid (H⁺) and alkali (OH⁻) ions. Amphoteric agents are known to have a high buffer capacity. They also have hyperosmolar property, allowing the irrigating solution to be more concentrated inside the corneal stroma, thus causing less edema and mobilization of corrosive agents out of the injured tissue.^{8,10} Diphoterine[®] or Previn[®] are commonly used as amphoteric agents in chemical injuries. Diphoterine[®] and Previn[®] solutions have mainly the same ingredients, except for different preservatives used in Germany (Previn[®] solution) and the rest of the world (Diphoterine[®] solution).⁶

Schrage *et al.* conducted the first ex vivo experiment comparing the effectiveness of Diphoterine[®] and normal saline in the eyes of rabbits that are injured by sodium hydroxide. The corneal surface pH was measured as 9±0 in the normal saline group and 7.5±0 in Diphoterine[®] group. Meanwhile, the anterior chamber pH was measured as 10±0 in the normal saline group and 9.35±0.3 in Diphoterine[®] group. These results showed a statistically significant difference in the buffering capacity of Diphoterine[®]. However, no significant clinical differences were found between the two groups, although the lens opacification and iris stroma atrophy were slightly milder among Diphoterine[®] group. This finding was probably due to the level of damage that was already quite severe in the cornea after the intentional injury. The pH measurement showed a value of 13, and in some literatures state that exposure to corrosive agents with a pH of more than 11.5 does cause irreversible damage.¹⁵

Rihawiet *et al.* conducted an in vitro experiment using 0,5 mol sodium hydroxide as corrosive agents. Several irrigating solutions, including tap water, normal saline, Ringer's lactate, PBS, borate buffer, and Diphoterine[®] or Previn[®], were then added, and the pH of each reaction was measured. The result of this experiment showed that there were no significant differences in buffering capacity among the irrigation solutions except for borate buffer and Previn[®]. This study also carried out an ex vivo aqueous humor pH measurement from injured rabbit eyes, which was found that either Diphoterine[®] and Previn[®] effectively reduced the intracameral pH (8.4 and 8.6 respectively) compared to other types of solutions.¹⁶

Goldich *et al.* performed the irrigation of chemically injured rabbit eyes using a 2% nitrogen mustard. Irrigation was done using Diphoterine[®] and normal saline as a comparison. This study found that in Diphoterine[®] group, the corneal opacity and neovascularization were less severe, and the development of iris atrophy was also delayed. The use of Diphoterine also provided a better intraocular pressure maintenance effect after the injury.¹⁷

Merle *et al.* compared the use of the physiological solution and amphoteric agent (Diphoterine[®]) in alkali injured eyes in humans. This study showed a shorter time of reepithelialization among the grade I-II injured eyes irrigated by Diphoterine group compared to physiological solution group (Grade I: 1.9±1 days vs. 11.1±1.4 days; grade II: 5.6±4.9 days vs. 10.0±9.2 days, respectively). Unfortunately, in this study, there were not enough cases to compare the differences in the effects of the two irrigating solutions on grade III-IV ocular chemical injury.¹⁸

Fortin *et al.* evaluated the subjective and objective clinical signs after the use of amphoteric agents among chemically injured eyes. This study found the statistically significant difference of median initial visual analogue scale (VAS) of 7 before the irrigation using an amphoteric agent, and the final score of 1 after the irrigation. Improvement of subjective symptoms such as blepharospasm, blurred vision, and palpebral edema were also noticed.¹⁹

A recent study done by Wiesner *et al.* compared the use of two different irrigation methods (normal saline or Ringer's lactate vs. Previn[®]) among chemically injured eyes in the hospital emergency department. This study showed that first-aid

irrigation using tap water or Previn[®] solution resulted in statistically significant better clinical outcomes compared to normal saline, Ringer's lactate, or isotonic phosphate buffer. Hospital setting or secondary irrigation using Previn[®] also decreased lesion severity in comparison with all other irrigating solutions.

6. CONCLUSION

Chemical ocular injury may cause devastating consequences to the eye and its surrounding structures. Immediate irrigation using the prompt solution is needed to prevent further and extensive ocular damage. Amphoteric agents are recommended as an alternative irrigating solution to be used for the emergency setting, especially in a work-related environment. Apart from its limited availability for household emergency use, the usage of this type of irrigation is highly recommended and should be readily available in the workplace and hospital setting.

CONSENT

It is not applicable.

ETHICAL APPROVAL

It is not applicable.

REFERENCES

1. Eslani M, Baradaran-Rafii A, Movahedan A, Djalilian AR. The ocular surface chemical burns. *J Ophthalmol.* 2014;2014:196827.
2. Pargament J, Correa ZM, Augsburger JJ. Ophthalmic trauma. In: Riordan-Eva P, Augsburger JJ, Vaughan & Asbury's General Ophthalmology, 19th Edition. 2018. New York: McGraw Hill. Page 836-837.
3. Mashige K. Chemical and thermal ocular burns: a review of causes, clinical features and management protocol. *South African Family Practice.* 2016;58(1):1-4.
4. Lewis CJ, Al-Mousawi A, Jha A, Allison KP. Is it time for a change in the approach to chemical burns? The role of Diphoterine[®] in the management of cutaneous and ocular chemical injuries. *J PlastReconstrAesthet Surg.* 2017;70(5):563-567.
5. Haring RS, Sheffield ID, Channa R, Canner JK, Schneider EB. Epidemiologic Trends of Chemical Ocular Burns in the United States. *JAMA Ophthalmol.* 2016;134(10):1119-1124.
6. Wiesner N, Dutescu RM, Uthoff D, Kottek A, Reim M, Schrage N. First aid therapy for corrosive chemical eye burns: results of a 30-year longitudinal study with two different decontamination concepts. *Graefe's Arch Clin Exp Ophthalmol.* 2019;257(8):1795-1803.
7. Singh P, Tyagi M, Kumar Y, Gupta KK, Sharma PD. Ocular chemical injuries and their management. *Oman J Ophthalmol.* 2013;6:83-86.
8. Kuckelkorn R, Schrage N, Keller G, Redbrake C. Emergency treatment of chemical and thermal eye burns. *Acta Ophth Scan.* 2002;80(1):4-10.
9. Salmon JF. *Kanski's Clinical Ophthalmology: a systematic approach*, 9th Edition. 2020. China: El Sevier. Page 912-916.
10. Kompa S, Schareck B, Tympner J, Wüstemeyer H, Schrage NF. Comparison of emergency eye-wash products in burned porcine eyes. *Graefe's Arch Clin Exp Ophthalmol.* 2002;240(4):308-313.
11. Hughes WF. Alkali burns of the eye. *Arch Ophthalmol.* 1946;35:423-436.
12. Roper-Hall MJ. Thermal and chemical burns of the eye. *Trans Ophthalmol Soc UK.* 1965;85:631-646.
13. Dua H, King AJ, Joseph A. A new classification of ocular surface burns. *Br J Ophthalmol.* 2001;85(11):1379-1383.
14. Schrage NF, Schlossmacher B, Aschenbrenner W, Langefeld S. Phosphate buffer in alkali eye burns as an inducer of experimental corneal calcification. *Burns.* 2001;27:459-464.
15. Schrage NF, Kompa S, Haller W, Langefeld S. Use of an amphoteric lavage solution for emergency treatment of eye burns: first animal type experimental clinical considerations. *Burns.* 2002;28(8):782-786.
16. Rihawi S, Frentz M, Schrage FM. Emergency treatment of eye burns: which rinsing solution should we choose?. *Graefe's Arch Clin Exp Ophthalmol.* 2006;244:845-854.
17. Merle H, Donnio A, Ayeboua L, et al. Alkali ocular burns in Martinique (French West Indies): evaluation of the use of an amphoteric solution as the rinsing product. *Burns.* 2005; 31:205-211.
18. Goldich Y, Barkana Y, Zadok D, Avni I, Berenshtein E, Rosner M, Chevion M. Use of amphoteric rinsing solution for treatment of ocular tissues exposed to nitrogen mustard. *Acta Ophthalmol.* 2013;91(1):e35-40.

19. Fortin JL, Fontaine M, Bodson L, Depil-Duvala A, Bitar MP, MacherJM, *et al.* Use of an amphoteric solution in eye, skin and oral chemical exposures: retrospective multicenter clinical case series. *J Clin Toxicol.* 2017;7(2): 1-9.

UNDER PEER REVIEW