

Role of Oats in ameliorating hepatic and renal toxicity induced by acute **Lead nanoparticles** in male rats

ABSTRACT

Aims: Lead is well known environmental pollutant, which can cause toxic effects in multiple organ systems. Lead originates from various industrial and/or household sources, and enters the body through food and fluid intakes, as well as by inhalation. No sufficient information present about the toxic effect of acute lead nanoparticles on kidney and liver. Accordingly, current study was performed to study the therapeutic effects of Oats extract towards the injection of **lead nanoparticles (Pb NPs)** in rat induced kidney and liver damage by increasing kidney and liver functions, and electrolytes.

Study design: A total of 40 male adult albino rats were equally divided into four groups (Control group, Oats group, Pb NPs group as acute toxicity and last group is Pb NPs +Oats).

Results: Current results revealed that; a significant increase in the levels of **serum aspartate transaminase (AST) and alanine transaminase (ALT), alkaline phosphatase (ALP)**, urea, creatinine, potassium and chloride ions after injection with Pb NPs as compared to control group. In contrast; a significant decrease in serum albumin, total proteins, and sodium ions in Pb NPs as compared to control groups. Treatment of Pb NPs with Oats improved this change in liver and kidney functions as compared to Pb NPs group.

Conclusion: These findings suggested that; **lead nanoparticles injection induced hepatic and renal damage. This shows that the desired dose of Pb NPs can safely be used with Oats in improving hepatic and renal damage in toxic group in young rats.**

Key words: Lead nanoparticles; Oats; Rats; Liver and kidney functions.

1. INTRODUCTION

During recent decade, major researchers focused their research towards nanotechnology and its applications all over the globe. Metal nanoparticles have gained more attention and play a major role in day by day due to its vast of area of application like development of biosensors etc [1, 2, 3]. **Nanoparticles had found a number of applications in everyday life. Despite of many benefits that nanomaterials, including nanoparticles (NPs), bring to the society, e.g. in drug delivery systems, medical devices, food products, cosmetics, etc. their increasing usage raises concern about the consequences and health threats that it might bring to humans. The risk of dermal, inhalation and ingestion exposure to NPs exist at many stages of NPs life cycle [1,3].**

Lead is well known environmental pollutant, which can cause toxic effects in multiple organ systems [4]. Lead continues to remain a persistent environmental health threat today. Exposure to lead can result in significant adverse health effects in multiple organ systems. Leads have toxic effects on the nervous, hematological, renal and reproductive systems have been studied extensively and have been documented in detail [5]. Lead originates from various industrial and/or household sources, and enters the body through food and fluid intakes, as well as by inhalation [6,7].

Children have been shown to be at greatest risk because of their enhanced gastrointestinal absorption of lead (40–50% vs. 10–15% in adults) and an incompletely developed blood-brain barrier [4]. Lead exposure increases the risk of diminished intelligence, attention deficit, hyperactivity disorder, school failure and criminal **behavior**, thus, there is no known safe level of exposure to lead [8]. Absorbed lead, which is not excreted out of body, is deposited primarily in mineralizing tissues (bones and teeth), which typically store the majority of the body burden of lead, and in soft tissue organs such as the liver, kidneys, lungs, brain, spleen, muscles and heart [4]. At a steady state, about 90% of lead in the human body was found in the skeleton of adults [5] and 73% in children,

respectively [7]. The half-life of lead in adult human blood has been estimated to range between 28 and 36 days [4]. Lead is excreted via the kidneys with a half-life of about 30 days under normal kidney function.

Recently, there is a marked increase in the use of complementary and alternative medicine [10-15]. Kidney and liver diseases is accompanying with extraordinary morbidity and mortality, and these diseases are associated with elevation oxidative damage, and endogenous and synthetic antioxidants [16-19].

Oats (*Avena sativa* L.) is an annual 1.5-m-high grass widely cultivated in cool and moist region of Northern Europe and North America. Oats are distinct among cereals due to their considerably higher protein concentration. Oat is mainly eaten as porridge, breakfast cereals, and baked goods (oatcakes, oat cookies, and oat bread) [20]. At the same time oats possess a protein quality of high nutritional value and a special protein composition. Most cereals like wheat, barley, and rye have a high percentage of prolamins, the alcohol-soluble fraction, which usually contains most of the storage proteins, but oats are an exception [20]. Their major storage proteins belong to the salt-water soluble globulin fraction, whereas oats prolamins are a minor component. During oats great development, most obvious is the fairly linear increase in the globulin fraction [21]. No sufficient information present about the toxic effect of acute lead nanoparticles on kidney and liver. Accordingly, current study was performed to study the therapeutic effects of Oats extract towards the injection of Lead Nanoparticles (Pb NPs) in rat induced kidney and liver damage by increasing kidney and liver functions, and electrolytes.

2. MATERIAL AND METHODS

2.1. Lead nanoparticles

Lead nano powder with a particle size less than 100 nm and a 99.9% trace metals basis was purchased from Sigma-Aldrich Chemicals, Cairo, Egypt.

2.1 Experimental Animals

The experiment was performed on 40 male albino rats (*Rattus norvegicus*) weighing 150 g (± 10) and of 9-10 weeks' age. They were obtained from the animal house of the National Research Center (Dokki, Giza, Egypt). The rats were housed in suitable plastic cages for one week before the experimental work for acclimation with a new room conditions and maintained on a standard rodent diet, with water available ad libitum. Animal maintenance and treatments were conducted by the Faculty of Science, Tanta University guide for the animal, as approved by the Institutional Animal Care and Use Committee (IACUC-SCI-TU-0185).

2.2 Experimental Design

A total of 40 male adult's rats were equally divided into four groups. Group 1, control includes animals that not given any drug; group 2, includes rats that receive Oats (intragastrically, 5 g/Kg body weight/ day); group 3, (Pb Nps) include animals that treated with Pb Nps (50 mg/Kg body weight/ day) for 1 weeks. In contrast; group 4, (Pb Nps+Oats) include animals that treated Pb Nps for one week and then with Oats for another 2 weeks.

2.3 Determination of Serum Enzymes

At the end of the experimental period, animals fasted overnight and blood samples were individually collected from the eyes by retroorbital puncture using blood capillary tubes without heparin as per requirement under mild ether anaesthesia for clinical chemistry examinations. Blood samples were incubated at room temperature for 10 minutes and left to clot then centrifuged at 3000 r.p.m for 10 min and the serum was collected, serum was separated and kept in clean stopper plastic vial at -80°C until the analysis of serum parameters [22].

2.3.1 Serum liver functions enzymes

Serum aspartate transaminase (AST) and alanine transaminase (ALT) activities were assessed in the sera as per [23, 24] respectively while serum alkaline phosphatase (ALP) levels were evaluated by [25]. Serum albumin were assessed by [22] while serum total proteins level was evaluated by [26].

2.3.2 Electrolytes and kidney functions biomarkers

Serum urea and creatinine were determined in the mouse sera according to [27]. The approach proposed by [28] was followed to measure the levels of serum electrolytes (Potassium, sodium, calcium and chloride ions) using commercial kits (Sensa core electrolyte, India).

2.4 Statistical Analysis

Data were expressed as mean values \pm SE and statistical analysis was performed using the unpaired t-test to assess significant differences among treatment groups. The criterion for statistical significance was set at $p < 0.05$ for the biochemical data. All statistical analyses were performed using SPSS statistical version 21 software package (SPSS® Inc., USA).

3. RESULTS

3.1 Liver function:

Figures (1) revealed that; a significant increase in the level of ALT, AST and ALP in the injected rats with lead nanoparticles (Pb Nps) as compared control group. In contrast; Figures (2) revealed a significant decrease in the levels of albumin and total proteins in the injected rats with lead nanoparticles (Pb Nps) as compared control group. On the other hand; treatment of lead nanoparticles with oats (Pb Nps+Oats) revealed a significant decrease in the levels of ALT, AST, ALP and a significant increase in the levels of albumin and total proteins as compared to injected rats with lead nanoparticles (Figures 1&2).

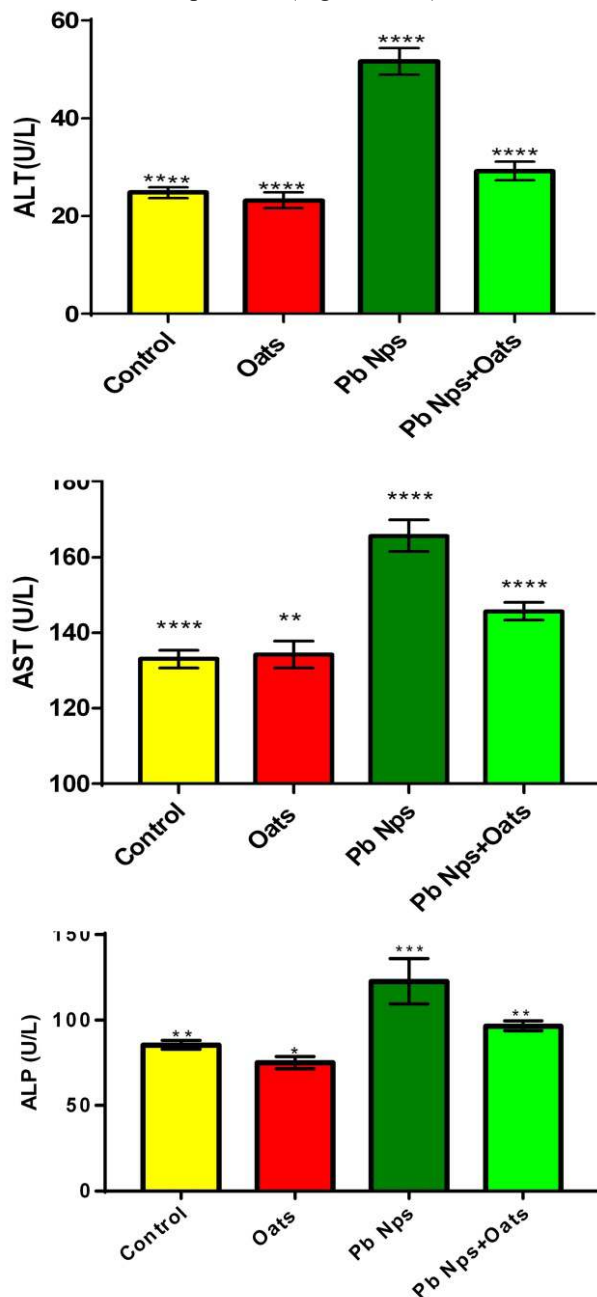


Figure 1: Changes in liver function as serum aspartate transaminase (AST), alanine transaminase (ALT) and alkaline phosphatase (ALP) levels in different groups. Data are expressed as mean \pm SE of 10 observations. The significance of difference was analyzed by one – way ANOVA and Dunnett test (compare all vs. Pb Nps group) using computer program. Values are expressed as means \pm SEM. one – way ANOVA was significant at $P < 0.05$. Dunnett test was significant from corresponding Pb Nps group value at * $P < 0.05$, ** $P < 0.01$, *** $P < 0.001$ and **** $P < 0.0001$.

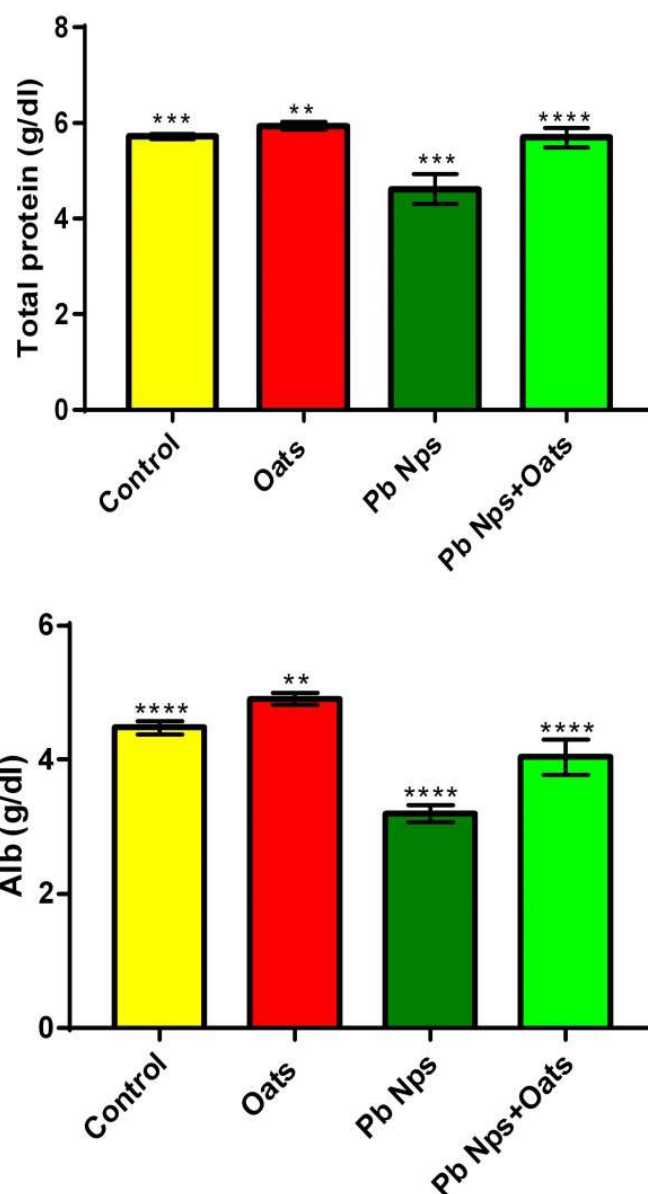


Figure 2: Changes in liver function as albumin (Alb) and total proteins levels in different groups. Data are expressed as mean \pm SE of 10 observations. The significance of difference was analyzed by one – way ANOVA and Dunnett test (compare all vs. Pb Nps group) using computer program. Values are expressed as means \pm SEM. one – way ANOVA was significant at $P < 0.05$. Dunnett test was significant from corresponding Pb Nps group value at $*P < 0.05$, $**P < 0.01$, $***P < 0.001$ and $****P < 0.0001$.

3.2 Kidney function:

Table (1) revealed that; a significant increase in the level of urea, creatinine, potassium and chloride ions in the injected rats with lead nanoparticles (Pb Nps) as compared control group. In contrast; a significant decrease in the levels of sodium and calcium ions in the injected rats with lead nanoparticles (Pb Nps) as compared control group (Table 1). On the other hand; treatment of lead nanoparticles with oats (Pb Nps+Oats) revealed a significant decrease in the levels of the level of urea, creatinine, potassium and chloride ions and a significant increase in the levels of sodium and calcium ions as compared to injected rats with lead nanoparticles (Table 1). Serum uric acid levels showed insignificant changes between different groups (Table 1).

Table 1: Variations in the serum kidney function (urea, creatinine, uric acid) and electrolytes as potassium (K⁺), chloride (Cl⁻), calcium and sodium ions(Na⁺) levels in different groups.

	Control	Oats	Pb Nps	Pb Nps+Oats
Urea (mg/dl)	31.6±1.691*	34.2±1.772*	39.8±0.860**	35.2±2.154**
Creatinine (mg/dl)	0.492±0.052**	0.492±0.051**	0.8±0.030***	0.584±0.020*
Uric acid (mg/dl)	3.618±0.065	3.59±0.0532	3.614±0.095	3.54±0.066
K ⁺ (mEq/L)	4.118±0.090**	4.002±0.059*	5.462±0.104****	4.916±0.217****
Na ⁺ (mEq/L)	135.4±0.32****	135.8±0.664****	122.2±0.522**	130±0.745**
Ca ⁺⁺ (mEq/L)	1.248±0.021****	1.272±0.017****	1.118±0.016**	1.164±0.025**
Cl ⁻ (mEq/L)	101.6±0.585**	100.7±0.372*	106±1.116****	104.2±0.937****

Data are expressed as mean ± SE of 10 observations. The significance of difference was analyzed by one – way ANOVA and Dunnett test (compare all vs. Pb Nps group) using computer program. Values are expressed as means ± SEM. one – way ANOVA was significant at $P < 0.05$. Dunnett test was significant from corresponding Pb Nps group value at * $P < 0.05$, ** $P < 0.01$, *** $P < 0.001$ and **** $P < 0.0001$.

4. DISCUSSION

Lead is an environmental pollutant with the largest toxicological database [8]. Exposure to lead can result in significant adverse health effects in multiple organ systems. Lead originates from various industrial and/or household sources, and enters the body through food and fluid intakes, as well as by inhalation [6, 7]. Children have been shown to be at greatest risk because of their enhanced gastrointestinal absorption of lead (40–50% vs. 10–15% in adults) and an incompletely developed blood-brain barrier [6]. Lead exposure increases the risk of diminished intelligence, attention deficit, hyperactivity disorder, school failure and criminal behavior, thus, there is no known safe level of exposure to lead [8]. Acute lead poisoning is characterized by non-specific symptoms such as abdominal pain (lead colic), joint pain, constipation, anorexia, muscle aches, headaches, decreased libido, sleep disturbance, irritability, fatigue, anemia, nephropathy, confusion, encephalopathy and seizures [8]. The current study was performed to study the therapeutic effects of Oats extract towards the injection of lead nanoparticles (Pb NPs) in rat induced kidney and liver damage by increasing kidney and liver functions, and electrolytes.

Liver enzymes (AST, ALT, ALP, albumin and total proteins) are considered as an important biomarker for the detection of lead hepatotoxicity. According to our results, lead caused a significant increase in AST, ALT and ALP levels versus the control group. In contrast; a significant decrease in albumin and total proteins. The changes in serum albumin provide valuable indices of severity, progress and prognosis in hepatic disease and this indicates hepatocellular origin of liver disease [25]. Decrease in albumin has been observed in serum of patients with tissue inflammation and damages [29]. Our results agree with [30] who studied the hepatotoxic effects of lead acetate in rats. Also [31] confirm our result and studied the ameliorative effect of curcumin against lead acetate-induced hemato-biochemical alterations, hepatotoxicity, and testicular oxidative damage in rats.

Urea is a waste item framed from the breakdown of proteins while creatinine is a waste item made by the muscles [17, 32]. Serum urea and creatinine are helpful records for assessing the status of renal capacity and the creatinine levels is typically a more exact marker of kidney work than urea [18]. The elevation serum urea levels may suggest debilitated renal discharge [33]. [34] who reported that; nanoparticles induced renal toxicity. Current results revealed that; treated rats with lead nanoparticles (Pb NPs) induced significant elevation in the levels of creatinine, urea, potassium ions and chloride ions, ($P < 0.01$) by comparison to the control and Oats groups. In contrast; decline in serum sodium ions were observed after the treatments of rats with Pb NPs. Post treatments of rats with Pb NPs and Oats extract (Pb NPs+Oats), improved the kidney functions and structure. This elevation in kidney functions is due to the abnormalities in kidney histological structure (data not shown). Our results align with [35] who stated that hydroxyapatite nanoparticles induced renal toxicity in male rats. Our results agree with [36] who reported that administration of Pb significantly increased the levels of renal function as creatinine, urea and uric acid. Our results in line of [37,38] who find that; treatments with TiO₂NPs induced elevations in the levels of urea creatinine and uric acid. This increase in potassium ions and the decrease in sodium ions levels may be due to kidney injury.

The current results indicate that administering Oats extract led to hepatic and renal structures being close to normal and very similar to the kidneys and livers retrieved from control animals. The reduction in the activities of ALT, AST, ALP, creatinine, urea, potassium and chlorides by Oats point to the compound exerting a hepato- and renal protective effect by stimulating antioxidative defence mechanisms, in addition to performing scavenging and or antioxidant properties [39, 40,41, 20].

5. CONCLUSION

These findings suggested that the misuse of lead nanoparticles may contribute to continuous hepatic and renal damage. This shows that the desired dose of PbNPs can safely be used with Oats in improving hepatic and renal damage in toxic group in young rats.

COMPETING INTERESTS DISCLAIMER:

Authors have declared that no competing interests exist. The products used for this research are commonly and predominantly use products in our area of research and country. There is absolutely no conflict of interest between the authors and producers of the products because we do not intend to use these products as an avenue for any litigation but for the advancement of knowledge. Also, the research was not funded by the producing company rather it was funded by personal efforts of the authors.

REFERENCES

- 1 Elango G, Roopan S.M. Green synthesis, spectroscopic investigation and photocatalytic activity of lead nanoparticles. *Spectrochimica Acta Part A: Molecular and Biomolecular Spectroscopy*. 2015; 139, pp.367-373.
- 2 Altwaijry N, El-Masry TA, Alotaibi B, Tousson E, Saleh A. Therapeutic effects of rocket seeds (*Eruca sativa* L.) against testicular toxicity and oxidative stress caused by silver nanoparticles injection in rats. *Environmental Toxicology*. 2020 Apr 15. <https://doi.org/10.1002/tox.22931>
- 3 El-Masry El-Masry T, Al-Shaalan N, Tousson E, Buabeid M, Al-Ghadeer A. Potential therapy of vitamin B17 against Ehrlich solid tumor induced changes in Interferon gamma, Nuclear factor kappa B, DNA fragmentation, p53, Bcl2, survivin, VEGF and TNF- α Expressions in mice. *Pak. J. Pharm. Sci.* 2020 Jan;33(1):393-401.
- 4 Dumková J, Smutná T, Vrlíková, L, Le Coustumer P, Večeřa Z., Dočekal B, Mikuška P, Čapka L, Fictum P, Hampl A, Buchtová M. Sub-chronic inhalation of lead oxide nanoparticles revealed their broad distribution and tissue-specific subcellular localization in target organs. *Particle and fibre toxicology*. 2017; 14(1), pp.1-19.
- 5 Lippmann M. *Environmental toxicants: human exposures and their health effects*. Hoboken: Wiley; 2000.
- 6 Wang M, Chen WH, Zhu DM, She JQ, Ruan DY. Effects of carbachol on lead-induced impairment of the long-term potentiation/depotentiation in rat dentate gyrus in vivo. *Food Chem Toxicol*. 2007; 45:412–8.
- 7 Nascimento C, Risso W, Martinez C. Lead accumulation and metallothionein content in female rats of different ages and generations after daily intake of Pb-contaminated food. *Environ Toxicol Pharmacol*. 2016; 48:272–7.
- 8 Grandjean P. Even low-dose lead exposure is hazardous. *Lancet*. 2010; 376:855–6.
- 9 Tousson E, Alghabban AJ, Harga HA. Thyroidectomy induced hepatic toxicity and possible amelioration by Ginkgo biloba leaf extract. *Biomedicine & Preventive Nutrition*. 2014;4(3):391-7.
- 10 Tousson E, Elgharabawy RM, Elmasry TA. Grape seed proanthocyanidin ameliorates cardiac toxicity induced by boldenone undecylenate through inhibition of NADPH oxidase and reduction in the expression of NOX2 and NOX4. *Oxidative medicine and cellular longevity*. 2018;2018. Article ID 9434385, 12 pages, <https://doi.org/10.1155/2018/9434385>
- 11 Tousson E, Bayomy MF, Ahmed AA. Rosemary extract modulates fertility potential, DNA fragmentation, injury, KI67 and P53 alterations induced by etoposide in rat testes. *Biomedicine & Pharmacotherapy*. 2018 Feb 1; 98:769-74.
- 12 Mutar TF, Tousson E, Hafez E, Gazia MA, Salem SB. Ameliorative effects of vitamin B17 on the kidney against Ehrlich ascites carcinoma induced renal toxicity in mice. *Environmental Toxicology*. 2020 Apr;35(4):528-537.
- 13 El-Masry T, Al-Shaalan N, Tousson E, ElMorshedy K, Al-Ghadeer A. P53 expression in response to equigan induced testicular injury and oxidative stress in male rat and the possible prophylactic effect of star anise extracts. *Annual Research & Review in Biology*. 2017;14(1):1-8.
- 14 El-Masry TA, Al-Shaalan NH, Tousson E, Buabeid M, Alyousef AM. The therapeutic and antineoplastic effects of vitamin B17 against the growth of solid-form Ehrlich tumours and the associated changes in oxidative stress, DNA damage, apoptosis and proliferation in mice. *Pak. J. Pharm. Sci.* 2019 Nov;32(6):2801-10.
- 15 El-Masry TA, Altwaijry N, Alotaibi B, Tousson E, Alboghhdady A, Saleh A. Chicory (*Cichorium intybus* L.) extract ameliorates hydroxyapatite nanoparticles induced kidney damage in rats. *Pak. J. Pharm. Sci.* 2020 May;33(3):1251-60
- 16 Salama AF, Kasem SM, Tousson E, Elsisy MK. Protective role of L-carnitine and vitamin E on the kidney of atherosclerotic rats. *Biomedicine & Aging Pathology*. 2012 Oct 1;2(4):212-5
- 17 Salama AF, Tousson E, Ibrahim W, Hussein WM. Biochemical and histopathological studies of the PTU-induced hypothyroid rat kidney with reference to the ameliorating role of folic acid. *Toxicology and industrial health*. 2013 Aug;29(7):600-8.

- 18 Oyouni AA, Saggu S, Tousson E, Rehman H. Immunosuppressant drug tacrolimus induced mitochondrial nephrotoxicity, modified PCNA and Bcl-2 expression attenuated by *Ocimum basilicum* L. in CD1 mice. *Toxicology reports*. 2018 Jan 1; 5:687-94.
- 19 Eldaim MA, Tousson E, El Sayed IE, El AE, Elsharkawy HN. Grape seeds proanthocyanidin extract ameliorates Ehrlich solid tumor induced renal tissue and DNA damage in mice. *Biomedicine & Pharmacotherapy*. 2019 Jul 1; 115:108908.
- 20 Aldubayan MA, Elgharabawy RM, Ahmed AS, Tousson E. Antineoplastic Activity and Curative Role of Avenanthramides against the Growth of Ehrlich Solid Tumors in Mice. *Oxidative Medicine and Cellular Longevity*. 2019;2019. ID 5162687, 12 pages <https://doi.org/10.1155/2019/5162687>
- 21 Biel W, Bobko K, Maciorowski R. Chemical composition and nutritive value of husked and naked oats grain. *Journal of cereal science*. 2009;49(3), pp.413-418.
- 22 Basuony M, Hafez E, Tousson E, Massoud A, Elsomkhraty S, Eldakamawy S. Beneficial role of panax ginseng root aqueous extract against cisplatin induced blood toxicity in rats. *Am J Biol Chem*. 2015;3(1):1-7.
- 23 El-Moghazy M, Zedan NS, El-Atrsh AM, El-Gogary M, Tousson E. The possible effect of diets containing fish oil (omega-3) on hematological, biochemical and histopathological alterations of rabbit liver and kidney. *Biomedicine & Preventive Nutrition*. 2014 Jul 1;4(3):371-7.
- 24 Al-Rasheed N, El-Masry T, Tousson E, Hassan H, Al-Ghadeer A. Hepatic protective effect of grape seed proanthocyanidin extract against gleevecinduced apoptosis, liver injury and ki67 alterations in rats. *Brazilian Journal of Pharmaceutical Sciences*. 2018; 54(2).
- 25 Moustafa A, Ali E, Moselhey S, Tousson E, El-Said K. Effect of coriander on thioacetamide-induced hepatotoxicity in rats. *Toxicology and Industrial Health*. 2014;30(7):621-9.
- 26 Tousson E, El-Moghazy M, Massoud A, El-Atrash A, Sweef O, Akel A. Physiological and biochemical changes after boldenone injection in adult rabbits. *Toxicology and industrial health*. 2016 Jan;32(1):177-82.
- 27 Tousson E, El-Atrash A, Karson Y. Protective Role of Rocket Seed (*Eruca sativa*) Extract against Monosodium Glutamate-induced Hepato-renal Toxicity in Male Rats. *Asian Journal of Research in Medical and Pharmaceutical Sciences*. 2019;1-0.
- 28 Abd Eldaim MA, Tousson E, El Sayed IE, Awd WM. Ameliorative effects of *Saussurea lappa* root aqueous extract against Ethephon-induced reproductive toxicity in male rats. *Environmental toxicology*. 2019 Feb;34(2):150-9.
- 29 Tousson E, Hafez E, Gazia MM, Salem SB, Mutar TF. Hepatic ameliorative role of vitamin B17 against Ehrlich ascites carcinoma-induced liver toxicity. *Environmental Science and Pollution Research*. 2020; 27:9236–9246
- 30 Haouas Z, Sallem A, Zidi I, Hichri H, Mzali, I, Mehdi M. Hepatotoxic effects of lead acetate in rats: Histopathological and cytotoxic studies. *Journal of Cytology & Histology*. (2014);5, 256.
- 31 Abdelhamid F.M, Mahgoub H.A, Ateya A.I. Ameliorative effect of curcumin against lead acetate-induced hemato-biochemical alterations, hepatotoxicity, and testicular oxidative damage in rats. *Environmental Science and Pollution Research*. 2020; pp.1-16.
- 32 Oyouni AA, Saggu S, Tousson E, Mohan A, Farasani A. Mitochondrial nephrotoxicity induced by tacrolimus (FK-506) and modulatory effects of *Bacopa monnieri* (Farafakh) of Tabuk Region. *Pharmacognosy Research*. 2019 Jan 1;11(1):20.
- 33 Alm-Eldeen A, Tousson E. Deterioration of glomerular endothelial surface layer and the alteration in the renal function after a growth promoter boldenone injection in rabbits. *Human & experimental toxicology*. 2012 May;31(5):465-72.
- 34 Iavicoli I, Fontana L, Nordberg G. The effects of nanoparticles on the renal system. *Critical reviews in toxicology*. 2016 Jul 2;46(6):490-560.
- 35 Mosa IF, Youssef M, Kamel M, Mosa OF, Helmy Y. Synergistic antioxidant capacity of CsNPs and CurNPs against cytotoxicity, genotoxicity and pro-inflammatory mediators induced by hydroxyapatite nanoparticles in male rats. *Toxicology Research*. 2019 Nov 1;8(6):939-52.
- 36 Ansar S, Farhat S, Albati A.A, Abudawood M, Hamed S. Effect of curcumin and curcumin nanoparticles against lead induced nephrotoxicity. 2019.
- 37 Song ZM, Chen N, Liu JH, Tang H, Deng X, Xi WS, Han K, Cao A, Liu Y, Wang H. Biological effect of food additive titanium dioxide nanoparticles on intestine: an in vitro study. *Journal of applied toxicology*. 2015 Oct;35(10):1169-78.
- 38 Hsu PC, Guo YL. Antioxidant nutrients and lead toxicity. *Toxicology*. 2002; 180:33–44. [https://doi.org/10.1016/s0300-483x\(02\)00380-3](https://doi.org/10.1016/s0300-483x(02)00380-3)
- 39 Okarter N, Liu RH. Health benefits of whole grain phytochemicals. *Critical reviews in food science and nutrition*. 2010 Mar 8;50(3):193-208.

- 40 Singh R, De S, Belkheir A. Avena sativa (Oat), a potential nutraceutical and therapeutic agent: an overview. *Critical reviews in food science and nutrition*. 2013 Jan 1;53(2):126-44.
- 41 Boz H. Phenolic amides (avenanthramides) in oats-a review. *Czech Journal of Food Sciences*. 2015 Sep 21;33(5):399-404.

UNDER PEER REVIEW