

Diethylcarbamazine (DEC) in Relapse cases of Nephrotic Syndrome in Filarial Endemic Region: A Case Series

Dr Jayendra R Gohil¹, Dr Tanmay P Vagh*², Dr Dimpal Patel², Dr Asha Patel²

1 Professor

2 Resident

*corresponding author

From- Department of Paediatrics, Govt. Medical College, Bhavnagar, Gujarat.364001

Author Contribution

This work was carried out in collaboration among all authors. Author JG designed the study and author TV wrote the first draft of the manuscript. Authors DP and AP managed the literature searches. All authors read and approved the final manuscript.

Abbreviations

UTI: urinary tract infection; DEC: diethylcarbamazine citrate; T temperature; AG abdominal girth; URTI upper respiratory tract infection; DOA day of admission; CP crystalline penicillin

Abstract

INTRODUCTION- Incidence of nephrotic syndrome (NS) and filariasis both is high in China, Japan & India. Studies have shown the association of filariasis in NS. In the coastal belt of Gujarat, Filariasis occurs as the mosquito responsible is still prevalent. Therefore, filariasis association may be causing persistence of oedema in NS relapse cases. After a 7th relapse patient was treated successfully with diethylcarbamazine citrate (DEC), we decided to study, the effect of DEC on weight loss and urine protein, in relapse patients of NS.

MATERIAL METHOD- In relapse patients of NS, DEC was given by oral route in the dose of 72 mg/kg/cycle for 7 days. Weight record and urine protein were measured daily. Steroid as Tab prednisolone was administered at 2 mg/k/d.

RESULTS- The 1st case was a steroid-dependent nephrotic syndrome with the 7th relapse; he had been on prednisolone and Levamisol for 3 years. DEC was started on day 3 of admission and response was seen on the 5th day. Urinary protein became nil on day 10, and the patient has been relapsing free for 1 year. In each of the other 4 cases with 1st, 2nd, 2nd and 4th relapse respectively, the response of DEC was seen within 2 days. Thus, after starting DEC weight and urine protein reduced within 2 days in 5 relapse cases. Filaria was not detected in blood film of any patient and Elisa tests are done in 2 were negative.

CONCLUSION- Further randomized studies with controls and better filarial detection methods are required for DEC to be considered as an add-on drug in relapse cases of NS in, Filarial endemic regions, as it is faster acting, effective, similar to Levamisol and safe.

Keywords

Nephrotic syndrome; Diethylcarbamazine DEC; Filariasis; Levamisole; Relapse; steroid-sensitive;

Introduction

Nephrotic syndrome is characterized by heavy (nephrotic range) proteinuria at >3.5 gm/24hr or a urine protein creatinine ratio >2, hypoalbuminemia (< 2.5 g/dl), hyperlipidaemia (cholesterol >200 mg/dl), and edema.[1]

Prednisolone suppresses autoimmunity in nephrotic syndrome & so induces remission early. But long term use of prednisolone can cause steroid toxicity [2]

Diethylcarbamazine citrate (DEC) is an anti-parasitic agent used in the treatment of lymphatic filariasis, tropical pulmonary eosinophilia, and loiasis & acts by inhibiting arachidonic acid metabolism. DEC alters organelle membrane of Mf (microfilariae) and affects the muscular activity of Mf. Side effects of DEC due to release of antigens from dying filariae are fever, skin rash, and swollen tender glands in the neck, visual disturbance, nausea, dizziness and itching.[3]

Levamisole as an immunomodulator for nephrotic syndrome is more effective in filarial endemic countries and the beneficial effect of levamisole are reported only from south-east Asian countries.[4] As we see glomerular pathology occurs because of parasitic infections, instead of using levamisole, we can use a more specific antifilarial agent, DEC, which has lower side effects.

Method

Here we are discussing the effect of DEC in minimal change nephrotic syndrome patients who had responded to steroids and who presented again with a relapse. DEC is not a 1st line treatment of nephrotic syndrome here, we were using it when such patients came with relapse.

Case presentation

In these five cases of relapse of nephrotic syndrome, each patient was treated as follows: Tab Prednisolone 2mg/kg/day till remission, and then switch over to alternate day therapy. Immuno-modulators are continued or added as required. DEC (Hetrazan[®] Wyeth) was started in all patients by oral route in the dose of 72mg/kg/cycle total dose over 7 days (Table 1). After admission, weight was recorded and urine protein was measured daily (Figure 3-7). Investigations are mentioned in Table 2.

Results - Course during treatment and Outcome

In the index case A, with 7th relapse, foci of infection were urinary tract infection (UTI) so treatment for UTI was started. Till 4th day no recovery was seen so considering relapse and no any recovery seen even after starting antibiotics so started DEC on 3rd day of admission (DOA). Oedema started to reduce on 5th DOA and slowly it disappeared on 8th DOA, urinary protein became clear on 9th DOA (figure 3).

In the 2nd case (B) with the 4th relapse, foci of infection were chronic tonsillitis so considering bacterial infection we started antibiotics but there was no response so DEC was started on 4th DOA and after that oedema gradually started to reduce on 6th day. (figure 4).

The 3rd case (C) was seen during the 2nd relapse. The foci of infection were UTI and treatment for UTI started. Even after 7 days, no signs of recovery were seen so we commenced DEC on the 7th DOA and after that oedema reduced on 9th DOA and Urinary Protein became clear on 10th DOA (figure 5).

In the 4th case (D) with 2nd relapse, foci of infection were due to tonsillitis and antibiotic was started. Even after 6 days on antibiotics no change in oedema and proteinuria was seen so DEC was started on 6th DOA

and after that oedema started to resolve slowly from the 7th DOA and Urinary Protein became clear on 9th DOA (figure 6).

The foci of infection in the 5th case (E), was pharyngitis and symptomatic and specific treatment was started. But no response till 6th day so DEC started on 6nd DOA and after that oedema started to reduce on 9th DOA & Urinary Protein became clear on 4th DOA (figure 7).

Filaria was not detected in midnight thick blood film of any patient. Elisa test done in 2 patients was negative. Thus it was seen that from case one to subsequent four cases, all responded rapidly following the introduction of DEC, within a week; which otherwise may take a longer time. This reduced the duration of therapy including steroids. No adverse events were detected by using DEC.

Table 1: Case Details

History	Examination	Treatment
A.4 Y/F: Eyelid and pedal swelling - 7 day abdominal distension - 3 days, decreased urine output - 2 days UTI (Ecoli +ve) 7 th relapse, steroid-sensitive	T Normal Eyelids swelling Pedal oedema (pitting), transverse umbilicus AG-64cm BP-94/68mmHg	Inj. ciprofloxacin(7day) Tab. levamisole (4day) Tab. Prednisolone (20mg) (8day) DEC for 7days Tab zinc for 12days
B. 2 Y/M: Swelling of the eyelid - 3days cough and cold - 2days Tonsilitis 4 th relapse, steroid-dependent	T-Normal AG-64cm, BP-96/70 mmHg Throat-congested, Tonsil enlarged Eyelids swelling Pedal oedema +(pitting)	Inj. Amoxiclav for 5 days Tab. Prednisolone for 6days DEC for 7days
C.5.5 Y/M: fever 4day, Eyelid swelling 4 days, Swelling over the abdomen for 2 days, UTI (urine pus cells) 2 nd relapse, steroid-sensitive	T-Normal AG-64cm BP-96/70 mmHg Pedal oedema + transverse umbilicus	Inj. ciprofloxacin (10 d) Tab. Prednisolone (10 d) Tab. amoxicillin (1day) DEC for 7days Tab zinc for 11days
D.6 Y/F: eyelid swelling- 2 days Pedal swelling- 2 days Cough- 2 days, Tonsilitis 2 nd relapse, steroid-sensitive	T-Normal AG-60cm, BP- 100/70 mmHg Throat congested, Tonsil enlarged Eyelid swelling Pedal oedema (pitting)	Inj. amoxiclav for 4 days Tab. prednisolone for 4 days DEC for 7 days
E.6 Y/M: eyelid swelling - 3 days, swelling over abdomen - 3 days Pharyngitis 1 st relapse, steroid-sensitive	T-Normal AG-62cm, BP-98/66 mmHg Throat-congested PA-visible veins, oedema over abdomen, liver+2cm	Inj. CP for 5 days Inj. amoxiclav for 4 days Tab. prednisolone for 9 days DEC for 7days

T temperature, AG abdominal girth, CP crystalline penicillin, DEC diethyl carbamazine citrate, UTI urinary tract infection; *Doses*- Inj. ciprofloxacin- 10mg/kg/d; Tab. Levamisole- 2mg/kg/d, 3d in a week for 6 week; Tab. Prednisolone- 2mg/kg/d; DEC- 72mg/kg/cycle; Tab zinc- 20mg/d; Inj. CP- 50,000 IU/kg/dose; **Amoxiclav**- amoxicillin +clavulanic 30mg/kg 8 hourly.

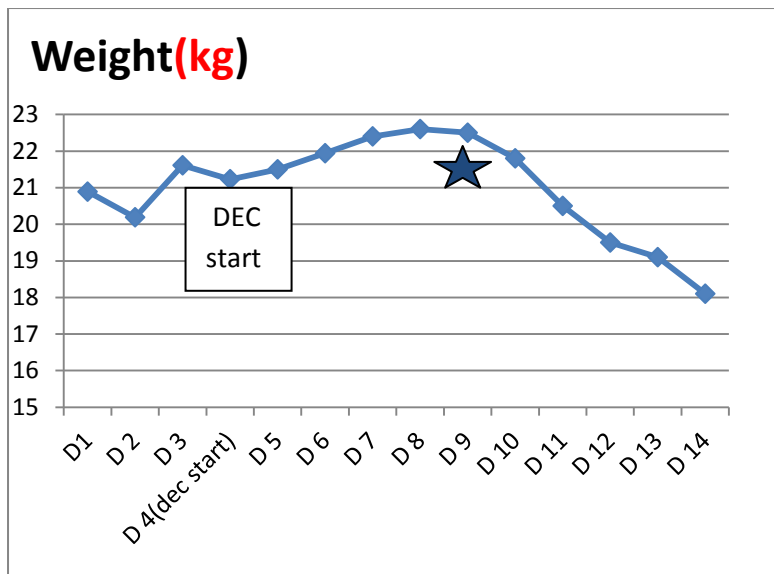
Table 2: Investigations on admission

Investigations	Case 1	Case 2	Case 3	Case 4	Case 5
Total Protein (g/dl)	3.9	4	4.02	3.92	3.2
S. Albumin (g/dl)	1.42	1.5	1.42	1.63	2.1
S. Globulin (g/dl)	2.48	2.5	2.60	2.29	2.8
A/ G ratio	0.57	2.5	0.55	0.71	0.75
S. Cholesterol (mg/dl)	525	385	467	321	320
24hr Urine Protein (mg/24hr)	>2000	670	452	395	410
Urine Protein Creatinine ratio (mg/mg)	7.9	9.19	12.85	12.5	8
Weight (kg) Maximum/ on discharge	21.9/ 18.1	20/ 18.8	21.3/ 19.3	20.2/ 18.2	20.6/ 18.2

S serum; A/G serum albumin/ globulin ratio

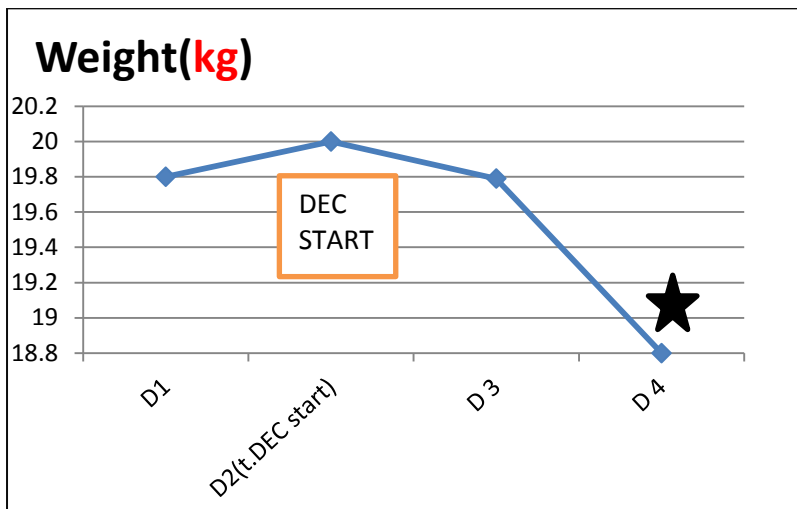
Normal values: T. protein 6-8g/dl; S. Albumin 3.5-5g/dl; S.Globulin-0.5-3g/dl; A/G ratio-0.8-2.0; S. cholesterol <200mg/dl; 24hr urine protein 30-150 mg/24hr; Urine protein creatinine ratio <0.2mg/mg

Figure 3: Case A-4yr female- 7th Relapse



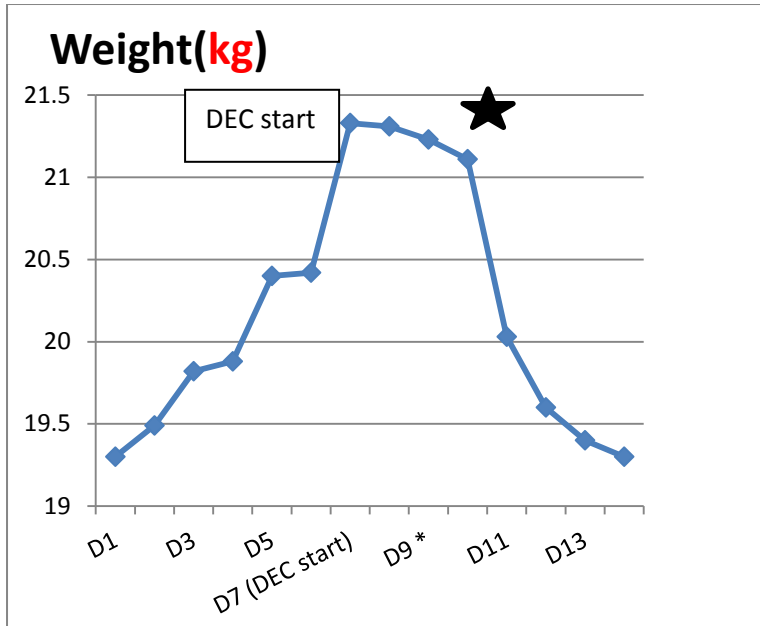
★ ----Shows urine Urinary Protein becomes nil

Figure 4: Case B 2yr male 4th Relapse



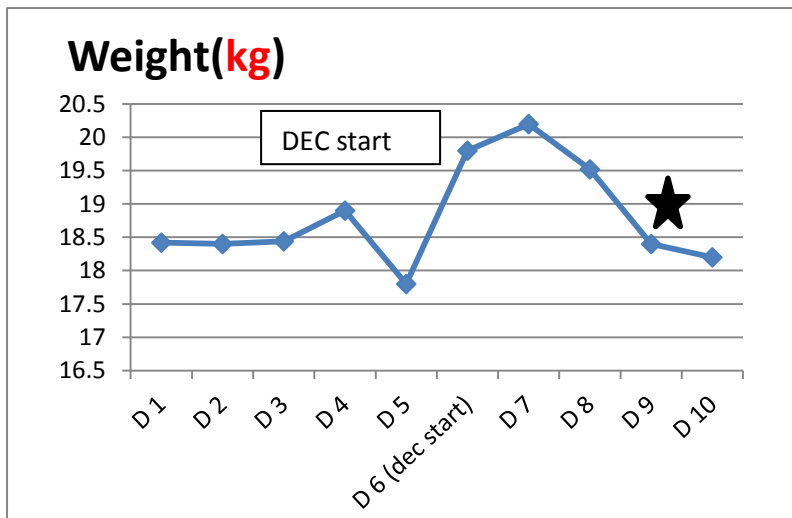
★----Shows urine Urinary Protein becomes nil

Figure 5: Case C. 5.5yr male -2nd relapse



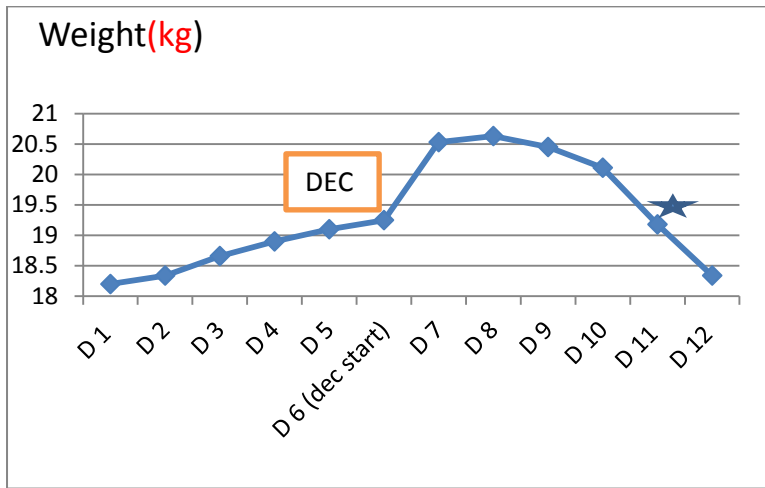
★----Shows urine Urinary Protein becomes nil

Figure 6: Case D -6yr Female – 2nd relapse



★ ----Shows urine Urinary Protein becomes nil

Figure 7: Case E .6yr Male -1st Relapse



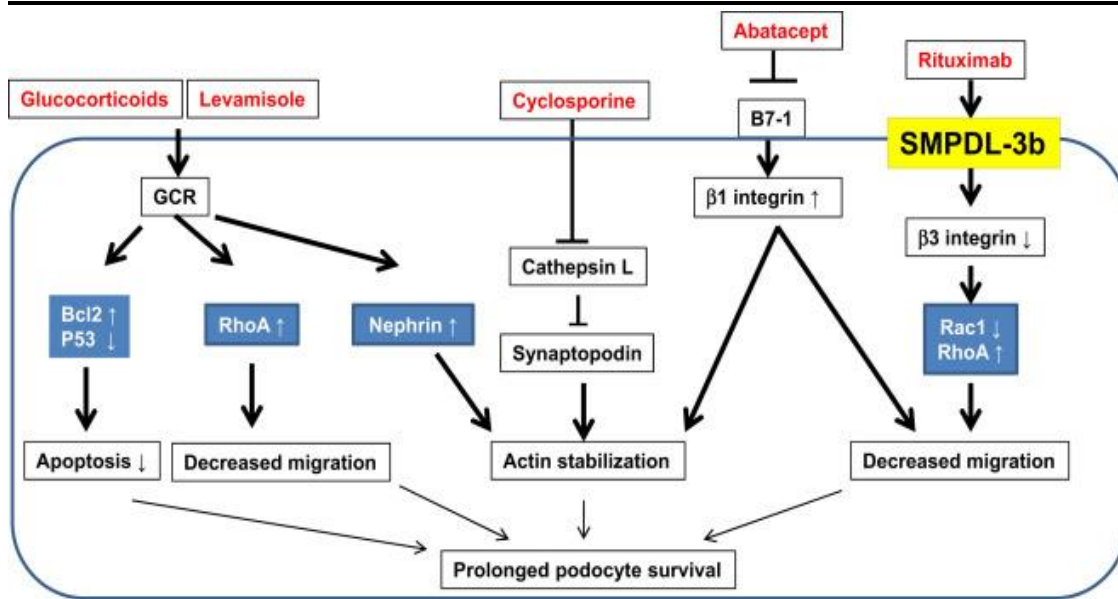
★ - Shows urine Urinary Protein becomes nil

Discussion:

It is a denovo study in nephrotic syndrome patients. Initially, reports were done to find out any foci of infection and as per the report, symptomatic management was done. Still, in all these cases oedema and heavy range proteinuria did not disappear so considering the connection of nephrotic syndrome with filariasis we started DEC. After starting DEC as effect occur initially weight loss starts slowly and urine heat coagulation becomes clear day by day.

In 1966, new drug levamisole was discovered [5] and due to its immunomodulatory property [6], its use had been increased in the frequent relapsers, steroid-resistant & steroid-dependent nephrotic syndrome. But its side effects like leucopenia, rash, seizures limit its use in nephrotic syndrome [7]. Levamisole attenuates podocyte apoptosis and increase in RhoA (ras homolog family member A) activity and decrease in degradation of synaptopodin protein, and so prolonging podocyte survival[8].

Figure 1 Mechanism of action of Drugs used in Nephrotic Syndrome (Figure reproduced from ‘Nonimmunologic targets of immunosuppressive agents in podocytes’ by Yoo TH [8])



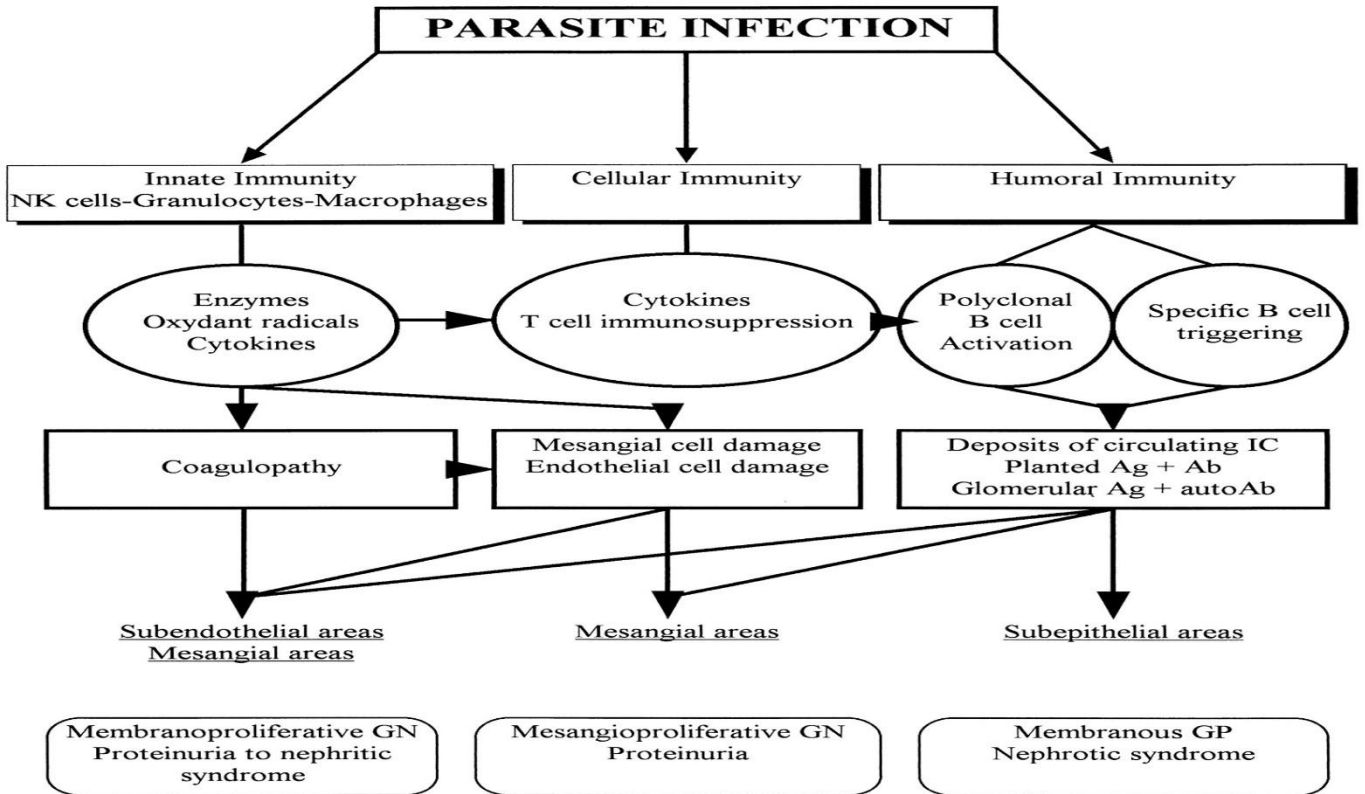
GCR=Glucocorticoid receptor; Bcl2=B cell lymphoma 2; p53= tumour protein 53; b7-1=membrane protein; RhoA=ras homolog family member A; SMPD-3B=Sphingomyelin phosphodiesterase acid-like 3B; Rac1=Rac family small GTPase 1

Incidence of nephrotic syndrome was quite high in China, Japan, India and many Asian countries in the 1950s[9] and incidence of lymphatic filariasis was also quite high in those countries.[10] There is a clear association of filariasis and nephrotic syndrome.[11] In the Coastal belt of Gujarat, filariasis still occurs as the mosquito responsible for it, therefore filariasis association causing persistence of oedema in nephrotic syndrome is possible. However, this (Bhavnagar) being an endemic coastal belt for filariasis and presentation with oedema, so we decided to introduce DEC, an anti-filarial drug.

After filarial infection of the human body, the generated toxins affect several compartments of the immune system. And play a role in fighting parasitic infections & in the pathogenesis of associated glomerulopathies. During infection, released inflammatory mediators directly damage the different glomerular cell types & participate in the activation of specific subsets of T and B cells, resulting in different levels of antigen, antibody & immune complexes. Depending on the site of the immune-complex deposition and on the type of primary damaged glomerular cells, different glomerular lesions develop.[12]

DEC works well in filariasis and other parasitic infections and due to serious side effects of levamisole & due to the possible association of filariasis with nephrotic syndrome, it can be used in nephrotic syndrome as it is cost-effective and safety is better than levamisole.

Figure 2 Effect of Parasitic Infection (Figure reproduced from 'The nephrotic syndrome associated with filariasis' study done by Yap HK[11])



NK cell=Natural killer cell; GN=glomerulonephritis; Ag=antigen; Ab=Antibody; GP-glomerulopathy

Conclusion

As per above case reports, after Starting DEC, weight and urine protein started to reduce within 2 days in the first difficult case and subsequent 4 more cases of NS relapse in the filarial endemic belt at Bhavnagar. The mechanism could be that DEC works well in filariasis and has also effects on an immune system similar to Levamisole that is used as an immunomodulator. However, both also act as an anti-filarial agent. It is cost-effective and safe. *However, DEC needs to be studied in a further randomized controlled study with efforts to detect filarial antigen* for it to be considered in relapse cases of NS in Filarial endemic regions.

What is already known?

Levamisole is used for steroid-dependent nephrotic syndrome. It is also a wormicidal drug acting on filarial worms. Filaria has been linked with minimal change nephrotic syndrome and filarial antigen has been observed in kidney biopsy. Diethylcarbamazine (DEC) is the drug of choice for Filarial infection.

What did this Case Series add?

The effect of DEC (when added to Prednisolone) in relapse cases of nephrotic syndrome in the filarial endemic region appears to reduce oedema and proteinuria within 3-4 days of administration. **DEC needs to be studied in further trials** with control, for relapse cases of NS.

Limitations

This is a *denovo case series* and it is a proof of concept case series. A study with control and filarial confirmation is recommended.

Funding: No grant was received; there is no conflict of interest.

Ethical Approval:

As per international standard, written ethical approval has been collected and preserved by the author(s).

Consent

As per university guideline, participant consent has been collected and preserved by the authors.

References

1. Pais P, Eliis DA. Nephrotic syndrome, in Nelson Textbook of Pediatrics, Kleigman RM, Stanton BF, Geme JW, Schor NF, Behrman RE, Saunders Elsevier, 2012;19:1801-06.
2. Hahn D, Hodson EM, Willis NS, Craig JC. Corticosteroid therapy for nephrotic syndrome in children. Cochrane Database of Systematic Reviews 2015, Issue 3: CD001533.
3. WHO Model Prescribing Information: Drugs Used in Parasitic Diseases – 2/e: Helminths: Lymphatic filariasis: Diethylcarbamazine. *who.int*. 1995. p. 152
4. Kuhlmann FM, James MF. Antiparasitic Agents. *Infectious Diseases*. 2017;4(2)1345-1372.
5. Narasimham MV, Roychowdhury SP, Das M, Rao CK. Levamisole and mebendazole in the treatment of bancroftian infection. *Southeast Asian J Trop Med Public Health*. 1978 Dec;9(4):571-5.
6. Gupta M. Levamisole: A multi-faceted drug in dermatology. *Indian J Dermatol Venereol Leprol* 2016;82:230-6.
7. Symoens J, Veys E, Mielants M, Pinals R. Adverse reactions to levamisole. *Cancer Treat Rep* 1978;62(11):1721-30. PMID: 365327
8. Yoo TH, Fornoni A. Nonimmunologic targets of immunosuppressive agents in podocytes. *Kidney Res Clin Pract*. 2015;34(2):69–75.
9. Pal A, Kaskel F. History of nephrotic syndrome and Evolution of its Treatment. *Front Pediatr*. 2016;4:56
10. SudomoM, Chayabegara S, Duong S, Hernandez L, Wu WP, Bergquist R. Elimination of Lymphatic Filariasis in Southeast Asia. *Advances in Parasitology* 2010;72(C)205-33.
11. Yap HK, Yeo PP, Chiang GS, Singh M, Lim CH. The nephrotic syndrome associated with filariasis. *Ann Acad Med Singapore* 1982;11:60-3.
12. van Velthuysen MLF. Glomerulopathy associated with parasitic infections. *Parasitol* 1996;12:102–107.