

**KIKUCHI FUJIMOTO DISEASE – A DIAGNOSTIC CHALLENGE**

**ABSTRACT**

Kikuchi-Fujimoto Disease is an extremely rare entity characterized by subacute necrotizing lymphadenitis and frequently associated with fever. It is known to have a worldwide distribution with higher prevalence among Japanese and other Asiatic young individuals. The clinical, histopathological and immunohistochemical features appear to point to a viral etiology, a hypothesis that still has not been proven and the cause remains uncertain. It is generally diagnosed on the basis of an excisional biopsy of affected lymphnodes. The diagnosis is crucial **Early diagnosis with excisional lymph node biopsy is crucial** as this disease can be mistaken for Systemic Lupus Erythematosus (SLE) or lymphoma and **to avoid unnecessary investigations.** **The treatment is only symptomatic unless complicated, where steroid therapy is considered.** **Kikuchi's disease has an excellent prognosis with almost no risk.** **Because of the rarity and difficulty in diagnosis, we thought of publishing the case.**

**KEY WORDS**

Necrotising Lymphadenitis, Adults, Asia

## INTRODUCTION

Kikuchi Fujimoto Disease (KFD) was first reported in Japan almost simultaneously by Kikuchi (1) and Fujimoto (2) in 1972. It is a benign and self-limiting disease that classically presents with lymphadenopathy and fever. The etiology is has poorly understood. The searched literature did not show incidence rates. Although seen worldwide, it is known to be much more prevalent in Asian populations (3). Indeed, a comprehensive literature review of KFD cases in 2003 described it as being “scarce in the western world” (4). KFD is prevalent in younger population.(3,4,5) Histologically, lymphadenitis is characterized by paracortical lymph node expansion with patchy, well-circumscribed areas of necrosis showing abundant karyorrhectic nuclear debris and absence of neutrophils and eosinophils. The histological differential diagnosis of KFD includes reactive lesions as lymphadenitis associated with Tuberculosis, Histoplasmosis, Leprosy, Syphilis, Infectious mononucleosis, SLE or herpes simplex , non-Hodgkin's lymphoma, plasmacytoid T-cell leukemia, myeloid tumor and even metastatic carcinoma.(5) Treatment is symptomatic with analgesics-antipyretics, non-steroidal anti-inflammatory drugs and, rarely, corticosteroids. Spontaneous recovery occurs in 1 to 4 months. Patients with Kikuchi-Fujimoto disease need long term follow up to survey the possibility of the development of SLE.

## CASE REPORT

A 32-year male was referred for of cervical lymphnode biopsy having multiple bilateral neck nodules associated with low grade fever for last four months. The size of nodules was increasing slowly and didn't respond to a course of antibiotics prescribed by his physician. On examination the nodules were multiple, nonmatted, soft to firm, freely mobile, nontender with largest being of size 2x2 cm. He also had bilateral axillary lymphadenopathy. He didn't have history of allergy. His systemic examination i.e. Cardiovascular, Respiratory, Abdominopelvic and Nervous systems were within normal limits. A possible diagnosis of tuberculosis was considered and the patient was sent for investigations. Complete blood count showed lymphocytosis and elevated E.S.R. (20 mm at the end of one hour by Wintrobe's method). Rest all parameters were within normal limits. His X-ray chest was done and was reported by radiologist as (Rt) hilar lymphadenopathy likely of infective origin, rest of the lung parenchyma and bony cage did not show any abnormality. The Tuberculin test had induration of 3 mm after 48 hours. With multiple lymphadenopathies, he was referred for USG Abdomen and Pelvis, which ruled out hepatosplenomegaly and abdominal lymphadenopathy. (Rt) neck cervical lymphnode biopsy was done, two intact nodes were removed and sent for histopathology examination. On gross examination, two whitish rounded 2x1 and 1.5x1 cm soft tissue masses were seen. Cut surface had capsule and uniform whitish areas. No caseation was seen. Histologically the sections showed fibrous capsule and beneath maintained lymphoid architecture (Fig.1 ) with paracortical expansion by necrotic areas showing admixture of histiocytes, plasmacytoid dendritic cells, lymphocytes and karyorrhectic debris.(Fig 2) No neutrophils or eosinophils were seen. There was no evidence of Reed Sternberg cells, granuloma or metastatic deposits. Ziehl Neelsen (ZN) stain was negative for acid fast bacilli. The diagnosis

of Lymphadenitis of Kikuchi Fujimoto type was conveyed. On immunohistochemistry (IHC), CD 20 and CD 3 highlighted “B” and “T” lymphocytes, CD 68 histiocytes, CD 123 plasmacytoid dendritic cells and CD 30 highlighted scattered immunoblasts. Ki 67 was 95% in lymphoid follicles and 15% in interfollicular areas. Thus, IHC ruled out lymphoma and also confirmed our diagnosis.

## **DISCUSSION**

Kikuchi Fujimoto Disease was discovered in 1972 in Japan by two separate groups. Its exact incidence is unknown, but it is more prevalent in East Asia. Kikuchi's disease is seen more frequently in young adults, with a mean age between 20–30 years but it can occur in any age group. Even though a female predominance is reported in many previous cases, some studies done in Asia show a male to female ratio of 1:1.(4,5) The definitive diagnosis of KFD can be made only through lymph node biopsy and histological examination. Even with adequate tissue the lymph node appearances can be mistaken for malignant lymphoma; in one study, 30% of lymph node biopsies in KFD were initially misdiagnosed as lymphoma. The histopathological features of KFD have been classified into three stages: (1) proliferative stage, with expression of histiocytes, plasmacytoid monocytes, and lymphoid cells containing karyorrhectic nuclear fragments and eosinophilic apoptotic debris; (2) necrotizing stage, with a degree of coagulative necrosis; and (3) xanthomatous stage, with foamy histiocytes predominating. A characteristic and useful diagnostic feature is the absence of granulocytes in the “necrotizing stage”, which is helpful in distinguishing KFD from SLE and drug induced lymphadenopathy. (4,5)

## **CONCLUSION**

Kikuchi-Fujimoto disease poses significant diagnostic challenges to pathologists and clinicians as it can easily be mistaken for other benign lymphadenopathies or infectious lymphadenitis as well as lymphomas. Clinicians' and pathologists' awareness of this disorder can help to avoid misdiagnosis of lymphoma and prevent further expensive and invasive investigations, as well as potentially harmful treatments and psychological stress to the patient. Excisional lymph node biopsy provides the optimal specimen for diagnosis of KFD.

## **Consent Disclaimer:**

As per international standard or university standard, patient's consent has been collected and preserved by the authors.

## **REFERENCES**

- 1) Kikuchi M: Lymphadenitis showing focal reticulum cell hyperplasia with nuclear debris and phagocytes: a clinicopathological study. *Acta Hematol Jpn* 1972, 35:379-380.
- 2) Fujimoto Y, Kozima Y, Yamaguchi K: Cervical subacute necrotizing lymphadenitis: a new clinicopathologic entity. *Naika* 1972, 20:920-927.
- 3) Xavier Bosch and Antonio Guilabert. Kikuchi-Fujimoto disease. *Orphanet Journal of Rare Diseases* 2006, 1:18
- 4) Matthew R. Wilson, Gordon Milne, and Evangelos Vryonis. Kikuchi-Fujimoto Disease: A Rare Cause of Fever in the Returning Traveller. *Case Reports in Medicine* Volume 2014, Article ID 868190,
- 5) Anamarija M. Perry, Sarah M. Choi Kikuchi-Fujimoto Disease: A Review *Arch Pathol Lab Med*—Vol 142, November 2018

## **LEGENDS TO FIGURES**

- 1) Fig. 1 shows fibrous capsule (yellow arrow head) and beneath lymphnode architecture maintained and hyperplastic follicles (red arrow) and dilated sinuses. (H & E 5x X 10x)
- 2) Fig. 2 shows areas of necrosis (green arrow) surrounded by chronic inflammatory cells (yellow arrowhead) and histiocytes (red arrow) . ( H & E 10x X 40x)

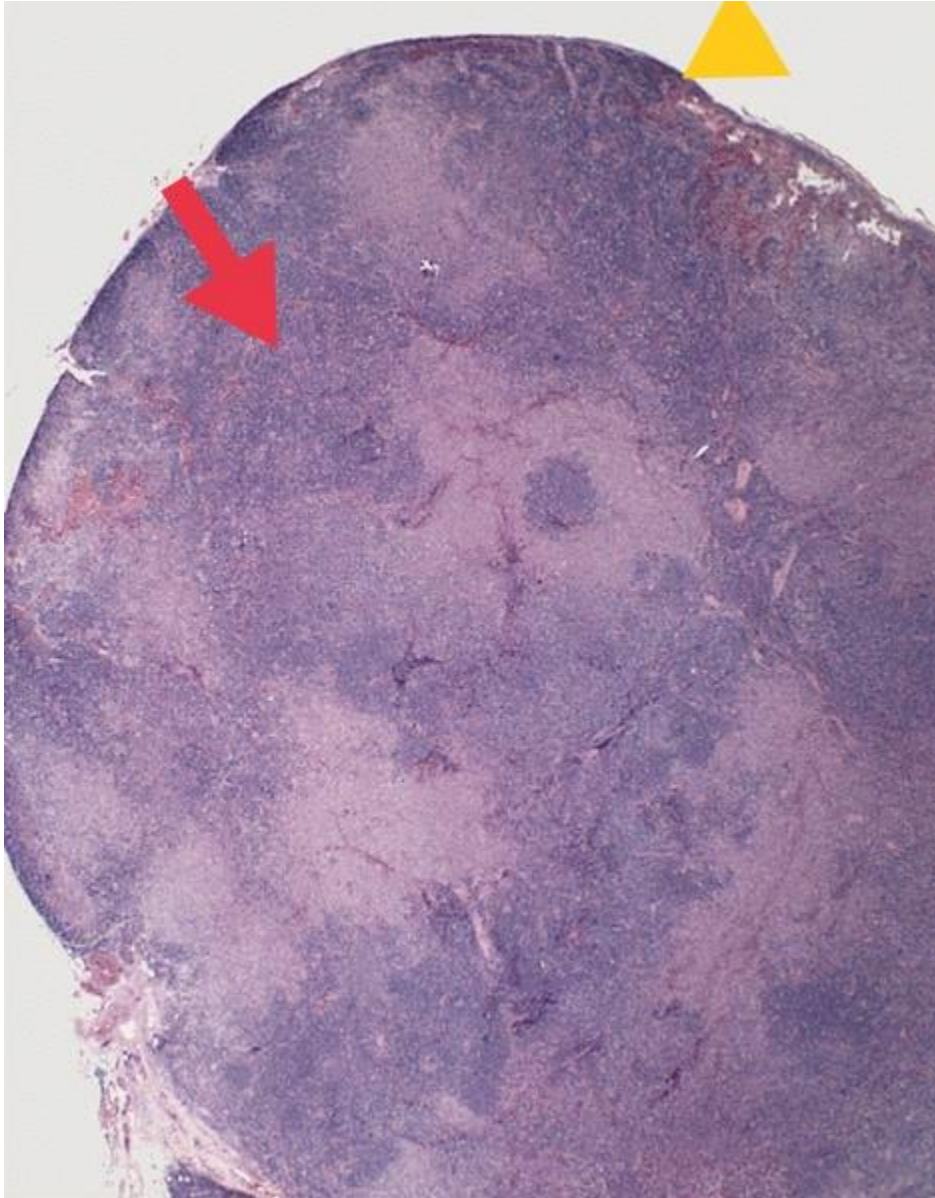


Fig. 1 shows fibrous capsule and beneath lymphnode architecture maintained and hyperplastic follicles and dilated sinuses. (H & E 5x X 10x)



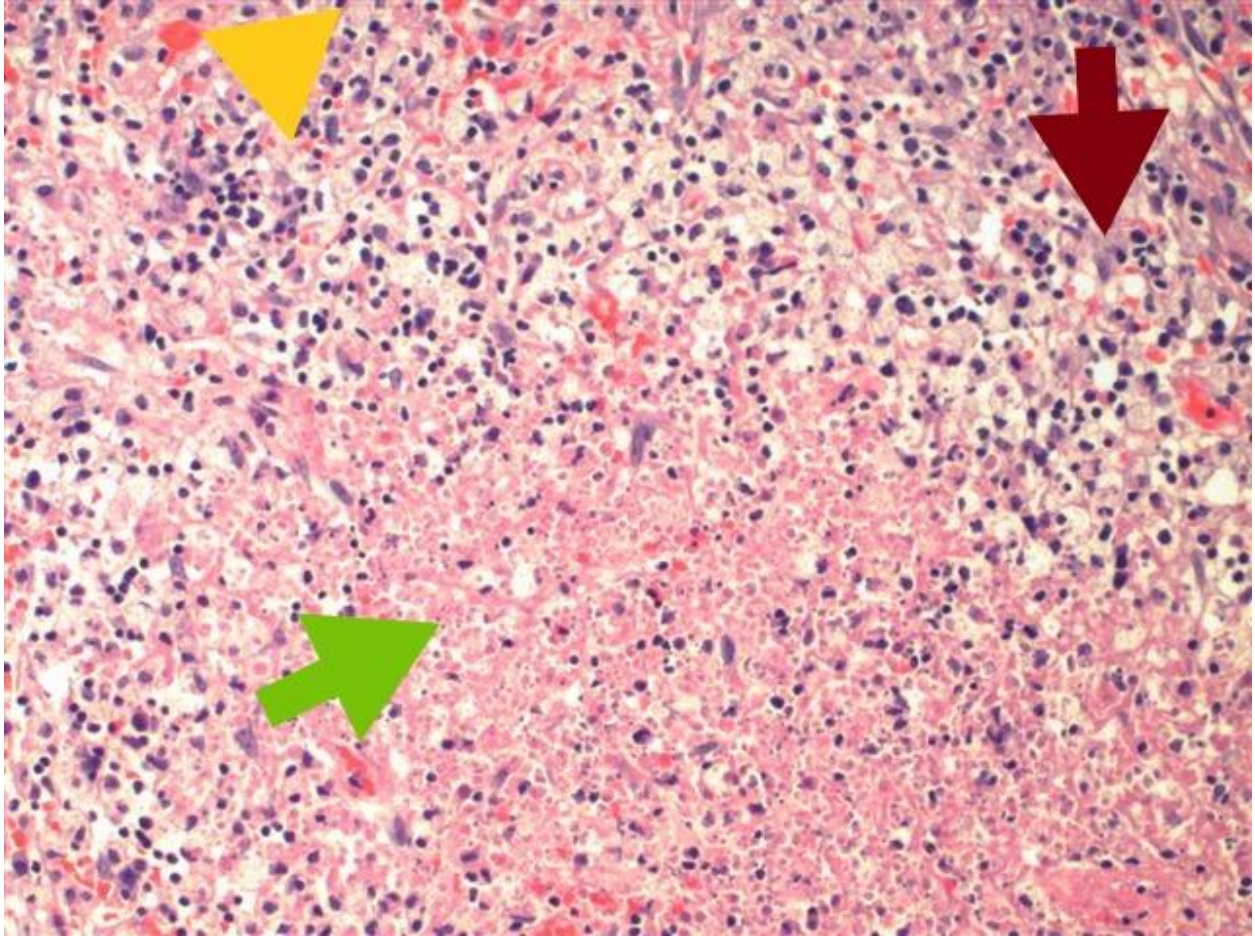


Fig. 2 shows areas of necrosis surrounded by inflammatory cells. ( H & E 10x X 40x)

UNDER