

Case report

Title: Gastro-Tracheal Fistula: A rare late complication following Laryngo-Pharyngo-Esophagectomy

Abstract:

Idiopathic fistula between the Gastric tube and the trachea after Laryngopharyngoesophagectomy (LPO) for Carcinoma post cricoid has not been reported in the literature so far. This is the first time we report one such case and its successful repair using Pectoralis Major Muscle Flap (PMMF) and Delto-Pectoral Flap (DPF). The surgical procedure is explained in detail and the various management strategies were discussed.

Keywords: Tracheogastric fistula, carcinoma hypopharynx, Dual flap, PMMC flap, DP flap

Introduction:

Gastro-tracheal fistula (GTF), a rare complication, is described as fistula between trachea and transposed gastric tube post laryngopharyngoesophagectomy or a esophagectomy. Gastro-Tracheal Fistula (GTF) as a rare complication after surgery for Carcinoma Esophagus is reported.¹ The management is complex than usually mentioned, with an author describing the unsuccessful attempts to repair.² We report a case treated at Cancer Research and Relief Trust (a tertiary Care Centre) for GTF occurring 2 years following treatment for Postcricoid Carcinoma. Surgical intervention and successful fistula repair using Pectoralis Major Muscle Flap (PMM flap) and Delto-pectoral flap (DP flap) is described.

Case Report:

A 58 year old gentleman presented to the outpatient clinic with complaints of recent onset severe cough and fever. He was treated for Carcinoma of Post cricoid, stage cT3 N0 M0, 2 years back. He underwent Laryngopharyngoesophagectomy, bilateral selective neck dissection, Gastric transposition. Post operative histopathology revealed Squamous cell carcinoma Grade II, Margins Free, Lymph nodes negative for metastatic carcinoma, pT3 pN0. The surgery was followed by adjuvant radiotherapy in view of the pathologically stage III disease. His speech was rehabilitated by electrolarynx. Clinical examination of the trachostoma revealed salivary leak from the membranous tracheal wall and erythematous tracheal mucosa. Provisional diagnosis of GTF was made. Barium swallow (Figure 1) shows evidence of aspiration. The patient was started on broad-spectrum antibiotics to manage aspiration pneumonitis. Ryle's tube was inserted to bypass the fistulous site, and feeding started. PET-CT was performed to rule-out recurrence. Bronchoscopy and esophagogastrosocopy (Figure 2, 3) confirmed the presence of 1x1cm gastro-tracheal fistula, 2cm caudal to the tracheostoma. Endoscopic biopsy from fistulous tract was taken, which was negative for malignancy. Initially managed conservatively, later became evident that it is less likely to heal without surgical management.

After taking informed consent, he was planned for surgery; the fistula was approached via cervical incision along the previous scar. Trachea was separated from the stomach tube and fistula was exposed. The ensuing gastrostomy was closed in two layers with 3-0 vicryl (polyglactin 910). Pectoralis major muscle flap was harvested, via a horizontal incision over the anterior chest wall without violating the delto-pectoral skin territory. The muscle flap was brought into the neck after tunnelling. The length of the muscle flap was inadequate to reach the mediastinal fistula; hence the medial aspect of the clavicle was resected to facilitate the reach. The gastric closure was covered with the vascularised muscle flap, in view of the prior radiotherapy. The opening in the membranous wall of trachea was exteriorised, to widen the stoma. DP Flap was used to reconstruct the membranous wall. Portex tracheostomy tube was maintained in position for 3 weeks to avoid collapse of stoma. The post operative course was uneventful; patient was started on complete oral diet after the 3rd post operative week.

Discussion:

The GTF is a potentially lethal complication which requires prompt recognition and swift closure. Common cause of Gastro-Tracheal fistula in oncology setting is recurrence of disease, which has to be ruled out. PET CT is the investigation of choice for diagnosing recurrence, due to its high negative predictive value close to 95%.³ We describe a rare case of idiopathic Gastro tracheal fistula in a patient, who was treated for Carcinoma postcricoid and its unique way of management following the traditional surgical principles.

In the current era, GTF induced by the cuff of endotracheal or tracheostomy tubes are obsolete, because of the availability of low pressure cuffs. It was described that a chronic inflammatory process, such as gastritis or tracheitis can be attributed to the development of fistula,⁴ which was not the finding in our case. External beam radiotherapy (EBRT) leads to localized fibrosis and decreased microvascular circulation both in the trachea as well as in the gastric tube which may affect the vascularity, leading to necrosis and fistula formation. As the GTF in the present case, occurred within the field of radiation, the possibility of GTF as a late complication of EBRT can be thought.

There is one reported case with late benign gastro tracheal fistula, following treatment for hypopharyngeal cancers.⁴ Interestingly the author concluded that the fistula was a result of existing tracheitis and a over judicious biopsy performed in the irradiated field, which was not the case in the present paper.

The principles of closure of fistula are well described in the literature.⁵ The closure of gastro tracheal fistula in post radiotherapy setting is complication by reduced vascularity and extensive fibrosis. The optimization of patient general condition and nutrition should be the first goal before planning a major surgical intervention.

A variety of methods were illustrated by different authors for the management of Gastro tracheal fistula, these include less invasive covered self-expanding metallic stents along with fibrin glue, cardiac septal occluder devices,⁶⁻⁹ which are least suitable in post radiation field. Successfully used Invasive methods like pedicled pericardial flap, Pedicled Jejunum, Intercostal muscle flap interposition,

Combination of pericardial patch-intercostal muscle-colon conduit, combination of Bovine Pericardial patch – Deepithelized PMMC flap were described.^{5,10-13}

Our method of closure was different and comparatively less invasive than the above described procedures, where either the thoracic or/ abdominal cavities were not entered. We used the traditional PMM flap and DP flap, because the fistula was high in the mediastinum that was amenable to approach from neck.

Conclusion:

The occurrence of idiopathic GTF, 2yrs post treatment for post cricoid carcinoma is very rare. The primary objective is to rule out a possible recurrence and if deemed idiopathic then every attempt should be made to repair the fistula, as the continuous leakage of gastric fluids leads to high mortality. We described the successful management of the GTF with dual regional flaps.

Disclaimer regarding Consent and Ethical Approval:

As per university standard guideline, participant consent and ethical approval have been collected and preserved by the authors

References:

1. Kalmar K, Molnar TF HO. Two cases of benign tracheo-gastric fistula following esophagectomy for cancer. *Acta Chir Hung*. 1999;38:261–7.
2. Salah H, Tahamtan M, Ziaian B, Masjedi M, Saadati Z, Hoseini N TE. Gastrotracheal Fistula as a Result of Transhiatal Esophagectomy for Esophageal Cancer: An Unusual Complication. *Case Rep Surg*. 2015;2015.
3. Isles MG, McConkey C MH. A systematic review and meta-analysis of the role of positron emission tomography in the follow up of head and neck squamous cell carcinoma following radiotherapy or chemoradiotherapy. *Clin Otolaryngol*. 2008;33:210–22.
4. Zitsch RP 3rd, Vallery SW DL. Benign tracheogastric fistula: a late complication of pharyngogastric anastomosis. *Head Neck*. 1994;16:186–90.
5. Muniappan A, Wain JC, Wright CD, Donahue DM, Gaissert H, Lanuti M MD. Surgical treatment of nonmalignant tracheoesophageal fistula: a thirty-five year experience. *Ann Thorac Surg*. 2013;95(4):1141–6.
6. Lee HJ, Jung ES, Park MS, Chung HS, Choi JY, Lee KJ, Lee JS, Kil HK LY. Closure of a gastrotracheal fistula using a cardiac septal occluder device. *Endoscopy*. 2011;43:E53-4.
7. Fayoumi S SS. Closure of tracheogastric fistula by video-assisted tracheoscopy, direct repair, and self-expandable titanium stent in a patient with total laryngopharyngoesophagectomy. *J Thorac Cardiovasc Surg*. 2007;133:1103–4.
8. Bona D, Sarli D, Saino G, Quarenghi M BL. Successful conservative management of benign gastro-bronchial fistula after intrathoracic esophagogastrotomy. *Ann Thorac Surg*. 2007;84(3):1036–8.

9. Repici A, Presbitero P, Carlino A, Strangio G, Rando G, Pagano N, Romeo F RR. First human case of esophagus-tracheal fistula closure by using a cardiac septal occluder (with video). *Gastrointest Endosc.* 2010;71(4):867–9.
10. Francesco Paolo Caronia, Alfonso Fiorelli, Mario Santini, Roberto Alfano SC. A new technique to repair huge tracheo-gastric fistula following esophagectomy. *Ann Transl Med.* 2016;4:403.
11. Nardella JE, Van Raemdonck D, Piessevaux H, Deprez P, Droissart R, Staudt JP, Heuker D van VE. Gastro-tracheal fistula--unusual and life threatening complication after esophagectomy for cancer: a case report. *J Cardiothorac Surg.* 2009;29:69.
12. Ibuki Y, Hamai Y, Hihara J, Taomoto J, Kishimoto I, Miyata Y OM. Emergency escape surgery for a gastro-bronchial fistula with respiratory failure that developed after esophagectomy. *Surg Today.* 2015;45:369–73.
13. Yasuda T, Sugimura K, Yamasaki M, Miyata H, Motoori M, Yano M, Shiozaki H, Mori M DY. Ten cases of gastro-tracheobronchial fistula: a serious complication after esophagectomy and reconstruction using posterior mediastinal gastric tube. *Dis Esophagus.* 2012;25(8):687–693.

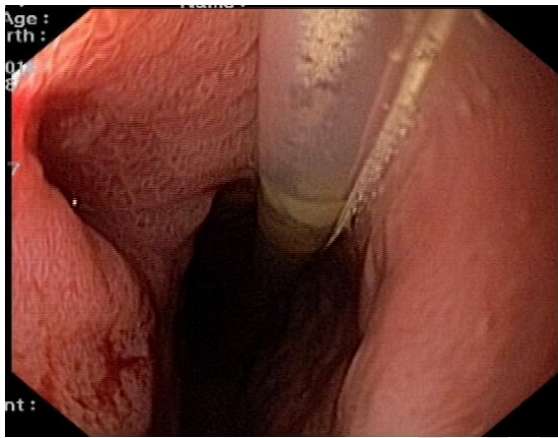
Figure 1: Barium swallow showing the fistulous tract and barium enhanced tracheo broncheal tree

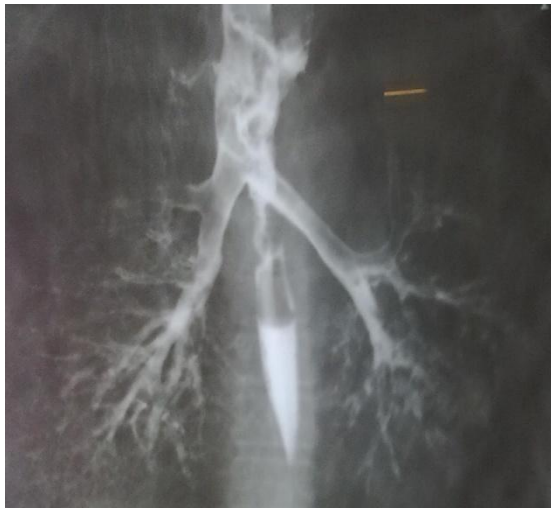

Figure 2: Bronchoscopy with fistula over the membranous portion

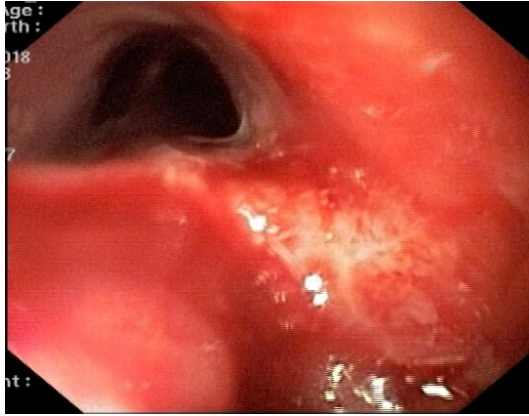

Figure 3: Esophagoscopy image with fistula in the gastric tube



UNDER PEER REVIEW