

Comment [I1]: Better to write the article as case report since it is not review article

A REVIEW on PLACENTAL TUBERCULOSIS

Abstract

Tuberculosis has re-emerged as a serious health concern as a result of AIDS epidemic, immigration from areas where the disease is endemic and multi drug resistance, with 8.8 million patients affected worldwide in 2010. Infections with mycobacterium tuberculosis (MTb) are globally prevalent in many countries, yet descriptions of placental pathology in tuberculous patients are few. Moreover, the diagnosis of tuberculosis in pregnant patients can be missed or delayed owing to the insidious onset and variability of clinical presentation, often overlapping with non-specific symptoms common in pregnancy such as loss of appetite, malaise and lethargy. The exact incidence of tuberculosis in pregnancy is not readily available in many countries due to confounding factors. However, it is expected that the incidence of tuberculosis in pregnant women is high as in general population, with higher incidence in developing countries. Placental tuberculosis shows predominantly neutrophilic and histiocytic response in the form of villitis and intervillitis which is due to the innate immune response. This innate response contributes more to tissue injury than protection as proved in our case, where it led to intrauterine death of the fetus. We, hereby report a case of placental tuberculosis, diagnosed on histopathological examination of placenta showing caseating epithelioid cell granulomas with Langhans' giant cells and Acid Fast Bacilli on Ziehl-Neelsen stain.

Comment [I2]: No abbreviation in the abstract

Comment [I3]: Old incidence

Comment [I4]: So its case report rather than review article

Keywords

Tuberculosis, Placental, Congenital, Epithelioid cell granulomas, Acid fast bacilli

INTRODUCTION

Tuberculosis (TB) is believed to be nearly as old as human history. About one third of the world's population (estimated to be about 1.75 billion) is infected with the tubercle bacillus [1]. As much as 75% of individuals with TB are within the economically productive age group of 15 to 54 years. This significantly impairs socioeconomic development, perpetuating the poverty cycle [2]. Infections with mycobacterium tuberculosis (MTb) are globally prevalent in many countries, yet descriptions of placental pathology in tuberculous patients are few. The delay in clinical onset of disease and diagnosis, specifically in the newborn and often in the mother, are the most likely explanations for the scanty reports of placental pathology in congenital tuberculosis. Also, placentas are usually discarded by the time diagnosis is finally considered several weeks postpartum. Moreover, the diagnosis of tuberculosis in pregnant patients can be missed or delayed owing to the insidious onset and variability of clinical presentation, often

overlapping with non-specific symptoms common in pregnancy such as loss of appetite, malaise and lethargy. Other factors contributing to underdiagnosis include: a reluctance to perform radiographic studies in patients to avoid fetal exposure to radiation, the technical difficulty of accessing **lesional** tissue for diagnosis, and both infrequent and inadequate placental examination [3, 4, 5, 6]. In a span of ten years of histopathological practice at a tertiary care hospital in Kanpur, India, we came across only one case of placental tuberculosis.

Comment [15]: lesion

Comment [16]: [3-6]

A 28 year female patient came for regular follow up in antenatal **OPD** and was advised routine ultrasound scan at 12th week gestation. The scan showed **IUD** and then the patient was taken up for D&C. The patient was asymptomatic with no history of any weight loss, loss of appetite or evening rise in temperature. Her **vitals** were stable. We received multiple bits of grayish white, soft placental tissue which on histopathological examination revealed chorionic villi showing Granulomatous villitis, foci of caseous necrosis, Langhans' giant cells, acute villitis and intervillitis. (Figure 1&2) ZN stain was positive for acid fast bacilli, confirming the diagnosis of placental tuberculosis.

Comment [17]: No abbreviations

Comment [18]: Missed miscarriage

Comment [19]: Vital signs

DISCUSSION

Tuberculosis has re-emerged as a serious health concern as a result of AIDS epidemic, immigration from areas where the disease is endemic and multi drug resistant [3, 7, 8], with 8.8 million patients affected worldwide in 2010. Over the past three decades the most common age group affected has changed from over 50 years to a median age of less than 30 years, resulting in an increased proportion of tuberculosis in women of child bearing age and maternal mortality [3,5]. However, despite the increase in incidence of TB, congenital TB remains an uncommon diagnosis. It is a rare disease with a high mortality rate, requiring high index of suspicion to diagnose because of non specific presentation. The exact incidence of tuberculosis in pregnancy is not readily available in many countries due to confounding factors. However, it is expected that the incidence of tuberculosis in pregnant women is high as in general population, with higher incidence in developing countries.

Comment [110]: Repeated sentences in the abstract

Current literature on the prevalence of TB among pregnant women in developing countries like India is not available. Considering the current incidence of TB among women of reproductive age (around 100 cases/100,000 population) and a total of 26 million births annually, our estimates suggest that approx. 20,000-40,000 women in India are likely to have active TB during pregnancy each year [9,10]. Therefore, not only is there a knowledge gap, but also the true impact of the problem is not known.

Tuberculosis in pregnancy is a double edged sword, one blade being the effect of tuberculosis on pregnancy while the other being effect of pregnancy on the progression of tuberculosis. In the beginning of 14th century, it was believed that pulmonary cavities from tuberculosis collapse as a result of increased intra-abdominal pressure due to pregnancy leading to a recommendation that young women with TB should get married and become pregnant to slow the progression of the

disease. This was practiced in many areas till the 19th century!! [11], while in the early 20th century, induced abortion was recommended for these women [12].

Several descriptive studies, both old and new have underestimated the maternal and perinatal complications of TB [7,13,14]. Also, there is a sense of complacency among obstetricians regarding the benign course of both disease and pregnancy among women suffering from TB. However, few reports from diverse countries have tempered this false notion and suggested the potential harmful effects of TB on mother, fetus and newborn [13,14].

TB has multiple implications on maternal, fetal and new born health. According to the past studies, TB is associated with major/minor maternal/obstetric problems. [15] High grade fever and maternal debility could lead to antenatal hospital admission and preterm delivery, however, these women respond well to anti-TB treatment. Extrapulmonary tuberculosis in pregnancy can lead to serious morbidity; PUO, back pain, early onset paraplegia, spinal deformity and difficult spinal anesthesia. [15,16]

Comment [I11]: No abbreviations

Maternal TB is potentially for the fetus and newborn. There is higher risk for low birth weight and small for gestational age babies in tuberculous mothers. [7,15] The perinatal effects are more pronounced in cases with late diagnosis, incomplete or irregular drug treatment, and in those with advanced pulmonary lesions. [17] A prospective observational study over a period of 10 years (1991-2000) from Mumbai, western India, included 153 pregnant women with TB. This study revealed that maternal TB is associated with a high incidence of LBW neonates, which was primarily attributed to fetal growth restriction. Although there was some improvement of perinatal outcomes in the latter half of the study, the problems of LBW and late fetal death remained undebated [18].

TB in the neonate can be either congenital (i.e., acquired in utero) or neonatal (i.e., acquired early in life from the mother or other persons). Sources of fetal infection can be hematogenous spread through placenta or by aspiration/ingestion of infected amniotic fluid. Hematogenous spread leads to formation of a primary complex in the liver or caseating hepatic granulomas, whereas aspiration or ingestion of infected amniotic fluid results in primary complex in lungs or gastrointestinal tract, respectively [19,20].

Comment [I12]: Delete this sentences

Congenital tuberculosis is extremely rare condition, with less than 400 cases reported in the literature published in 2002 [21]. Many cases of perinatal TB seem to be associated with a concomitant acute or new infection in the mother which is required for hematogenous transplacental transmission to the fetus. Chronic TB in the mother is less likely to cause infection in the fetus as in them hematogenous spread is less possible due to variable fibrosis and low levels of mycobacteria in the tissue, blood and genital secretions. Also chronic TB leads to infertility in females; with low pregnancy changes [20,21].

Diagnostic criteria for congenital tuberculosis were laid down by Beitzki in 1935 and subsequently by Cantwell in 1994. Singh et al in 2007 suggested laboratory and clinical findings

that may suggest congenital TB, which include a newborn from a TB endemic area with unresponsive worsening pneumonia, a mother with TB or a baby with fever and hepatosplenomegaly [22].

In published reports, a minority of women were diagnosed with TB during the third trimester of pregnancy. Most women became symptomatic postnatally with active pulmonary disease, prompting newborn evaluation. Few reports had postnatally asymptomatic mothers while infants had active disease [23].

Our case reflects a case of fetal TB in which the mother was apparently healthy, without family history of TB or other infection problems. Indeed it was fetal IUD in early pregnancy that led to the diagnosis of TB in fetus through placental histopathology and subsequently TB was also diagnosed in the mother.

Comment [113]: Missed miscarriage

Placental tubercular lesions are rare. Tubercular placentitis could potentially arise by the direct extension from the endometrial lesions; however, this pathogenesis is unlikely since tuberculous endometritis is usually associated with tubal disease and infertility. Hematogenous dissemination is more probable [24]. Warthin et al classified placental tuberculosis as (1) Decidual; (2) Intervillous; (3) Intravillous; (4) Intravascular chorionic; (5) Chorio-amniotic. He also stated that decidual lesion is practically always primarily a vascular one, the endothelium being first involved [25]. As seen with other transplacental infections, in tuberculosis, acute or chronic villitis, often accompanied by intervillitis, is the hallmark lesion. Most commonly, mycobacteria localize in the intervillous space following hematogenous spread from the mother, resulting in villitis and intervillitis. While granulomatous inflammation is to be expected and has been reported [26,27] in cases of congenital tuberculosis, an acute villitis and intervillitis is seen. The usual necrotizing granulomatous response associated with tuberculous infections require an activation of the adaptive immune system, however, before this system is turned on, the first encounter with the tubercle bacillus is mediated by the innate immune system. This pathway utilizes innate surface granulomatous pattern of inflammation. Acute abscess-like inflammatory response with neutrophils and histiocytes causing acute villitis and intervillitis is seen. This may be one of the reasons that so few cases of congenital tuberculosis involving placenta have been reported [4,27]. Another reason may be that with an acute type of inflammatory reactions, tuberculosis may not be considered in the differential. Our case also showed prominent villitis and intervillitis with only focal caseating granulomatous reaction. But since, the section was positive for acid fast bacilli on Ziehl Neilsen stain, a confirmatory diagnosis of placental tuberculosis was made.

CONCLUSION

Maternal tuberculosis remains unrecognized and underestimated tragedy with pervasive undernutrition compounded with overcrowding and inequity in health care services. In antenatal intrauterine deaths it is worthwhile to thoroughly examine the placentas for tuberculosis as

involvement may lead to accurate diagnosis or indicate disseminated disease. Placental tuberculosis shows predominantly neutrophilic and histiocytic response in the form of villitis and intervillitis which is due to the innate immune response. This innate response contributes more to tissue injury than protection as proved in our case, where it led to intrauterine death of fetus. Therefore it is very important for thorough antenatal checkup to rule out maternal tuberculosis. Perinatal tuberculosis is biggest hurdle in management to tuberculosis during pregnancy. To conclude advocacy, communication and social mobilization are vital issues to bridge pre-existing gaps between the health system and the community by enhancing knowledge, attitude and practice related to tuberculosis, especially in pregnant women.

REFERENCES

1. "Global tuberculosis control: a short update to the 2009 report." Tech. Rep., World Health Organization, Geneva, Switzerland, (WHO/HTM/TB/2009.426), 2009.
2. "Global tuberculosis control 2010," Tech. Rep., World Health Organization, Geneva, Switzerland, (WHO/HTM/TB/2010.), 2010.
3. Whittaker E, Kampmann B. Perinatal Tuberculosis: new challenges in the diagnosis and treatment of tuberculosis in infants and newborn. *Early Hum Dev.* 2008 Dec; 84(12):795-9.
4. Benirschke K, Kaufmann P, Baergen R. Infectious diseases. In: Benirschke K, Kaufmann P, Baergen R, eds. *Pathology of Human Placenta*. 5thed. New York: Springer, 2006.p.683.
5. Ormerod P. Tuberculosis in pregnancy and puerperium. *Thorax* 2001;56:494-99.
6. Asquo B, Vellore AD, Walters G, Manney S, Mignini L, Kunst H. A case control study of the risk of adverse perinatal outcomes due to tuberculosis during pregnancy. *J ObstetGynaecol* 2012; 32:635-8.
7. Jana N, Barik S, Arora N, Singh AK. Tuberculosis in pregnancy: the challenges for South Asian countries. *J ObstetGynaecol Res* 2012;38:1125-36.
8. Loto OM, Awowole I. Tuberculosis in pregnancy: a review. *J Pregnancy* 2012;2012:379271.
9. WHO. Tuberculosis in the South-East Asia Region. The Regional Report: 2010. New Delhi: WHO Regional Office for South-East Asia, 2010.
10. UNICEF. India statistics. Available from URL: http://www.unicef.org/infobycountry/india_statistics.html.
11. D. Snider Jr. Pregnancy and tuberculosis. *Chest* 1984;86(3).
12. JG Vallejo, JR Starke. Tuberculosis and pregnancy. *Clinics in Chest Medicine* 1992;13(4):693-707.
13. Jana N, Arora N, Barik S. Tuberculosis in pregnancy in the UK. *BJOG* 2009;116:1542-3.
14. Lin H-C, Lin H-C, Chen S-F. Increased risk of low birth-weight and small for gestational age infants among women with tuberculosis. *BJOG* 2010;117:585-90.

15. Tripathy SN, Tripathy SN. Tuberculosis and pregnancy. *Int J GynaecolObstet* 2003;80:247-53.
16. Jana N, Vasishta K, Saha SC, Ghosh K. Obstetrical outcome among women with extrapulmonary tuberculosis. *N Engl J Med* 1999;341:645-9.
17. Jana N, Vasishta K, Jindal SK, Khunnu B, Ghosh K. Perinatal outcome in pregnancies complicated by pulmonary tuberculosis. *Int J GynecolObstet* 1994;44:494-9.
18. Khadilkar SS, Saraiya U. Tuberculosis and pregnancy: A ten year overview. *J ObstetGynaecol India* 2003;53:453-7.
19. Jana N, Ghosh K, Sinha S, Gopalan S, Vasishta K. The perinatal aspects of pulmonary tuberculosis. *FetalMaten. Med Rev* 1996;8:229-38.
20. Cantwell MF, Shehab ZM, Costello AM, et al. Brief Report: Congenital tuberculosis. *N Engl J Med* 1994;330:1051-4.
21. Smith KC. Congenital tuberculosis: a rare manifestation of a common infection. *Curr Opin Infect Dis* 2002;15:269-74.
22. Tewari L, Kumar R. Congenital tuberculosis with possible placental transmission and paradoxical reaction to anti-tuberculosis treatment. *Lung Breath J* 2017DOI: 10.15761/LBJ.1000111.
23. Mony VK, Polin J, Adler E, Munjal I, LaTuga MS, Kojaoghlanian T. Congenital tuberculosis: A missed opportunity. *J PediaInfec Dis Soc* 2014;3(4):e45-7.
24. Kaplan C, Benirschke K, Tarzy B. Placental tuberculosis in early and late pregnancy. *Am J Obstet Gynecol.* 1980 Aug 1;137(7):858-60.
25. Warthin, A.S.: Tuberculosis of the placenta. *J. Infect. Dis.* 4:347,1907
26. Cantwell MF, Shehab ZM, Costello AM, Sands L, Green WF, Ewing Jr EP, et al. Congenital tuberculosis. *N Engl J Med.* 1994;330:1051-4.
27. Abramowsky CR, Gutman J, HilinskiJA . Mycobacterium tuberculosis Infection of the Placenta: A study of the Early (Innate) Inflammatory Response in Two Cases. *PediatrDevPathol.* 2012 Mar-Apr;15(2):132-136

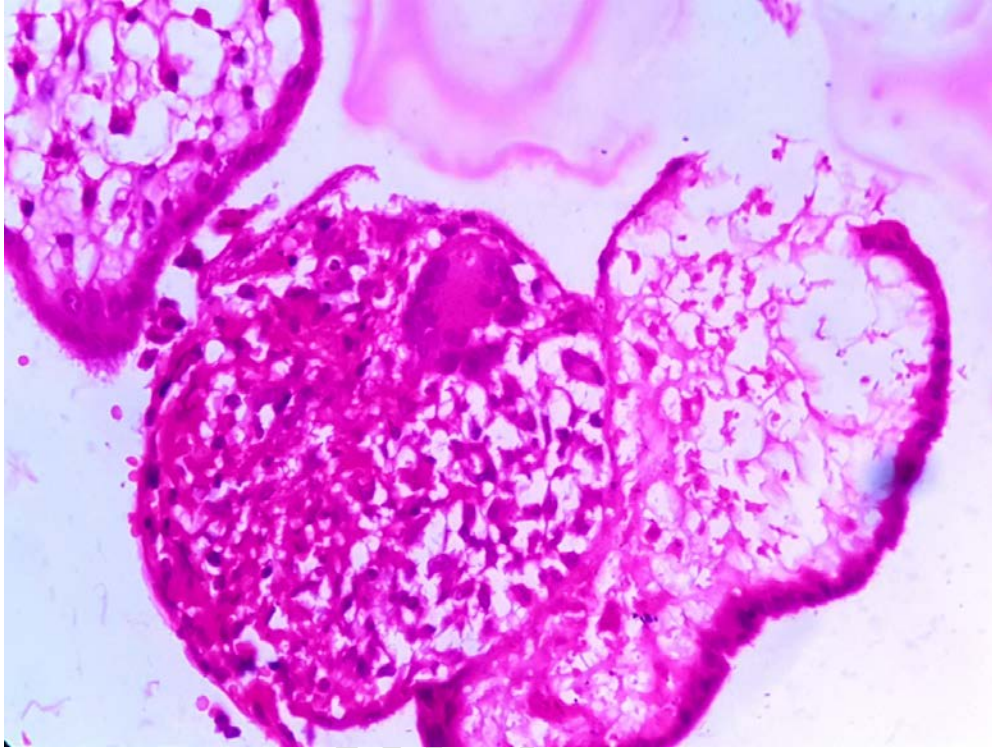


Fig. 1. Placental tubercular lesions 1

UNDER PE

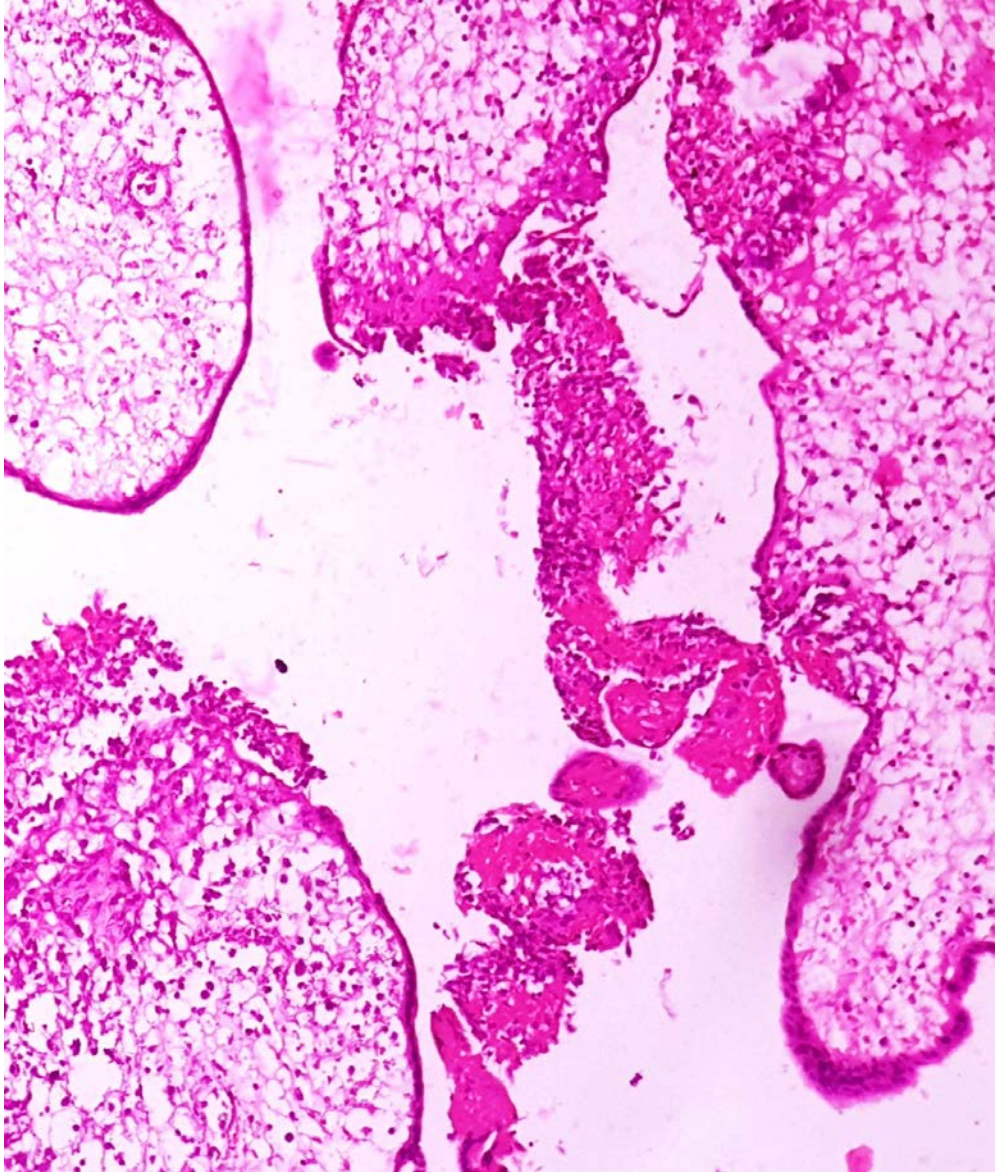


Fig. 2. Placental tubercular lesions 2