

Bilateral Transolecranon fracture dislocation elbow with bilateral coronoid and radial head fractures – a rare complex elbow injury. A case report and review of literature.

Abstract

Bilateral olecranon fractures are a rare occurrence. Direct trauma usually results in comminuted fractures and indirect trauma in transverse fractures. We describe a case of bilateral olecranon fracture with radial head comminuted fracture with coronoid fracture without involvement of collaterals. Olecranon fractures are usually a result of direct trauma (fall from height / motor vehicle accidents) or indirect trauma. A 22year old male patient presented to the emergency department with complaints of pain and swelling around both elbows following a motor vehicle accident. Patient also sustained trauma to the head and had a history of transient loss of consciousness. CT brain at the time of presentation was normal and patient was conscious. The Olecranon Fracture was fixed with a pre contoured olecranon locking compression plate (Synthes, USA). In our case, the collaterals were intact and as the radial head was comminuted, we excised the radial head. The radial head being secondary stabilizer of the elbow in injuries to the medial collateral ligament complex. Excision of radial head would not cause any instability. Bilateral olecranon fractures need to be fixed anatomically, the comminuted radial head was excised and anterior capsule was repaired.

Keywords: Bilateral Transolecranon, Olecranon Fracture, trauma, collateral ligament complex

Introduction

The incidence of Olecranon Fractures has been reported to be approximately 10% of traumatic fractures of the upper limb (1). Olecranon fractures are usually a result of direct trauma (fall from height / motor vehicle accidents) or indirect trauma (2). These injuries are usually unilateral, and bilateral injuries are very rare. A review of literature showed five case reports of bilateral traumatic olecranon fractures and two reports of spontaneous bilateral olecranon fractures in patients of rheumatoid arthritis and sarcoidosis (2-9). Of the five papers describing cases of traumatic aetiology, one author reported an associated radio-humeral dislocation (7).

We would like to report a case of a complex elbow injury -Bilateral Transolecranon fracture dislocation elbow with bilateral coronoid and radial head fractures. We were unable ... to find such injuries being reported in the English literature. We describe the management of such a complex injury and review the literature....

Case Report

A 22-year-old male patient presented to the emergency department with complaints of pain and swelling around both elbows following a motor vehicle accident. This happened when the motor bike hit a truck from behind. Patient also sustained trauma to the head and had a history of transient loss of consciousness. CT brain at the time of presentation was normal and patient was conscious. A neurosurgery consult was sought.

Physical examination revealed swelling, tenderness and deformity of both elbows. There were no distal neurovascular deficits. The ipsilateral wrist and shoulder was clinically normal. Plain radiographs of both elbows revealed Bilateral Olecranon Fracture with radial head fracture dislocation (fig 1&2). CT scan of both elbows was done following this, which showed olecranon fracture with comminuted fracture of radial head and coronoid fracture bilaterally. (Fig 3&4)

Patient was prepared for surgery. Under general anesthesia, patient was placed in a right lateral position and the left olecranon fracture was exposed by a posterior midline incision. The radial head was found to be comminuted, dislocated posteriorly and not reconstructible, and hence a decision for radial head excision was made intra-operatively. The Olecranon Fracture was fixed with a pre-contoured olecranon locking compression plate (Synthes, USA). The elbow was found to be stable at about 100 degree of flexion. There was no varus or valgus instability. The collaterals were normal. The anterior capsule was repaired but coronoid was not fixed.

Patient was switched to the left lateral position and the same technique was used to the right olecranon fracture fixation. The right side radial head was comminuted, dislocated posteriorly and was not reconstructible, and hence a decision for radial head excision was made intra-operatively. The Olecranon Fracture was fixed with a pre-contoured olecranon locking compression plate (Synthes, Usa). The elbow was found to be stable at about 100 degree of flexion. There was no varus or valgus instability. The collaterals were found normal. The anterior capsule was repaired but coronoid was not fixed.

Postoperative plain radiographs demonstrated adequate fixation of the olecranon with concentric reduction of ulna humeral joint bilaterally (fig5 &6). Both elbows were splinted in flexion of 100 degrees for a period of 3 weeks and then range of motion exercises (passive and active-assisted) were initiated. Patient had full range of flexion-extension and supination-pronation at the end of 16 weeks from the surgery.

Discussion

Bilateral olecranon fractures are a rare occurrence. **Newman et al** al. noted that direct trauma usually results in comminuted fractures and indirect trauma in transverse fractures. We describe

a case of bilateral olecranon fracture with radial head comminuted fracture with coronoid fracture without involvement of collaterals.

Elbow fractures with ulnohumeral instability tend to occur in general patterns: (1) **terrible triad**, (2) varus posteromedial rotatory instability (VPMRI), (3) olecranon fracture dislocation (OFD), (4) radial head fracture with ulnohumeral dislocation, and (5) lateral column fracture of the distal humerus with ulnohumeral dislocation.

Our case did not fall into any of the above categories, as there was trans olecranon fracture with coronoid fracture with comminuted radial head fracture, dislocation of the elbow with intact collaterals. The comminuted radial head fragments were found dislocated posteriorly on both sides. And due to bilateral nature of the injury there was no particular treatment protocol we could follow. However achieving ulnohumeral stability and good function in both the elbow was crucial in this case. We went on with bone stabilization first in this case. The coronoid fracture was not operatively fixed but the anterior capsule was repaired after the radial head was excised.

In our case, the collaterals were intact and as the radial head was comminuted, we excised the radial head. The radial head being secondary stabilizer of the elbow in injuries to the medial collateral ligament complex (was intact in our case). Excision of radial head would not cause any instability.

As all olecranon fractures are intra articular (10), the goal of the treatment is to achieve anatomical reduction of the articular surface, complete range of motion without extensor lag and a stable elbow (1). Non-operative management of these fractures are reserved for undisplaced fractures and patients who are not fit for surgical intervention (10). The operative treatment options available are – tension band fixation, intramedullary pinning and plate fixation (10). Comminuted fractures of the olecranon are not amenable to tension band fixation (1) and hence option of plate fixation was used. Hardware prominence is the most common complaint after plate fixation. Aroutine removal of plate may be considered in these patients.

An axial loading injury such as one in our case causes trans-olecranon fracture-dislocations. These injuries typically have disruption of the ulnohumeral joint and the radial head gets displaced anteriorly. The proximal ulna has a complex, comminuted fracture. However the ulna fracture could be simple or oblique also. **The fractures of coronoid are common in these injuries and typically involve more than 50% of the height of the coronoid.** Concomitant radial head fractures are common, however the collaterals are spared. [11,12,13,14,15].

These TOFD injuries need to be differentiated from the Monteggia injuries. The Monteggia injuries involve dislocation of PRUJ (proximal radio ulnar joint). The aim of management of

TOFD is to restore the greater sigmoid notch. The focus of treatment of Monteggia type of injuries is anatomical reduction of ulnar diaphyseal fracture.

The option for radial head fracture with dislocation is prosthetic replacement, fixation, or surgical excision. The fixation was not an option in our case as it was comminuted. We did not opt for prosthetic radial head replacement, as the results of prosthetic radial head replacement are fraught with early loosening of the prosthesis. The proximal migration of the radius after radial head excision could be a problem causing pain in the distal radio ulnar joint area. We did not see any such issue in our patient.

The peri-operative considerations in a patient of bilateral elbow trauma requiring operative fixation was to avoid bilateral brachial plexus block and positioning of the patient during surgery. We positioned the patient in lateral position, which helps in good exposure and fixation and assessment of range of movements and stability of elbow. The other authors preferred supine position. We used celecoxib for a period of 4 weeks to prevent heterotopic ossification (16-17). Our patient achieved full range of motion and a stable joint. No additional procedure was required for ligament reconstruction.

At the recent follow up fractures were completely healed with stable elbow and patient had flexion of 95 degrees with terminal 10 degree extension block. He did not have any functional restrictions in all his day to day activities.

Conclusion

Bilateral Transolecranon fracture dislocation elbow with Bilateral coronoid and radial head fractures is a complex elbow injury. This type of a rare injury doesn't fall into any of the types of complex fracture dislocations of the elbow. There is no set protocol for managing these types of injuries. The bilateral nature of this injury not only makes it challenging to treat but getting a good functional outcome is important in this type of patient. Bilateral olecranon fractures need to be fixed anatomically, the comminuted radial head was excised and anterior capsule was repaired. The coronoid was not fixed in this case. The collaterals were not involved. Good post operative rehabilitation after a period of three weeks of immobilization gave good result in our patient.

References

1. Wiegand L, Bernestein J, Ahm A. Fractures in Brief: Olecranon Fractures. Clin OrthopRelat Res.2012; 470:3637 -41.
2. Veillette, C.J., Steinmann, S.P., 2008. Olecranon fractures. Orthop. Clin. N. Am. 39, 229-236. doi: 10.1016/j.ocl.2008.01.002.
3. Citlak A, Guselb N, Kerinoglu V et al Bilateral isolated olecranon fracture after trauma report of 2 cases. Journal of experimental and clinical medical science 2014; 31:107 -10.
4. Z Zamzuri ,Nazri MY, Aminudin CA, Azril A, Shukrimi A, Hafiz A, and Khalid KA. Bilateral Olecranon Fracture in Adult. A Case Report. Int. Med J . June 2006; Vol. 5 No 1
5. Boufettal M, Zanati R E. Bilateral fracture of the olecranon in a young footballer. The Pan African Medical Journal. 2014;...
6. Patel A, Ullas T, Vikas, Divyang. Simultaneous Bilateral Traumatic Olecranon Process Fracture: A Rare Case Report. Journal of Dental and Medical Sciences. April 2016; Volume 15(4): 65-67
7. Kalande F. Bilateral Olecranon Fracture and Radio-Humeral Dislocation. The ANNALS of AFRICAN SURGERY. 2018; 15(2): 77
8. Kirmani, S., Draviaraj, K., Madegowda, B., Shahane, S., 2008. Spontaneous bilateral olecranon fractures in a rheumatoid patient. Ann. R. Coll. Surg. Engl. 90, 1-3. doi: 10.1308/147870808X257256.
9. O'Daly, B.J., Harty, J.A., O'Malley, N., Killeen, R., McDonnell, T.J., Quinlan, W.R., 2008. Bilateral olecranon fracture as first presentation of sarcoidosis: Case report and review of the literature. J. Shoulder. Elbow. Surg. 17, 1-5. doi: 10.1016/j.jse.2007.06.016
10. Newman, S.D., Mauffrey, C., Krikler, S., 2009. Olecranon fractures. Injury. 40, 575-581. doi: 10.1016/j.injury.2008
11. Wyrick JD, Dailey SK, Gunzenhaeuser JM, Casstevens EC. Management of complex elbow dislocations: a mechanistic approach. J Am Acad Orthop Surg. 2015;23(5):297–306.
12. Ring D, Jupiter JB, Sanders RW, Mast J, Simpson NS. Transolecranon fracture-dislocation of the elbow. J Orthop Trauma. 1997;11(8):545–50.

13. O'Driscoll SW, Jupiter JB, Cohen MS, Ring D, McKee MD. Difficult elbow fractures: pearls and pitfalls. *Instr Course Lect*. 2003;52:113–34.
14. Mortazavi SM, Asadollahi S, Tahririan MA. Functional outcome following treatment of trans olecranon fracture-dislocation of the elbow. *Injury*. 2006;37(3):284–8.
15. Mouhsine E, Akiki A, Castagna A, Cikes A, Wettstein M, Borens O, et al. Transolecranon anterior fracture dislocation. *J Shoulder Elb Surg*. 2007;16(3):352–7.
16. Sun Y, Cai J, Li F, Liu S, Ruan H, Fan, . The efficacy of celecoxib in preventing heterotopic ossification recurrence after open arthrolysis for post-traumatic elbow stiffness in adults. *Journal of Shoulder and Elbow Surgery* . 2015; 24(11): 1735-1740
17. Meyers C, Lisiecki J, Miller S, et al. Heterotopic Ossification: A Comprehensive Review. *JBMR Plus*. 2019;3(4):e10172. **Published** 2019 **Feb** 27. doi:10.1002/jbm4.10172

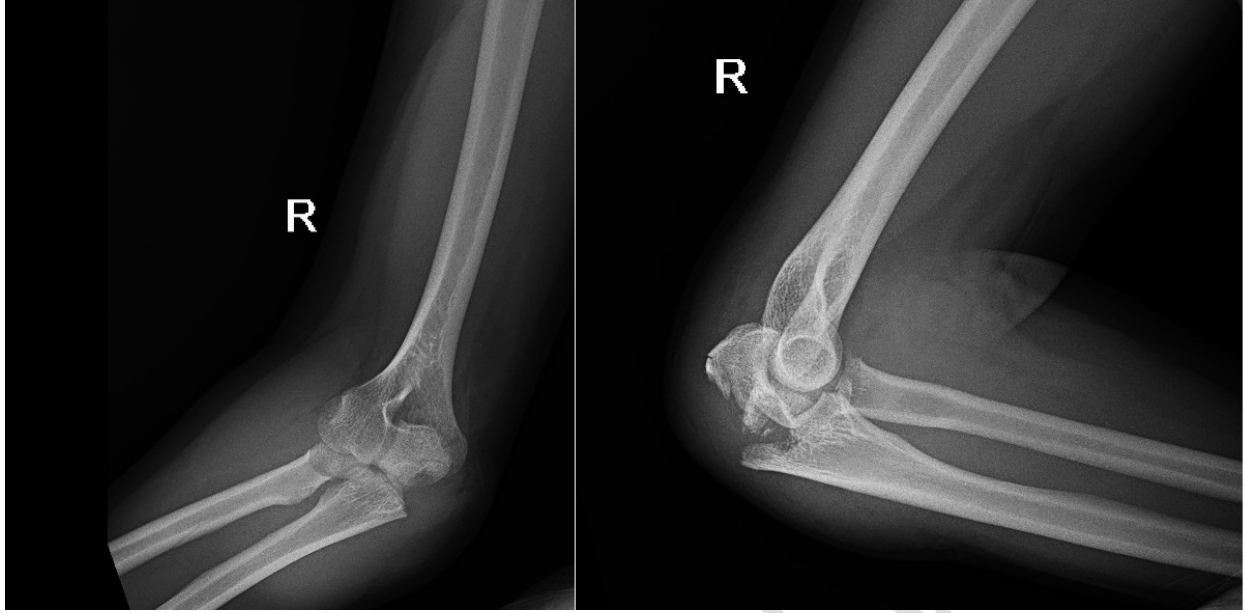


Fig: 1 x ray pre op R

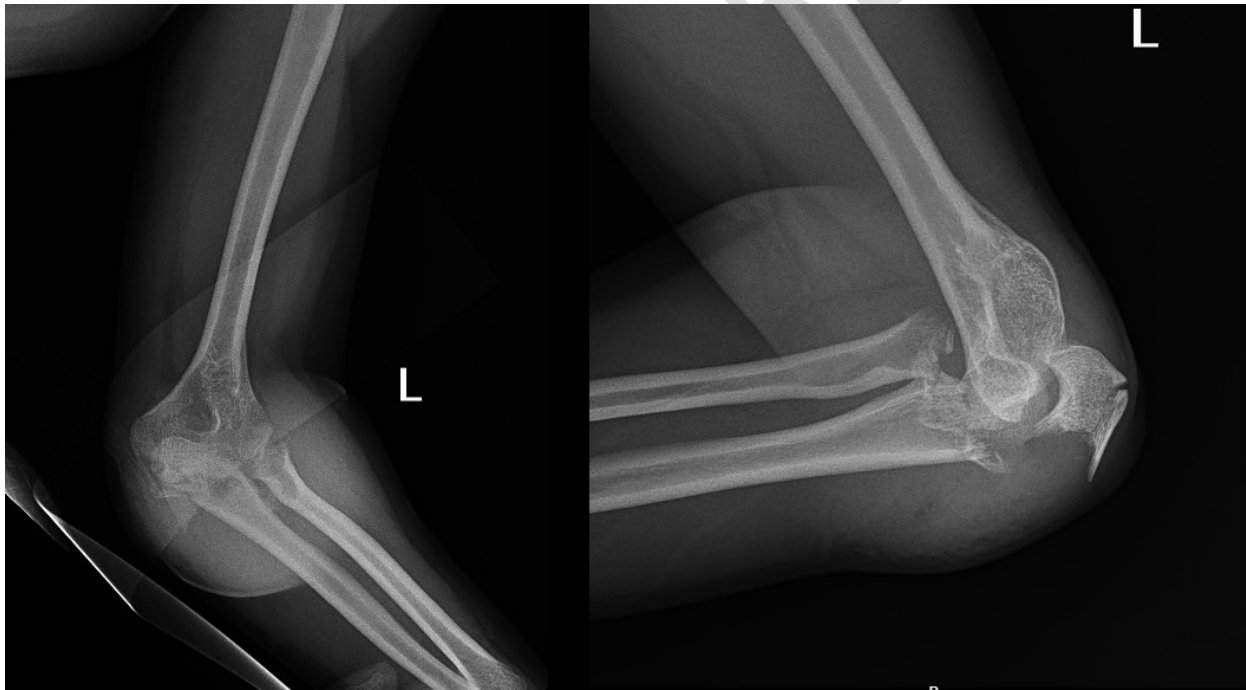


Fig: 2 xray preop L

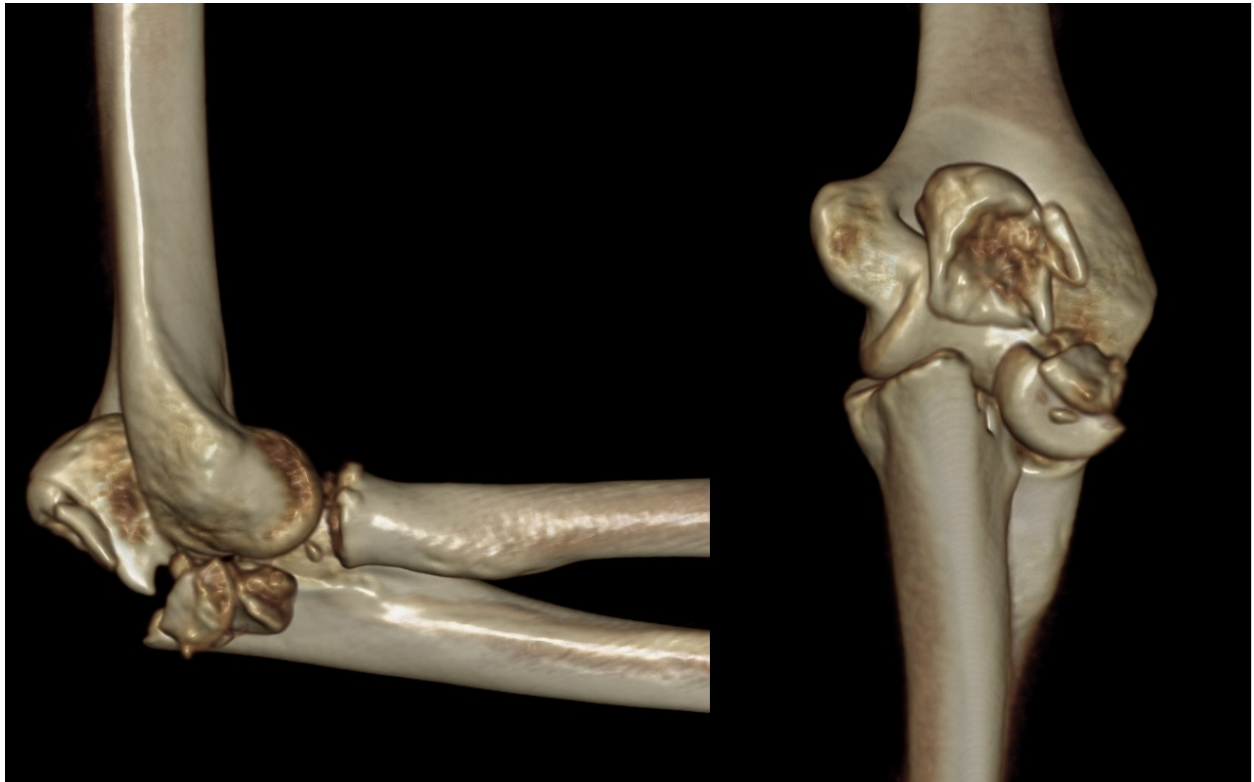


Fig :3 3d r ct final

UNDER PEE

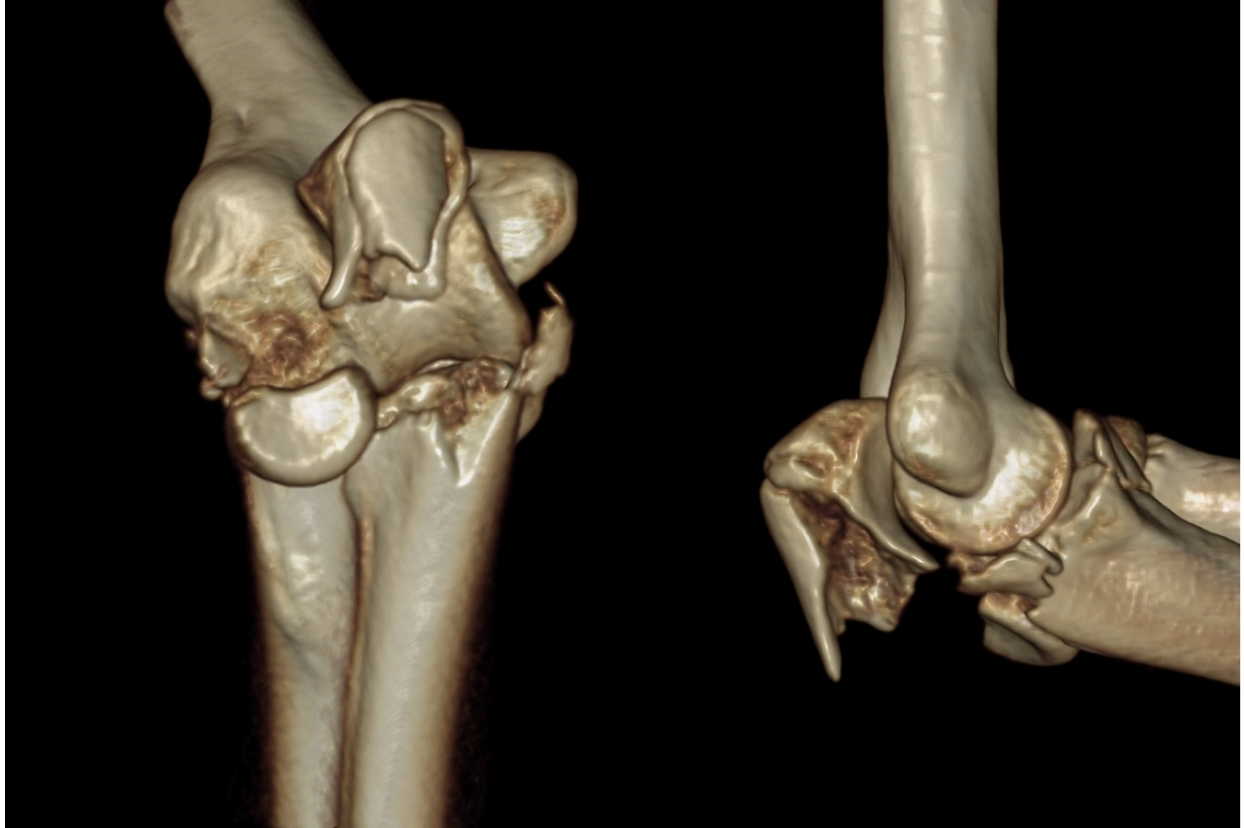

Fig: 4 3d left final ct

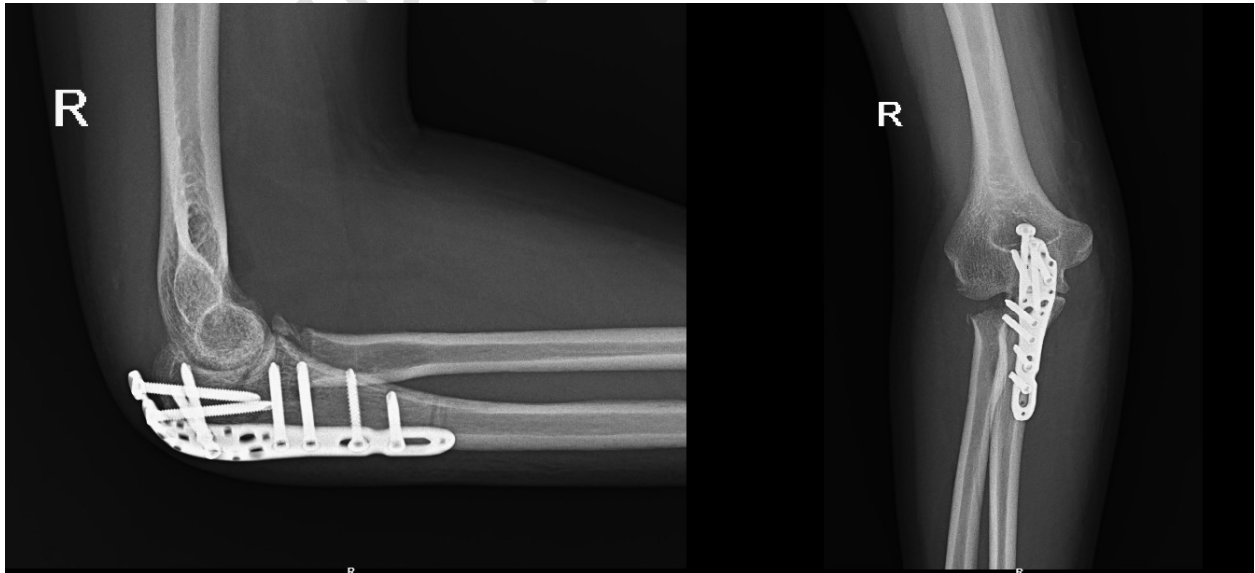


Fig :5 post op X ray R

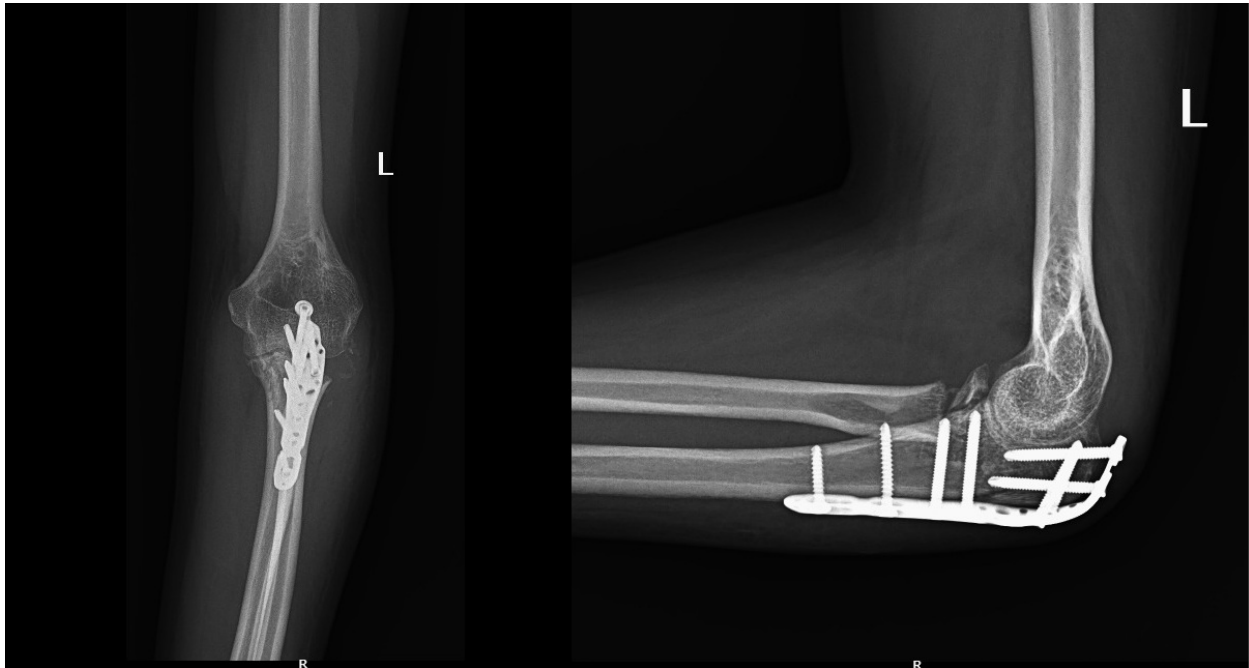


Fig: 6 post op x ray L

UNDER PEER REVIEW