

Histo-Architectural and Renal Function Markers in Long Term Consumption of Instant Noodles in Adult Wistar Rats

Comment [T1]:

Abstract:

Safety of all processed food has currently become an issue of public health concerned. This is especially due to the unchecked rate at which food industries turn out “novel” chemicals with the view to increasing brand acceptability. This study thus investigated the morphological and biochemical changes in the kidney of adult wistar rats fed with instant noodles. Fifty (50) adult wistar rats of an average of 180g were procured for the study. After two weeks of acclimatization, the rats were randomly grouped into five (5) (A, B, C, D and E) of ten (10) rats per group. Group A animals were fed with cooked instant noodle (Type A), group B rats received cooked instant noodles with its spice, group C received cooked noodle (type B) only, and group D animals received cooked instant noodles (type B) with its spice while group E (control animals received grower marsh for thirty (30) days. At the end of the administration of test substances, the animals were sacrifice by cervical dislocation and kidney tissue harvested and subjected to histological technique. Assay of selected renal function markers [Urea and Creatinine levels] was also conducted using serum. Statistical Package for Social Sciences (SPSS version 21) was used to evaluate the data obtained. Results (H&E) revealed that there was an enlarge Bowman’s space distortion and disruption of the cyto-architecture of the renal cortical structure and marked sign of diffuse nephritis of treated animals as compared to the control animal but with that of treated group B more marked. Study also found a statistically significant increase in serum urea levels of groups B, C and D wistar rats as compared to control; whilst observing a significant increase in serum creatinine levels of groups A and D wistar rats only as against the control (group E). Further study aimed at corroborating the findings from this work should be encouraged.

Keywords: Kidney, Instant Noodles, Histo-architecture, Renal function markers

Comment [T2]: There is need for conclusion of the research work before making recommendation, this is to actually give a summary of the major findings of the work.

Introduction

The kidneys are paired, bean-shaped organs that weighs between 125-170 grams in males and 115-155 grams in females. They are Located in the retroperitoneal cavity, just within the abdominal cavity; and are found in all vertebrates, one on each sides of the spine [1]. The left kidney is slightly smaller than the right; with each containing a number of pyramid shaped tubes of outer-renal cortex and inner renal medulla. Following between these kidneys layers are nephrons where urine production takes place [2]. Blood enters the kidney through the renal veins which accounts for about 25% of cardiac outputs [2]. The kidneys are vital life sustaining organs, performing many functions to keep the blood clean and chemical balance [1].

Comment [T3]: The L-letter should be small letter

Like most other vital organs in the body, the kidneys are susceptible to deleterious damages resulting from exposures to improperly processed foods. For example, studies have shown that heavy metals such as cadmium, lead, mercury, arsenic, aluminium and chromium are

toxic even in minute quantities, and are reportedly present in most fast foods [3]. These metals are bioactive, accumulating with time in the kidney and/or liver to trigger irreversible effects on individuals who consume such foods [4]. This may also lead to serious threats, renal failure, liver damage, neurological impairments, cardiovascular diseases and even death [5].

Nutritionally, instant noodles are high in carbohydrates (< 70%) and low in protein, fibre, vitamins and minerals [6]. All ultra-processed foods containing artificial food colours, flavourings and certain preservatives have adverse effects on children. However, the long-term consumption of instant noodles may affect vital renal function of glomerular filtration, thereby resulting in morphological changes in the kidney as well as very severe histopathogenesis [6]. According to indomie instant noodle report of 2016, their brand has been widely accepted by people across all ages in Nigeria that almost everyone in the country consumes instant noodles at one time or the other [8, 9]. The consumption of instant noodles is increasing globally, as at 2010 approximately 95 million people consume the products worldwide with China consuming about 42 billion packs yearly, accounting for about 44% of the world's noodle consumption [4]. Nigeria on the other hand consumes millions of packs yearly in homes and university campuses. For this, the country is ranked as the 13th largest consumer of instant noodles across the world [4]. College students with unhealthy dietary habit frequently eat instant noodles and may be at increased risk of negative outcomes [10]. Again, surveys have shown an increasing trend of early premature cardiovascular diseases (CVD) and death among adults as young as 20-49 years of age [10 & 11].

Aim of Study

This study aimed at evaluating the possible morphological and biochemical effects of long term consumption of instant noodles on the kidney of adult wistar rats. Specifically, the study investigated the;

- i. Histological changes associated with renal tissues as a result of long term consumption of instant noodles in adult wistar rats
- ii. Changes that long term consumption of instant noodles may have on selected renal function markers of adult wistar rats.

Materials and Methods

Animals:

Fifty (50) adult wistar rats of an average weight of 180 g, were procured from the animal holdings of the Department of Anatomy and Cell Biology, Delta State University, Abraka. The rats were then maintained in the Animal holdings of the Department of Public and Community Health, Novena University, Ogume, Delta State, Nigeria.

Comment [T4]: Why using up to 50 rats for this study? Since the researchers are not expecting high mortality of the rats, they could have use 25 rats so that each group will be 5 rats each not 10 rats as conducted in this research.

Study Design

At the end of two weeks period of acclimatization, the animals were randomly assigned into five (5) groups; with A, B, C and D being the treatment groups, while group E acting as control. Each group contained ten rats each. The treatment groups (Group A) received cooked instant noodle (Type A) only; whereas, animals in group B received cooked instant noodles with its spice. Group C animals received cooked instant noodles type B only. Group D received cooked instant noodles type B with its spice while rats in the control group E were fed with grower marsh obtained from Animal care services, Konsult (Nig Ltd), Asaba, Delta State for 30 days. The animals were given water liberally.

Ethical Clearance:

Ethical approval was obtained from the Research and Ethics committee of the College of Health Sciences, Novena University, Ogume, Delta State. Guidelines on use and handling of laboratory animals were also strictly followed, ensuring that no animal live was unduly wasted without actual need for it.

Comment [T5]: Life not live

Sacrifice and Tissue Extraction:

Twelve (12) hours following the last treatment (31st day), the animals (per group) were re-weighed and immediately sacrificed via cervical dislocation. Thereafter, the kidney was carefully removed and some fixed in 10% formal-saline for histological technique after the method of Kurman *et al.*, (2009) while some kidney samples were quickly homogenized in a mortar and pestle with a pinch of acid washed sand and a total of 5 mls of normal saline (0.9%) added sequentially [12]. The homogenates were centrifuged at 3500 rpm for five minutes with the aid of a centrifuge and kept in refrigerator for biochemical analysis on selected renal function markers. The clear supernatants were collected using a micropipette and transferred into an empty specimen container and refrigerated till needed for biochemical assay.

Comment [T6]: The kidneys were carefully removed instead of saying just kidney because many rats were used for this study not just one rat.

Comment [T7]: The researchers need to indicate the method used in removing the kidneys. Mostly, abdominal incision is used for this particular purpose.

Collection of Blood Sample

At the end of the period of administration, blood samples were collected from the orbital sinus of the animals through ocular puncture, following which they were sacrificed by cervical dislocation. Serum was then separated by centrifuging at 6000 rpm for 15 mins. various biochemical analyses [Urea and Creatinine assay] were thereafter conducted on obtained serum, while harvested organ [kidney] were subjected to histological processing/technique.

Comment [T8]: This supposed to come first immediately before collection of the kidneys. So, this should come first before collecting the kidneys.

Comment [T9]: Precisely how many ml of blood was collected?

Comment [T10]: Urea and creatinine assays were thereafter.....

Histological Study

Harvested kidney tissues were dehydrated in an ascending grade of alcohol (ethanol), cleared in xylene and embedded in paraffin wax. Serial sections of 7 microns thick were obtained using a rotatory microtome. Deparaffinised sections were then stained routinely with Hematoxylin and Eosin [H&E]. Photomicrographs of the results were obtained using research photographic microscope in the Department of Anatomy and Cell Biology, Faculty of Basic Medical Sciences, Delta State University, Abraka, Delta State, Nigeria.

Comment [T11]: Impregnated and embedded in paraffin wax.

Creatinine Assay

Creatinine was assayed in serum by a colorimetric method using the Jaffe kinetic method.

Test principle:

This is based on the principle of creatinine reacting with picric acid under alkaline condition to form a yellow-red complex. The absorbance of the colour produced, measured at a wavelength of 492nm is directly proportional to creatinine concentration.

Creatinine + picrate (*alkaline pH*) Yellow-red complex Procedure: This was performed according to manufacturer's guideline (*Randox Labs, UK*). Briefly, 1.0ml and 100µl of working solution and sample respectively were pipette and mixed in a cuvette. After 30 seconds, the absorbance (A1) of the standard and sample were read in spectrophotometer. Exactly 2 minutes later, the absorbance (A2) of the standard and sample was read. The concentration of creatinine in the sample was determined as follows:

$$A_2 - A_1 = \Delta A_{\text{sample}} \text{ or } \Delta A_{\text{standard}} / \Delta A_{\text{sample}} \times \text{standard conc. } (\mu\text{mol/l}) = \text{Creatinine conc. } (\mu\text{mol/l})$$

Urea Assay

Urea was assayed in serum using a urease-Berthelot method (*Randox, UK*) following the manufacturer's guidelines. Test principle: Urea in serum is hydrolysed to ammonia in the presence of urease. The ammonia is then measured photometrically by Berthelot's reaction.

Urea + H₂O (*Urease*) 2NH₃ + CO₂ NH₃ + Hypochorite + phenol indophenols (blue compound)

Procedure:

10µl each of sample, standard and blank (distilled water) were mixed with 100µl of Reagent 1 (*Randox, UK*) in separate test tubes. These were mixed and incubated at 37°C for 10mins. 2.5ml each of Reagents 2 and 3 (*Randox, UK*) were added to each of the test tubes containing the sample, standard and blank, mixed and incubated for 15mins at 37°C. The absorbance of the sample (A_{sample}) and standard (A_{standard}) were measured against blank at 546nm wavelength spectrophotometer. Serum urea concentration was calculated as follows:

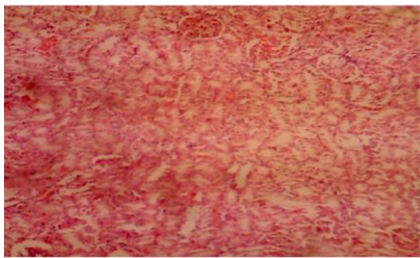
$$\text{Urea concentration} = A_{\text{sample}} / A_{\text{standard}} \times \text{standard conc (mmol /L)}$$

Analytical Approach

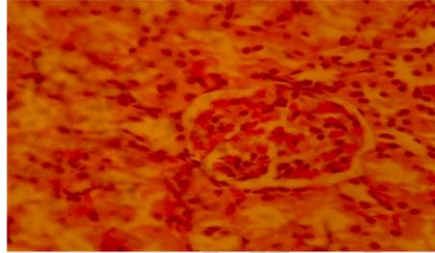
Results obtained from the study were recorded and compared statistically using the unpaired sample t-Test and symmetric measured t -Test of the Statistical Package for Social Sciences (SPSS version 22). The results from the various assay were also analysed and taken the significant level of (p < 0.05) as taken below variables

Results

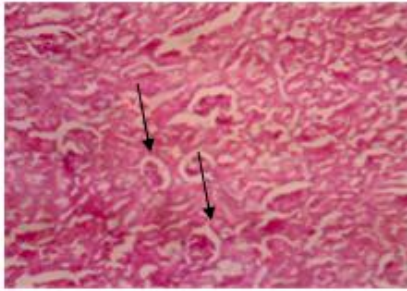
Figure I: Showing Renal Histo-Architectural Changes in the Kidney of Control and Instant Noodles Fed Wistar Rats of Group A



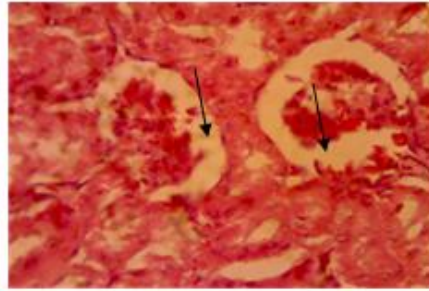
Control Kidney x 100



Control Kidney X 400



A kidney x 100

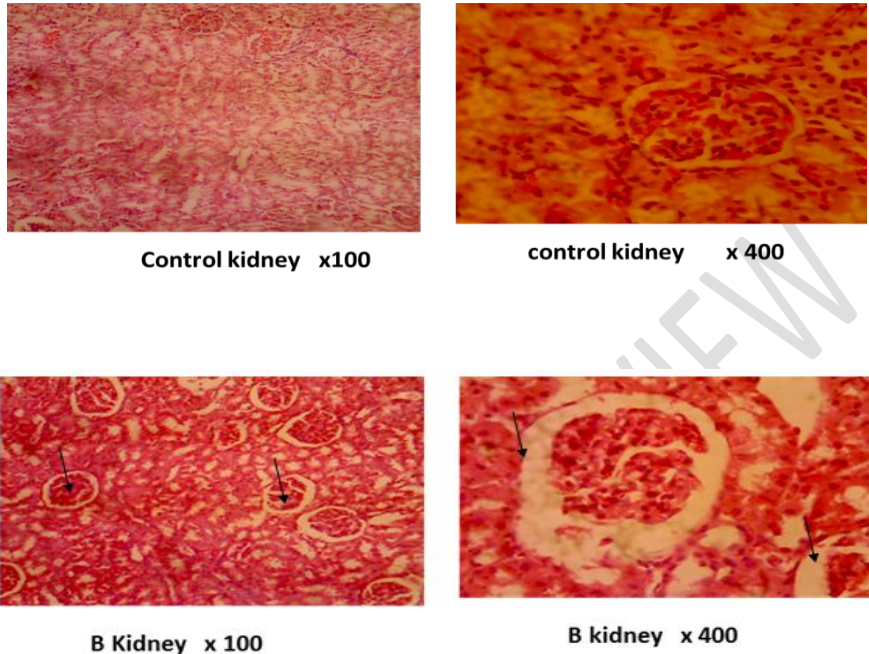


A kidney x 400

Control: The desired section of control group animals showed normal histological features in glomerular and nephrons appearing distinct and of various sizes. The various micro-anatomy structures appeared normal with no distortion or enlargement. **A:** The treated group A revealed some degenerative changes in micro-anatomy of the Kidney, increase in Brownman's space and some sign of diffuse nephritis.

Comment [T12]: The arrows should be coloured and what each arrow is pointing at should be describe. Likewise, the staining method employed should be stated at the end of the statement either alone or in a bracket.

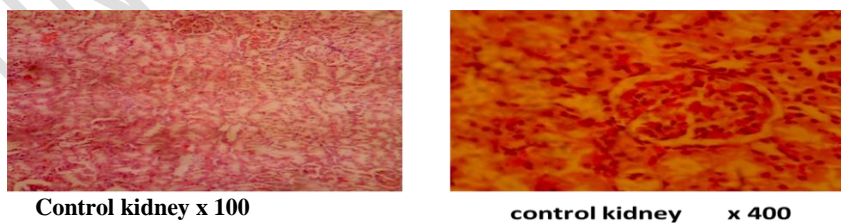
Figure II: Comparative Histo-Architectural Changes in the Kidney of Control and Group B Wistar Rats

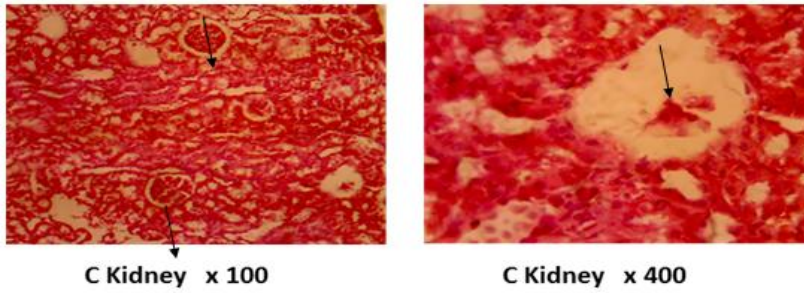


Control: The desired sections of control group of animal showed normal histological features in all micro-anatomy of kidney appearing normal in various sizes. No distortion, enlargement or disruption. **B:** The treated group B animals revealed some damages in micro-anatomy in the kidney. There is some dilated Bowman's space, some obvious level of distortion and disruption of the renal cortical structure as compared to control group. There are some sign of diffuse nephritis and damage in mesangial cells of juxtaglomerular apparatus of the treated group as compared to the control group.

Comment [T13]: The arrows should be coloured and what each arrow is pointing at should be describe. Likewise, the staining method employed should be stated at the end of the statement either alone or in a bracket.

Figure III: Comparative Histo-Architectural Changes in the Kidney of Control and Group C Wistar Rats



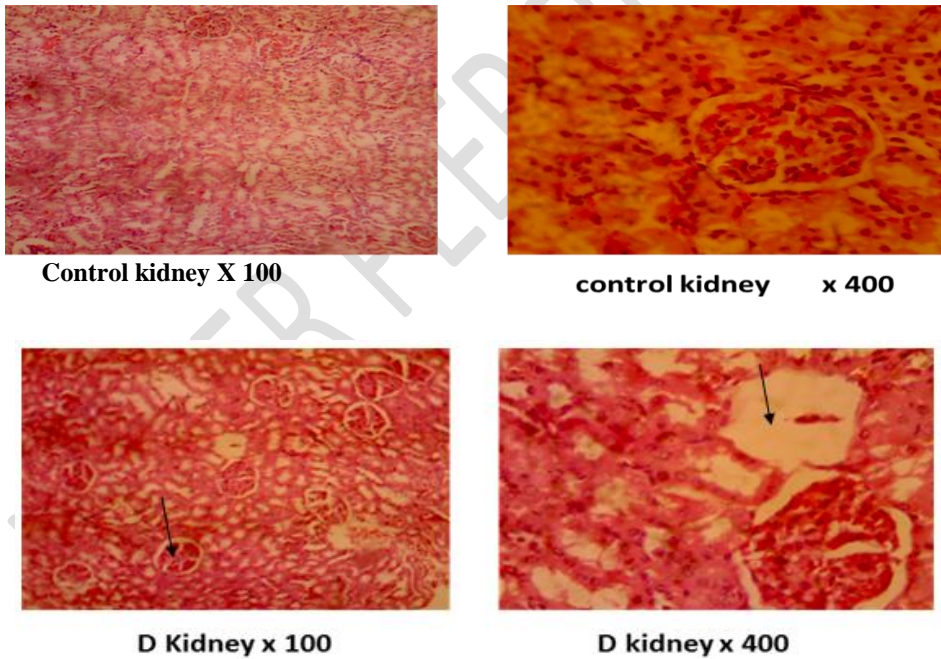


C Kidney x 100 **C Kidney x 400**

Control: The desired section of control group showed normal histological features in the micro anatomy of the kidney. Appearing normal in various sizes with no distortion, enlargement or disruption of any kind in the cytoarchitecture of the kidney. **C:** The treated group C animals revealed some degenerative changes (damage) in micro-anatomy of kidney. Thus, there is increased in parietal epithelium of the Bownman's capsules and signs of diffuse nephritis in the treated group as compared to the control group.

Comment [T14]: The arrows should be coloured and what each arrow is pointing at should be describe. Likewise, the staining method employed should be stated at the end of the statement either alone or in a bracket.

Figure IV: Comparative Histo-Architectural Changes in the Kidney of Control and Group D Wistar Rats



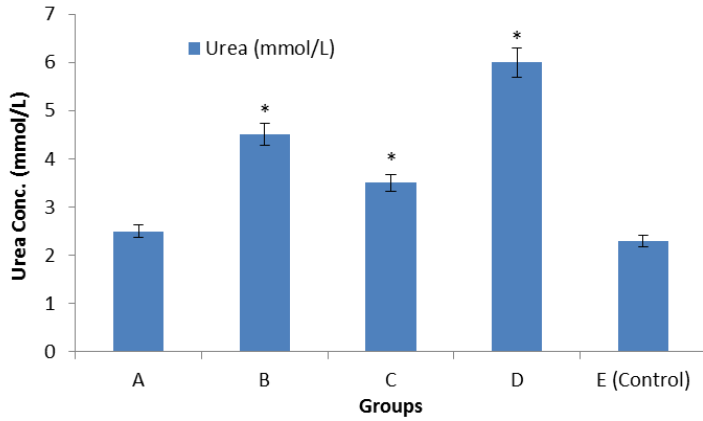
Control kidney X 100 **control kidney x 400**

D Kidney x 100 **D kidney x 400**

Control: the desired section of control group showed normal histological features in the micro anatomy of kidney appearing normal in various sizes with no distortion, enlargement or disruption of any kind. **D:** the treated D group revealed much more damages in the micro-anatomy of kidney, where the damages included the following: Parietal epithelium of bowman's capsule. Also noticeable is an enlarged Bowman's capsule, implicative of nephritis as well as distortion and disruption of the renal architecture

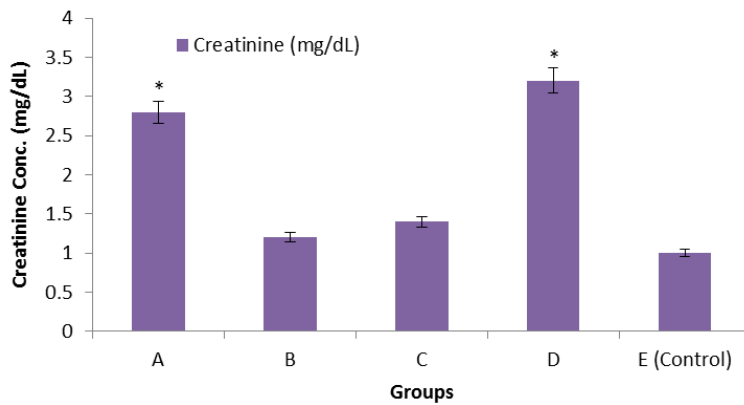
Comment [T15]: The arrows should be coloured and what each arrow is pointing at should be describe. Likewise, the staining method employed should be stated at the end of the statement either alone or in a bracket.

Figure V: Comparative Effects of long-term consumption of noodles on Urea Levels of Wistar Rats



* = Statistically significant increase ($p < 0.05$) as compared to control group

Figure VI: Comparative Effects of long-term consumption of noodles on Creatinine Levels of Wistar Rats



* = Statistically significant increase as compared to control group

TABLE I: Urea and Creatinine levels of the Animals

	A	B	C	D	E	f	p-value
Urea	2.58±0.26 ^a	4.50±0.45 ^{bc}	3.64±0.49 ^{ab}	5.88±0.13 ^c	2.29±0.11 ^a	19.701	0.000
Creatinine	2.85±0.40 ^{ab}	1.40±0.20 ^{ac}	1.72±0.10 ^{ac}	3.30±0.55 ^b	1.17±0.09 ^c	8.357	0.000

Values are expressed as Mean±SEM; Mean with different superscript are statistically significant @ $p < 0.05$

Discussion

It has been reported that Instant noodle and its flavouring sauce base contain huge amount of monosodium glutamate (MSG), which causes neuroplacental neurotoxic effect. MSG also reportedly causes cataract, causes induced retinal lesions and genotoxicity [13 & 14]. Our study focused on evaluating the possible morphological and functional changes associated with long term consumption of instant noodles on the kidney of adult wistar rats.

Comment [T16]: [13,14] not [13 &]

Histological findings

Histological findings revealed that there was an enlarge Bowman's space, distortion and disruption of the cyto-architecture of the renal cortical structures and marked sign of diffuse nephritis of the treated animals as compared to the control animals but with that of the treated group B more marked.

Comment [T17]: Delete

The result obtained in this experiment is in consonance with and continuation of the work carried out by Enaibe *et al.*, [2007] which reported that administration of camphor resulted in mild edema with glomerular nephritis, glomerular labulation, tubular necrosis and congestion of blood cell in the kidney rabbit [15]. Administration of damiana (tamera diffuse) to matured wistar rats resulted in distortion of the renal cortical structures, reduced size and necrosis in the histology of kidney [16]. The related findings also implicate soda drink as capable of precipitating kidney disease probably by causing congestion and tubular necrosis of kidney. Pathological or accidental cell death is regarded necrotic and could result from extrinsic insult to the cell as osmotic, thermal, toxic and traumatic effect [17]. The process of cellular necrosis involves disruption of membranes as well as structural and functional integrity. Cellular necrosis is not induced by stimuli intrinsic to the cells is in programmed cell death but by abrupt environmental perturbation and departure from the normal physiological conditions [18 & 19]. In this experiment, the noodles consumption may have acted as toxin to the cell of the kidney resulting in the distortion and disruption, congestion and glomerulanephritis.

Comment [T18]: Insert in a bracket: [2007]

This study has not looked into mechanism of renal damage. The report is limited simply to a general statement about the overall architecture of tissue consumption of carbonated soft drink has been implicated in several diseases including cardiology, diabetic and renal calculi [20].

Comment [T19]: This has no link with any part of the work, so delete

Table I shows effects of instant noodle formulated-diet on the concentration of serum urea and creatinine of adult Wistar rats. From our result, although there was a slight decrease

in both parameters compared to control, the increase was not significantly different ($p < 0.05$). Renal function indices are used to assess the normal functioning capacity of the different parts of the nephron [21]. Urea excretion by the kidney is the primary method of nitrogen excretion while creatinine, a catabolic product of muscle is a useful index of assessing the functional capacity of the glomerular and tubular regions of the nephrons and low levels are seen in some types of liver disease and diets that are very low in protein [22].

For results obtained in urea levels (figure V), it is noticed that addition of spice caused a statistically significant increase in serum urea levels. This increase could be traceable to high protein breakdown and could be implicated in passage of excess protein in urine (proteinuria). The possible cause of this is likely due to the disruption and distortion of the renal filtration membrane as a result of the active ingredients in the added spice as against those of control animals. This finding is supported by those of *Adjene et al., 2010* who previously reported a disruption and distortion of soda pop and *Phyllanthus amaranthus* on the kidney following prolonged administration [20 & 23]. *Enaibe et al* had also reported something similar with camphor; proving distortion in renal cortical structures in administration of camphor on wistar rats [15].

For serum creatinine levels, a statistically significant increase ($p < 0.05$) is also seen for spice addition to instant noodles (figure VI) in Wistar rats. Theoretically, creatinine is a product of muscle breakdown, and often almost surges in the serum to indicate an increase in muscle metabolism. In this case, high levels serum creatinine will also be seen in the urine, which may implicate renal dysfunction as a result of damage to cortical structures. This finding also supports the previous report of *Adjene et al., 2010* [23].

Conclusion

Results (H&E) revealed that there was an enlarge Bowman's space distortion and disruption of the cyto-architecture of the renal cortical structure and marked sign of diffuse nephritis of treated animals as compared to the control animal but with that of treated group B more marked. Study also found a statistically significant increase in serum urea levels of groups B, C and D wistar rats as compared to control; whilst observing a significant increase in serum creatinine levels of groups A and D wistar rats only as against the control (group E).

Comment [T20]: We noticed not it is noticed, the researchers need to own this work

Comment [T21]: Adjene et al.[2010]

Comment [T22]: [20,23]

Comment [T23]: Insert the year in a bracket after Enaibe et al.

Comment [T24]: Adjene et al. [2010].

Comment [T25]: The histo-architectural appearance of the treated kidney sections revealed

Comment [T26]: This work is not well concluded, kindly rephrase your conclusion like Administration of Instant noodles to Wistar rat for 30 days revealed histo-architectural distortions and increase in serum urea and creatinine levels. Hence the need to be very careful in regulating intake of Instant noodles

References

1. Maton, A., Jean, H., Charles, W., Malaughlin, Susan, J., Maryanna, W. W., David, L. Jill, D.W. (2013). Human Biology and Health Englewood Cliffs, New Jersey, USA: Prentice Hall ISBN 0-13-981176-1
2. Tolaram, Group (2012). Instant noodles industry in Nigeria and related issues. Available online: www.lbs.edu.ng/LBSBreakfastClub/Nigeria%20Noodle%20Industry.pdf (Accessed 04 October 2017).
3. Udeogu, E; Onyeka, E.U; Umelo, M.C. (2014). Potentials of using cowpea - wheat composite flour in noodles products. *European International Journal of Applied Science and Technology*, 2014; 1.
4. Marketing Edge, (2017). Battle of noodles brands over market share. Available online: <http://www.marketingedge.com.ng/2017/01/27/battle-of-noodle-brands-over-market-share/> (Accessed 04 October 2017).
5. World Instant Noodles Association (2016). Global demand of instant noodles: top15. https://instantnoodles.org/en/common_en/pdf/EN_MARKET_VOLUME_3LG_A4_2016.pdf
6. Sanni, M; Ejembi, D; Emmanuel, T. F; Abbah, O. C; Okwutachi S.O. (2013). Effects of chronic administration of indomie noodles on the activity of alkaline phosphatase of rat small intestine. *Journal of Pharmaceutical and Biomedical Sciences*, 2013; 34(34): 1682 - 1687.
7. Morgan M, Keefe EB. (2009): Diagnosis and treatment of chronic hepatitis B. update. *Minerva Gastroenterol.Dietol.* 2009(1); 55:5–22.
8. Sikander, M., Arif, M., Muhammad, S., Ghayas, K. Qurratal-Ain, M., Rabia, G.K. (2017). Instant noodles: are they really good for health? *Electronic Journal of Biology*. Vol. (3) 222 – 227.
9. Eze, G.I., Ehimugbai, A.R.O. Ezugwu, W.S., Okafor, F.O. (2017). Morphological changes-induces by instant noodles food on kidney of adult New Zealand Rabbit. *IOSR journal of dental and medical sciences (IOSR-IDMS)* e-ISSN: 2279–0858 P. ISBN: 2279 – 0861. Vol. 16, issue 1 ver.
10. Adi, A.H., Alturkmani, H.J. (2013). Physiologically lucky: the role of medical physiology in modern medical education: an interview. *Perspect Med. Educ.*, 2: 99–103.
11. Kim, H.K., Ahn, Y. (2015). Mortality trends of cardiovascular disease in Korea; big challenges in ischemic heart disease. *Korean Circ J* 2015; 45:192-3.

Comment [T27]: Journal names need to be italicized

Comment [T28]: Delete

Comment [T29]: italicize

Comment [T30]: Delete

Comment [T31]: Name of the journal should be written in full

Comment [T32]: Delete

Comment [T33]: Write the name of the journal in full

Comment [T34]: Delete

12. Korman, J.D, Volenberg I, Balko J, Webster J, Schiodt FV, Squires RH, Jr., et al. (2008). Screening for Wilson disease in acute liver failure: a comparison of currently available diagnostic tests. *Hepatology*, 48(4):1167–74.

Comment [T35]: Italyze

Comment [T36]: Should be comma not full stop

13. Kim, M.J., Shin, S.N., Kim, S.K. (2000). Proximate composition and calorie of Korean instant noodles. *Korean J Food Sci. Technol* 2000; 32:1043-50.

Comment [T37]: Write the name of the journal in full

Comment [T38]: Delete

14. Misra H. and Fridovich I. (1972). The purification and properties of superoxide dismutase from *Neurospora crassa*. *J. Bacteriol.* 247: 3410.

Comment [T39]: Write the name of the journal in full

15. Enaibe, B.U; Adjene, J.O; Eweka, A.O. and Adefolaju G.A: Histological effects of camphor administration on the histology of the Kidney of Rabbit (*Oryctolagus cuniculus*). Centrepoint (Science Edition) (2006/ 2007) Vol.14 No.1& 2: 118 -124

16. Jarup, L. (2003). Hazards of heavy metal contamination. *Br Med Bull* 68(1):167–182

Comment [T40]: Recast

17. Shin, H.J, Cho, E., Lee, H.J., Fung, T.T., Rimm, E., Rosner, B., Manson, J.E., Wheelan, K., Hu, F.B. (2014): Instant noodle intake and dietary patterns are associated with distinct cardiometabolic risk factors in Korea. *J Nutr* 2014; 144:1247-55.

Comment [T41]: Write the name of the journal in full

Comment [T42]: Delete

18. Lee, E.T. (2009). Utilization of Australian wheat for Korean style dried noodle making. *J. Cereal Sci.* 6, 283–297.

Comment [T43]: Write the name of the journal in full

19. Ahsan, R., Islam, M., Bulbul, J.I, Musaddik, A. Haque, E. (2009). Hepatoprotective activity of methanol extract of some medicinal plants against carbon tetrachloride-induced hepatotoxicity in rats. *Eur. J. Sci. Res.* 37: 302–310.

Comment [T44]: Write the name of the journal in full

20. Adjene, J.O; Ezeoke, J. C; Nwose, E.U: Histological effects of chronic consumption of soda pop drinks on kidney of adult wistar rats. *North Am J Med Sci.* 2010; 2 (5):215-217

Comment [T45]: Write the name of the journal in full

Comment [T46]: Delete

21. Al-Busaidi, M., Yesudhasan, P., Al-Mughairi, S., Al-Rahbi, W.A., Al-Harthy, K.S, Al-Mazrooei, N.A., Al-Habsi, S.H (2011). Toxic metals in commercial marine fish in Oman with reference to national and international standards. *Chemosphere* 85(1):67–73

22. Das, A.K. (2010). Environmental chemistry with green chemistry. ArvinabaSen Books and Allied (p) Ltd, Kolkata, p.201

23. Adjene, J.O, Nwose, E.U: Histological effects of chronic administration of *phyllanthus amaranthus* on the kidney of adult wistar rats. *North Am J Med Sci.* 2010; 2 (4):193-195.

Comment [T47]: Write name of the journal in full

Comment [T48]: Delete