

Surgical Separation of Thoraco-omphalopagus Conjoined Twins After SARS-CoV-2 Infection- Thoracic Surgery Perspective: A Case Report

ABSTRACT

Conjoined twins are a rare phenomenon of monochorionic monoamniotic twins, with an incidence of 1 in 50,000 to 200,000 births. They have a low survival rate of 7.5%, and 40% of surgically separated twins don't survive. The SARS-CoV-2 infection has contributed to 178 million infections globally and 3.8 million deaths. Surgery after a previous SARS-CoV-2 infection should be timed to ensure the safest delivery of perioperative care. It may cause multisystem disease with short and long-term sequelae that could impact postoperative recovery. We report a case of 16-months-old thoraco-omphalopagus twins with complaints of fever and respiratory distress. The twins tested positive for SARS-CoV-2 infection, and one of them continued to experience recurrent desaturation with respiratory acidosis. The patient was not able to wean from the ventilator and had recurrent ventilator-associated pneumonia. Imaging of the lungs showed consolidation in the 2nd and 3rd segment of the right lung of one of the twins and multiple consolidations in the 1st, 2nd, 3rd, and 6th segment of the left lung, accompanied with ground glass opacities in the 1st and 2nd segment of the right lung of the other, both suggestive of pneumonia. Thus, we decided to **undertake** elective surgery for separation **of the twins**, two months after their SARS-CoV-2 infection had resolved. A multidisciplinary team performed a successful separation of the twins with minimal blood loss and no intraoperative complications. The postoperative assessment showed no signs of chronic pulmonary dysfunction, and the patients were able to wean from the ventilator after the procedure.

Keywords: conjoined twins, SARS-CoV-2, thoracic surgery, thoraco-omphalopagus

1. INTRODUCTION

Conjoined twins refer to monochorionic monoamniotic twins fused in utero,¹ with an incidence of 1 in 50,000 to 200,000 births.² From those statistics, 28% of them **were** thoraco-omphalopagus twins, where they **were** joined face-to-face with their thorax and abdomen fused.³ Prenatal imaging with ultrasonography during the first trimester helps early diagnosis of conjoined twins, and the choice of terminating a pregnancy can be presented to the parents. Prenatal magnetic resonance imaging (MRI) also aids in determining the location of **the** fusion.

However, developing countries such as ours lack adequate maternal health care facilities, thus delaying the diagnosis. If conjoined twins survive until birth, doctors are faced with two options: to separate or not to separate the twins. Separation is feasible when vital organs are not shared extensively between the twins. Thus, imaging the anatomical relationship between the twins is crucial in making surgical decisions. Unfortunately, despite advances in imaging techniques, the prognosis for conjoined twins is still lacking. Conjoined twins have a total survival rate of 7.5%, and 40% of surgically separated twins don't survive.⁴ Although surgical separation of conjoined twins is the ideal goal. However, it remains a challenge for anesthesiologists and surgeons due to complex anomalies and their unpredictable response to anesthesia due to vascular shunts and cross circulations.⁵ The SARS-CoV-2 disease has contributed to more than 178 million infections globally and more than 3.8 million deaths from COVID-19, and the number of these cases continues to increase every day.⁶ Surgery after a previous SARS-CoV-2 infection should be timed to ensure the safest delivery of perioperative care. SARS-CoV-2 infection may cause multisystem disease with short and long-term sequelae, including chronic pulmonary dysfunction, myocardial inflammatory states, renal impairment, psychological distress, chronic fatigue and musculoskeletal deconditioning. These short and long-term complications of SARS-CoV-2 infection could impact upon postoperative recovery, and therefore these complications must be considered to plan safe surgery.⁷ Here, we present a rare case of thoraco-omphalopagus twins after SARS-CoV-2 infection successfully separated through the cardiothoracic surgeon perspective.

2. PRESENTATION OF CASE

A pair of 16 months old conjoined twins were referred to our institution from a remote hospital with primary fever and respiratory distress complaints progressing from 10 days before their admission. The babies were treated at the regional hospital for three days but showed no improvement. The patients were then referred to our hospital. In our institution, the conjoined female twins were suspected of having SARS-CoV-2 infection, so we took the oropharyngeal swabs from the patients for PCR test for SARS-CoV-2 infection, and both tested positive for SARS-CoV-2 infection. Baby A's condition was lethargic with increased work of breathing accompanied by recurrent desaturation. Blood gas analysis of Baby A showed respiratory acidosis, so we decided to intubate and give adequate sedation to control the baby's breathing. Baby B's condition was stable and unremarkable. Therefore, treatment for SARS-CoV-2 infection was undertaken. The patients then subsequently had a repeat PCR Swab for SARS-CoV-2, and the result was negative. Hence, the patients could not be weaned from the ventilator due to having recurrent VAP. A multidisciplinary meeting was then undertaken and following the discussions at the meeting, we decided to undertake elective surgery two months after obtaining their negative SARS-CoV-2 results. The patients' preparation for surgery was undertaken, the patients had an abdominal ultrasound scan which showed fusion between the 2 livers within the midline regions, but there was no abnormality within other abdominal organs. CT angiography was performed, which demonstrated thoraco-omphalopagus twins, conjoined from the sternum with a surface area of 15 x 9 cm². No cardiac abnormalities nor fusion were found. Imaging of the lungs showed consolidation in the 2nd and 3rd segment of the right lung of Baby A, and multiple consolidations in the 1st, 2nd, 3rd, and 6th segment of the left lung, which was accompanied with ground glass opacities in the 1st and 2nd segment of the right lung, that was suggestive of pneumonia. A three-phase CT angiography of the liver was performed. Pooling of the contrast was found in the anterior part of the left and right segment of the liver, which suggested arteriportal shunting. The left portal vein of Baby B was also connected to the left portal vein of Baby A (Figure. 1).

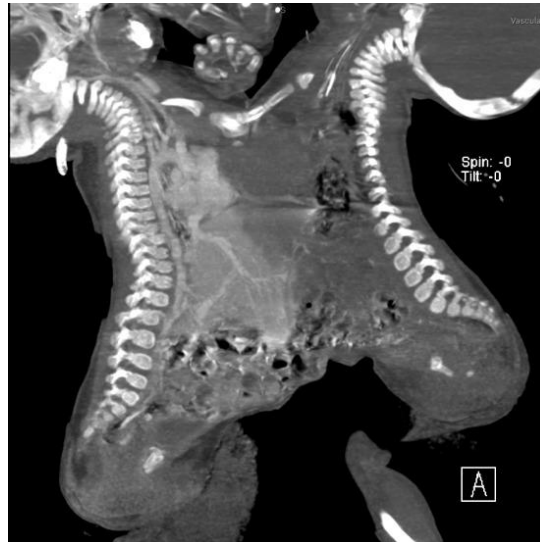

Figure 1. CT angiography of the two babies

The separation operation was performed when the babies were 18 months old, two months after their SARS-CoV-2 infection had resolved. The 15-hour procedure was performed by a multidisciplinary team consisting of 2 cardiothoracic surgeons, three paediatric surgeons, and four plastic surgeons that allowed two separate teams to be created once the twins were separated. Total blood loss was approximately 200 cc, and there were no intraoperative complications.

2.1 Surgical Techniques

The conjoint twins were positioned in such a way that Baby A was in the right lateral decubitus position. An abdominal wall incision was also made until the peritoneum was breached. We found the fusion of the two livers in the middle, where all the other organs (gallbladder, stomach, intestines) were separated from each other. The livers were then separated, and this separation was performed by a pediatric surgeon. An incision was made in the lateral chest wall until the fascia was reached, the sternum and xiphoid of Infants A and B were separated. The pericardium of the two babies were separated from each other, where the pericardium of baby B was still intact while the pericardium of baby A was open. (Figure. 2) After that, the posterior diaphragm was released. Complete separation of the twins was then performed.

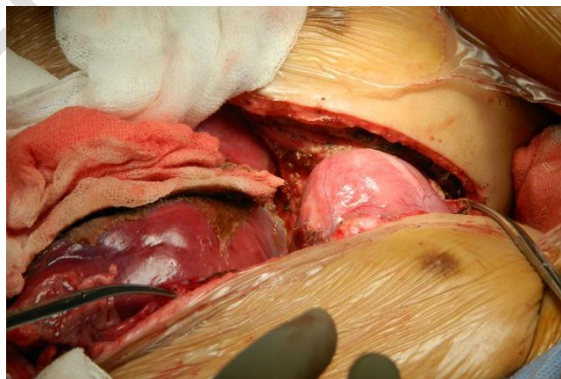


Figure 2. Separation of pericardium of two babies

In baby A, we found a significant defect of the thoracic wall with no sternum and an exposed pericardium (Figure 3). The thoracic wall reconstruction was done using a metal plate by fixating the metal plate to each side of the costal angle with interrupted sutures using 2/0 polypropylene. The diaphragm was then

reconstructed and fixated to the posterior part of the screw plate with interrupted sutures using 2/0 polypropylene to prevent flailing of the diaphragm. The costal side of the metal plate was then sutured with sternal wire to the metal plate on the diaphragm side to achieve fixation of the thoracic wall. Reconstruction of the pericardium for Baby A was performed using a GORE-TEX® patch of size 0.6 mm x 50 mm x 75 mm, where it was sutured into the surrounding pericardium with continuous suture using 3/0 polypropylene. (Fig. 4). A pneumothorax was found in the left lung. Thus a 16F thoracostomy tube was inserted into the pleural cavity. Decompression of the intestines was performed by the pediatric surgeon in Baby A. Mesh was situated to cover the abdominal cavity from peritoneal fascia to the diaphragm side of the metal fixation. The anesthesiologist evaluated the breathing mechanism on the ventilator, and we found that we needed high pressure to ventilate the patient. We decided to delay the skin reconstruction. The thoracic and abdominal defect was closed using a blood bag, vacuum drain was placed above the abdominal mesh. The whole thoracoabdominal defect was then covered with Op-site®.

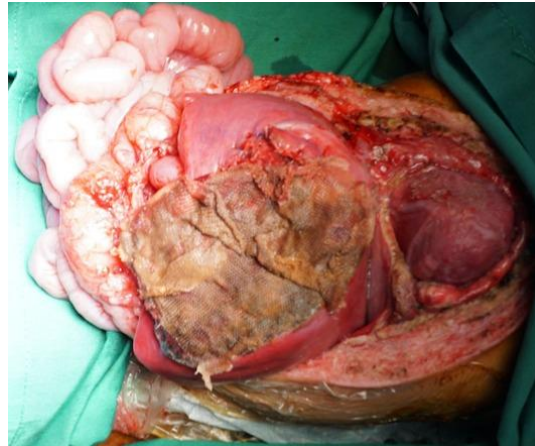


Figure 3. Defect of the thoracic wall with no sternum and an exposed pericardium

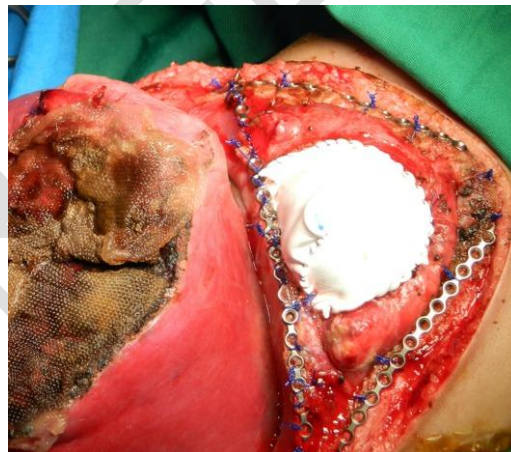

Figure 4. Reconstruction of the pericardium for Baby A

In Baby B, the sternum was incomplete on the left side. The ribs (costae) on the left side were not connected with the sternum and the left pleura was perforated. The pericardium and diaphragm were intact. The left side of the sternum was reconstructed and fixated using a metal plate with interrupted sutures using 2/0 polypropylene. The diaphragm was fixated to the plate connecting both hemithorax with interrupted sutures using 4/0 polypropylene.

A surgical mesh 20,3 cm x 30.5 cm was used to close the thoracic cavity and abdomen (Fig. 5). The liver of Baby B was approximated to unite the raw surfaces by a pediatric surgeon. Finally, the anterior thorax and

abdomen defect were closed using a local flap by the plastic surgeon. Both babies were stable after the procedure and were transferred to the pediatric intensive care unit and they tolerated the ICU ventilation well.

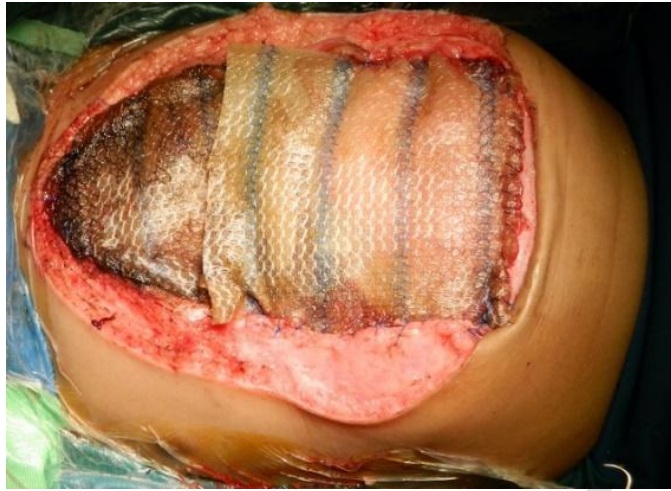

Figure 4. Surgical mesh to close the thoracic and abdominal cavity

In Baby A, closure of the thoracic and abdominal cavities were initially delayed and these gradually closed using a local flap and split-thickness skin graft (STSG) in the donor area within three months. After the surgery, both babies showed improvement in their respiratory functions, which were marked by their successful weaning from the ventilator in 1 month in Baby A and two months in Baby B. Baby A was discharged two months after surgery, and Baby B was discharged three months after surgery.

3. DISCUSSION

Thoraco-omphalopagus conjoined twins are a rare and complex congenital anomaly, Although there are various accounts of the separation of conjoined twins in the literature.⁸ Surgical separation is still a complex procedure that depends on the conjoining site and the shared organs. It can range from a relatively simple to a highly complex operation, and most of them are life-threatening. Each surgery of conjoined twins has its compelling circumstances. It's success depends on the focuses of the conjoining site, organs shared, and the surgical team's encounter and ability. All these factors make the surgery extend from possible to impossible.⁹

The timing of surgery after SARS-CoV-2 infection should consider the severity of the initial condition, ongoing COVID-19 symptoms; comorbidities and functional status; clinical priorities and risk of disease progression; and the complexity of the operation. The separation of thoraco-omphalopagus conjoined twins is a complex and high-risk procedure. Until now, there are no guidelines that indicate when is the most optimal time for surgery on Thoraco-omphalopagus conjoined twins after SARS-CoV-2 infection.

Literatures have recommended that elective surgery can be done after four weeks post asymptomatic SARS-CoV-2 infection and 6-8 weeks post-symptomatic SARS-CoV-2 infection.¹⁰ The surgical treatment of our reported case was delayed eight weeks post-symptomatic SARS-CoV-2 infection after confirmed negative with SARS-CoV-2 infection with PCR examination and improvement of infection marker. This case shows that separation of thoraco-omphalopagus conjoined twins can be carried out safely after eight weeks after negative SARS-CoV-2 infection was confirmed by PCR, where postoperatively there was no evidence of chronic pulmonary dysfunction. The patients were able to be weaned from the ventilator after the conjoined twin separation procedure. Even though the successful undertaking of separation of our conjoined twins who had SARS-CoV-2 infection is anecdotal, the ability to successfully undertake separation of conjoined twins like that of our reported does require future prospective studies.

4. CONCLUSION

A rare case of thoraco-omphalopagus twins after SARS-CoV-2 infection **h was** successfully separated through the **perspective of cardiothoracic surgeons**.

The complications of SARS-CoV-2 infection could impact **upon** postoperative recovery, and therefore must be considered to plan safe surgery.

CONSENT (WHEREEVER APPLICABLE)

All authors declare that 'written informed **consent was obtained from the parents of the conjoint twins** for publication of this case report and accompanying images. **[the patients cannot talk and cannot give consent, please state clearly who gave you consent to undertake the procedures]**

ETHICAL APPROVAL (WHEREEVER APPLICABLE)

All authors declare that 'written informed consent was **obtained from the parents of the conjoint twins** for publication of this case report and accompanying images.

Acknowledgements -----Please thank individuals as well as groups that helped you with regard to the treatment of your conjoint twins.

REFERENCES

1. Kobylarz K. History of treatment of conjoined twins. *Anaesthesiol Intensive Ther.* 2014;46(2):116–123.
2. Martínez-Frías ML, Bermejo E, Mendioroz J, Rodríguez-Pinilla E, Blanco M, Egüés J, et al. Epidemiological and clinical analysis of a consecutive series of conjoined twins in Spain. *J Pediatr Surg.* 2009 Apr;44(4):811–820.
3. Kaufman MH. The embryology of conjoined twins. *Child's Nerv Syst ChNS Off J Int Soc Pediatr Neurosurg.* 2004 Aug;20(8–9):508–525.
4. Brizot M de L, Liao AW, Lopes LM, Silva MM, Krebs V, Schultz R, et al. [Conjoined twins: prenatal diagnosis, delivery and postnatal outcome]. *Rev Bras Ginecol e Obstet Rev da Fed Bras das Soc Ginecol e Obstet.* 2011 May;33(5):211–218.
5. Mathew RP, Francis S, Basti RS, Suresh HB, Rajarathnam A, Cunha PD, et al. Conjoined twins - role of imaging and recent advances. *J Ultrason.* 2017 Dec;17(71):259–266.
6. WHO Coronavirus (COVID-19) Dashboard With Vaccination Data [Internet]. [cited 2021 Jun 25]. Available from: <https://covid19.who.int/>
7. El-Boghdadly K, Cook TM, Goodacre T, Kua J, Blake L, Denmark S, et al. SARS-CoV-2 infection, COVID-19 and timing of elective surgery: A multidisciplinary consensus statement on behalf of the Association of Anaesthetists, the Centre for Peri-operative Care, the Federation of Surgical Specialty Associations, the Royal College. *Anaesthesia.* 2021 Jul;76(7):940–946. Ammar Omran¹, Mhmmad Nassif^{1, *}, Nabila Salhab¹, Aras Abdo¹, Mohammad Ahmad Almahmod Alkhalil¹, Norma Taishori², and Adnan Dayoub²
8. Hoyle RM. Surgical separation of conjoined twins. *Surg Gynecol Obstet.* 1990 Jun;170(6):549–562.
9. Omran A, Nassif M, Salhab N, Abdo A, Alkhalil M, Taishori N, et al. Early separation of omphalopagus conjoined twins: a case report from Syria. *J Surg case reports.* 2020 Jan 30;2020:rjz374.
10. Bui N, Coetzer M, Schenning K, O'Glasser A. Preparing previously COVID-19-positive patients for elective surgery: a framework for preoperative evaluation. *Perioper Med.* 2021 Dec 1;10- **[provide last page of the article please]**

[9] AMMAR OMRAN¹, MHMMAD NASSIF¹, *, NABILA SALHAB¹, ARAS ABDO¹, MOHAMMAD AHMAD ALMAHMUD ALKHALIL¹, NORMA TAISHORI², AND ADNAN DAYOUB² REFERENCE 9 WRITE THE REFERENCES IN FULL JOURNAL OF SURGICAL CASE REPORTS, 2020;1, 1-3 DOI: 10.1093/JSCR/RJZ374

[7]

CHECK AND CORRECT THE REFERENCES YOU HAVE 2 REFERENBCES UNDER REFERENCE 7

UNDER PEER REVIEW