

## **Case report**

### **KIKUCHI FUJIMOTO DISEASE – A DIAGNOSTIC CHALLENGE**

#### **ABSTRACT**

Kikuchi-Fujimoto Disease is an extremely rare entity characterized by subacute necrotizing lymphadenitis and frequently associated with fever. It is known to have a worldwide distribution with higher prevalence among Japanese and other Asiatic young individuals. The clinical, histopathological and immunohistochemical features appear to point to a viral etiology, a hypothesis that still has not been proven and the cause remains uncertain. It is generally diagnosed on the basis of an excisional biopsy of affected lymph nodes. The diagnosis is crucial as this disease can be mistaken for systemic lupus erythematosus (SLE) or lymphoma.

#### **KEY WORDS**

Necrotising Lymphadenitis, Adults, Asian,

## INTRODUCTION

Kikuchi Fujimoto Disease (KFD) was first reported in Japan almost simultaneously by Kikuchi (1) and Fujimoto (2) in 1972. It is a relatively benign and self-limiting disease that classically presents with lymphadenopathy and fever. ~~It's~~Its etiology is poorly understood, and to our knowledge, ~~it's~~its incidence rates have not been reported, although it is known to be much more prevalent in Asian populations (3). Indeed, a comprehensive literature review of KFD cases in 2003 described it as being “scarce~~ly~~ in the western world” (4). KFD ~~is prevalent in younger population (please give age groups and reference) patients are typically young.~~ Histologically, lymphadenitis is characterized by paracortical lymph node expansion with patchy, well-circumscribed areas of necrosis showing abundant karyorrhectic nuclear debris and absence of neutrophils and eosinophils. The histological differential diagnosis of KFD includes reactive lesions as lymphadenitis associated with Tuberculosis, Histoplasmosis, Leprosy, Syphilis, Infectious mononucleosis, SLE or herpes simplex-, non-Hodgkin's lymphoma, plasmacytoid T-cell leukemia, myeloid tumor and even ~~metastasiemetastatic carcinoma.(carcinoma.~~ (5) Treatment is symptomatic ~~(analgesics-antipyretics, non-steroidal anti-inflammatory drugs and, rarely, corticosteroids).~~ Spontaneous recovery occurs in 1 to 4 months. Patients with Kikuchi-Fujimoto disease need long term follow up to survey the possibility of the development of SLE.

**Comment [U1]:** You should give a better literature review regarding the prevalence starting with the global prevalence, then moving to Asia in general and then the country of interest.

**Formatted:** Highlight

**Comment [U2]:** Remove the bracket and give the various treatment regimens.

## CASE REPORT

A ~~32-year~~32-year male came for consultation with multiple bilateral neck nodules associated with low grade fever for last four months. The size of nodules was increasing slowly and didn't respond to medications prescribed by his physician. On examination the nodules were multiple, non-matted, soft to firm, freely mobile, nontender with largest being of size 2x2 cm. He also had bilateral axillary lymphadenopathy. His systemic examination was within normal limits. He was investigated for possibility of tuberculosis. Complete blood count showed elevated E.S.R. (20 mm at the end of one hour by Wintrobe's method). His X-ray chest revealed (Rt) hilar lymphadenopathy likely of infective origin. The Tuberculin test had induration of 3 mm after 48 hours. With multiple lymphadenopathy/lymphadenopathies, he was referred for USG Abdomen and Pelvis, which ruled out hepatosplenomegaly/hepatosplenomegaly and abdominal lymphadenopathy. (Rt) neck cervical lymph node biopsy was done, two intact nodes were removed and sent for histopathology examination. On gross examination, two whitish rounded 2x1 and 1.5x1 cm soft tissue masses were seen. Cut surface had capsule and uniform whitish areas. No caseation was seen. Histologically the sections showed fibrous capsule and beneath maintained lymphoid architecture (Fig.1-) with paracortical expansion by necrotic areas showing admixture of histiocytes, plasmacytoid dendritic cells, lymphocytes and karyorrhectic debris. (Fig 2,3) There was no evidence of Reed Sternberg cells, granuloma or metastatic deposits. Ziehl Neelsen (ZN) stain was negative for acid fast bacilli. The diagnosis of Lymphadenitis of Kikuchi Fujimoto type was conveyed. On immunohistochemistry (IHC), CD 20 and CD 3 highlighted "B" and "T" lymphocytes, CD 68 histiocytes, CD 123 plasmacytoid dendritic cells and CD 30 highlighted scattered immunoblasts. Ki 67 was 95% in lymphoid

**Comment [U3]:** From which continent

**Comment [U4]:** Add additional history- past medical history, social history and occupational history, medication history and any present medication allergies

**Comment [U5]:**

**Comment [U6]:** What medications and for what duration given

**Comment [U7]:** Elaborate please- go system by system. Write the details even if they are within the normal limits.

**Comment [U8]:** What diagnostic test did you use- pcr?, biopsy staining?

**Comment [U9]:** Add other parameters of the full blood count

**Comment [U10]:** What implicated that it was of infective origin- the morphological findings?

follicles and 15% -in interfollicular areas. Thus, IHC ruled out lymphoma and also confirmed our diagnosis.

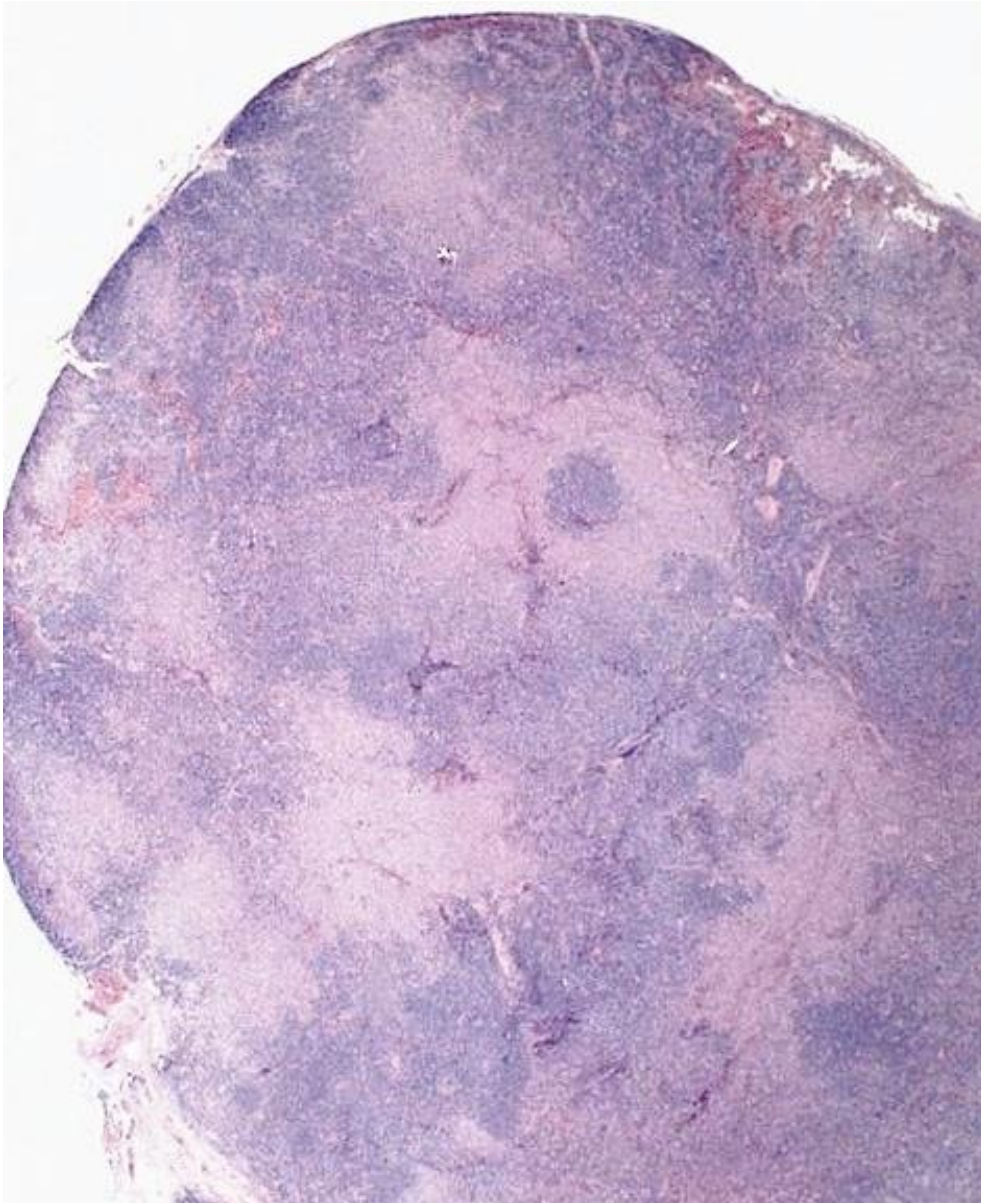


Fig. 1 shows fibrous capsule and beneath lymph node architecture maintained and hyperplastic follicles and dilated sinuses. (H & E 5x X 10x)

Fig. 2 shows areas of necrosis surrounded by inflammatory cells. (H & E 10x X 10x)

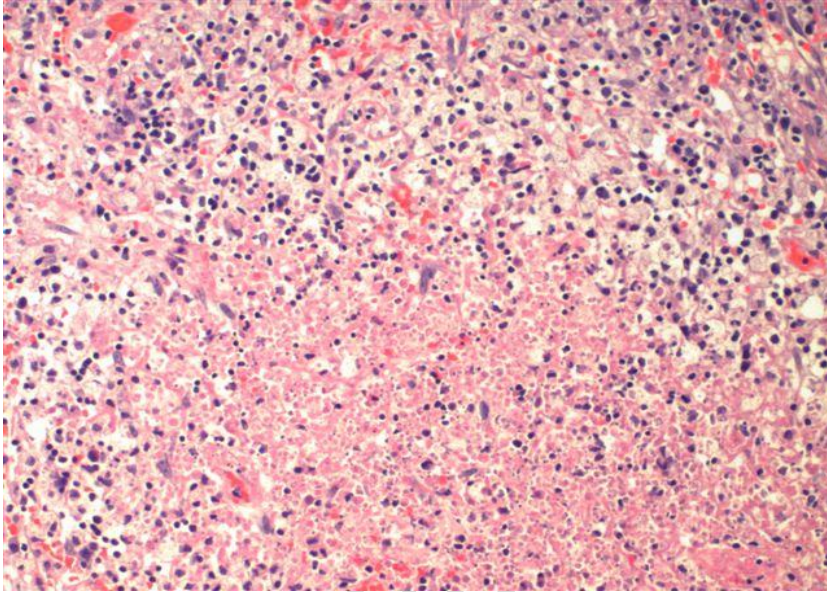


Fig. 3 is the higher magnification of Fig. 2. (H & E 40x X 10x)

### **DISCUSSION**

Kikuchi Fujimoto Disease was discovered in 1972 in Japan by two separate groups. Its exact incidence is unknown, but it is more prevalent in East Asia. Recent reports suggest M : F ratio is closer to 1 : 1 . KFD is often thought of as a disease of the young, with a mean age of diagnosis of 25. (4). The definitive diagnosis of KFD can be made only through lymph node biopsy and histological examination. Even with adequate tissue the lymph node appearances can be mistaken for malignant lymphoma; in one study, 30% of lymph node biopsies in KFD were initially misdiagnosed as lymphoma. The histopathological features of KFD have been classified into three stages: (1) proliferative stage, with expression of histiocytes, plasmacytoid monocytes,

**Comment [U11]:** Write in full form

and lymphoid cells containing karyorrhectic nuclear fragments and eosinophilic apoptotic debris;

(2) [neerotisingnecrotizing](#) stage, with a degree of coagulative necrosis; and (3) xanthomatous stage, with foamy histiocytes predominating. A characteristic and useful diagnostic feature is the

absence of granulocytes in the “[neerotisingnecrotizing](#) stage”, which is helpful in distinguishing

KFD from SLE and drug induced lymphadenopathy. (4,5)

## **CONCLUSION**

Kikuchi-Fujimoto disease poses significant diagnostic challenges to pathologists and clinicians as it can easily be mistaken for other benign lymphadenopathies or infectious lymphadenitis as well as lymphomas. Clinicians' and pathologists' awareness of this disorder can help to avoid misdiagnosis of lymphoma and prevent further expensive and invasive investigations, as well as potentially harmful treatments and psychological stress to the patient. Excisional lymph node biopsy provides the optimal specimen for diagnosis of KFD.

## **REFERENCES**

- 1) Kikuchi M: Lymphadenitis showing focal reticulum cell hyperplasia with nuclear debris and phagocytes: a clinicopathological study. *Acta Hematol Jpn* 1972, 35:379-380.
- 2) Fujimoto Y, Kozima Y, Yamaguchi K: Cervical subacute necrotizing lymphadenitis: a new clinicopathologic entity. *Naika* 1972, 20:920-927.
- 3) Xavier Bosch and Antonio Guilabert. Kikuchi-Fujimoto disease. *Orphanet Journal of Rare Diseases* 2006, 1:18
- 4) Matthew R. Wilson, Gordon Milne, and Evangelos Vryonis. Kikuchi-Fujimoto Disease: A Rare Cause of Fever in the Returning Traveller. *Case Reports in Medicine* Volume 2014, Article ID 868190,
- 5) Anamarija M. Perry, Sarah M. Choi Kikuchi-Fujimoto Disease: A Review *Arch Pathol Lab Med*—Vol 142, November 2018

### **LEGENDS TO FIGURES**

- 1) Fig. 1 shows fibrous capsule and beneath lymph node architecture maintained and hyperplastic follicles and dilated sinuses. (H & E 5x X 10x)
- 2) Fig. 2 shows areas of necrosis surrounded by inflammatory cells. (H & E 10x X 10x)
- 3) Fig. 3 is the higher magnification of Fig. 2. (H & E 40x X 10x)

UNDER PEER REVIEW