

## Case study

Unusual Presentation of Emphysematous Pyelonephritis (EPN): "Double trouble" A Case Report.

### Abstract

Emphysematous Pyelonephritis (EPN) is a possible life-threatening condition that usually presents as sepsis. Delay in identifying the disease may lead to detrimental outcomes, even mortality. The present study reports a case of incidental finding of an EPN in a perforated viscus patient. The study also advocates the minimally invasive approach of percutaneous drainage with antibiotics in asymptomatic EPN patients. A 63-year-old gentleman, with underlying Diabetes Mellitus (DM), initially presented with a sudden onset of severe generalized abdominal pain and distension. Historically, EPN was managed by nephrectomy or open drainage along with antimicrobial therapy but resulted in high mortality of 40-50%. After the introduction of minimally invasive percutaneous drainage, the management shifted towards it and yielded better outcomes. EPN is a fatal disease that requires early detection with a high index of suspicion, particularly in patients with signs of sepsis and pyelonephritis. Although it is rare, in subjects with pneumoperitoneum and the presence of pathology over the renal area, EPN should be one of the differential diagnoses. In this case, it is possible that the presence of EPN poses stress to the patient, leading to the development of a perforated viscus.

Comment [A1]: Lead to detrimental

**Keywords:** Emphysematous Pyelonephritis, Diabetes Mellitus, nephrectomy, mortality

### Introduction

EPN is a possible life-threatening condition that usually presents as sepsis. Delay in identifying the disease may lead to detrimental outcomes, even mortality. However, in rare cases, its presentation diverts its normal clinical picture, masquerading the true pathology. We present a case of incidental finding of an EPN in a perforated viscus patient. We advocate the minimally invasive approach of percutaneous drainage with antibiotics in asymptomatic EPN patients. However, serial radiological reassessment should be carried out to see the resolution of the abscess collection.

Comment [A2]: Lead to detrimental

### Case Report

A 63-year-old gentleman, with underlying Diabetes Mellitus (DM), initially presented with a sudden onset of severe generalized abdominal pain and distension. He was tachycardic and dehydrated. Abdominal examination revealed a distended abdomen with peritonism. Laboratory investigation showed leucocytosis with a WBC of 23.9 with acute kidney injury (AKI) shown by an elevated urea of 11.8 and creatinine of 131. The urine examination showed blood 3+, leucocytes 3+. We proceeded with an Erect Chest X-ray which showed air under the diaphragm. Our initial diagnosis was a perforated viscus with differential diagnoses of perforated gastric ulcer (PGU) / perforated duodenal ulcer (PDU). He was then subjected for operation where he underwent exploratory laparotomy with modified Graham Patch repair for a perforated prepyloric gastric ulcer measuring 2 cm. Intraoperatively, we noted there was a huge retroperitoneal mass measuring 8 cm x 8 cm on the right side, fixed, non-pulsating with no obvious signs of inflammation.

Comment [A3]: and

Comment [A4]: evidenced by

Comment [A5]:

Comment [A6]: perforated hollow viscus

Comment [A7]: measuring 2 cm

Comment [A8]:

Comment [A9]: fixed, non

Postoperatively, the patient had a speedy recovery and was discharged home well.

He was then planned for contrast-enhanced CT of the abdomen and pelvis to investigate the retroperitoneal mass. CECT of the abdomen and pelvis revealed features suggestive of right EPN with a large

perinephric abscess measuring 9.2x6.7x10.9cm and bilateral ureteric calculi as portrayed in Figure 1. We proceeded with ultrasound guided percutaneous drainage and thick pus was aspirated and sent for cultures. The pus culture grew Extended Spectrum  $\beta$ -Lactamase Klebsiella Pneumoniae. He had uneventful recovery afterwards, however the pigtail catheter meant for pus drainage prematurely dislodged. A repeat ultrasound revealed residual decreasing size collection. He was planned for conservative management with antibiotic and frequent visits to surgical outpatient clinic. His latest visit was unremarkable and showing good recovery.

### Discussion

EPN is defined by severe necrotizing and gas forming infection of the renal parenchyma and its surrounding structure namely perinephric tissue and collecting system (1,2). The first documented case of EPN was described in 1898 and the term EPN coined in 1962 to correlate between acute kidney infection with gas forming condition(1).

The incidence for female is more common than men, with mean age of 40-50 years old(2). It had been reported that left kidney is affected more than right without apparent explanation(2). Usually, it presented with sepsis and pyelonephritis signs such as fever with rigor, lumbar pain and urinary tract infection symptoms(3). However, in some extreme cases, peritonitis with pneumoperitoneum suggested of perforated viscus had been reported (6,7). This results from the extension of the disease into the peritoneum. This unique presentation is a red - herring resulting in different approach in managing the disease. However, in our case the patient presented with peritonitis secondary to perforated gastric ulcer with incidental finding of EPN. This caused a diagnostic dilemma and difficulty in managing this case.

Most EPN is associated with immunocompromised state particularly diabetes mellitus where its occurrence in diabetic patients accounts more than 95% of all EPN cases(4)(5). Besides, urinary tract obstruction also predispose patients to develop EPN(4).

Since 1984, multiple classification system developed in order to aid in managing the disease as illustrated in Table 1. The latest composition by Huang et al had provide objective means in treating EPN(5).

Author	Radiological modality	Class
Michaeli et al(6)	Plain x-ray with intravenous urography	I : Gas in the parenchyma or perinephric tissue
		II : Gas in the kidneys and its surroundings
		III : Gas through fascia or bilateral kidney involvement
Wan et al(7)	CT scan	I : Renal necrosis with presence of gas but no fluid
		II : Gas at parenchyma with fluid in renal parenchyma, perinephric space or collecting system
Huang et al(4)	CT scan	1. Gas only in collecting system
		2. Gas at parenchymal only
		3A. Perinephric space involvement
		3B. Pararenal space involvement
		4. Bilateral kidney involvement of in solitary kidney patient

**Comment [A10]:** Renal or perinephric fluid collection associated with gas in the collecting system.

**Comment [A11]:** Gas only in renal parenchyma

**Comment [A12]:** Bilateral kidney involvement or solitary kidney with EPN

EPN is a devastating condition that bears high risk of morbidity and mortality mainly due to septic complications. Variety of risk factors identified to prognosticate the outcome of the illness. The meta-analysis had concluded several factors including patient whom treated conservatively, type 1 EPN, bilateral EPN and patient with low platelet (thrombocytopenia)(8).

The diagnosis of EPN is radiological supported by the presenting history and laboratory investigations(7). Although plain radiograph may showed presence of air near the kidney, the gold standard modality in diagnosing EPN is undoubtedly CT scan(9). CT scan yield 100% accuracy compared to plain radiograph which only positive up till 69% of the cases(9).

Historically, EPN was managed by nephrectomy or open drainage along with antimicrobial therapy but resulted in high mortality of 40-50%(6). After the introduction of minimally invasive percutaneous drainage, the management shifted towards it and yield better outcome. A systematic review advocated percutaneous drainage as the initial management of EPN whereas it is associated with reduced in mortality comparing to emergency nephrectomy or medical management however, nephrectomy may be required in some cases not responded to the aforementioned treatment(9). Figure 2 demonstrate the management algorithm extracted from Huang et al(5).

Referring to our case, as patient was asymptomatic, percutaneous drainage with medical management were the treatment of choice. Radiological imaging repeated after one month showed improvement. Chen et al had concluded that imaging should be repeated after 4-7 weeks and from their cohort, the treatment lasted for approximately 3 months(10). Patient was follow up till 10 years with mean of 5 years (follow up till clinically and radiologically resolved) showed no recurrence or complications(10). In cases whom not responded to percutaneous drainage, nephrectomy should be considered(4). As EPN is a rare occurrence, there is limited consensus pertaining to the treatment of incidental finding of EPN during an exploratory laparotomy. However, a safer approach must be undertaken to avoid causing more harm to the patients particularly in asymptomatic patients. Open drainage with posterior approach (flank incision) is one of the method of choice(11).

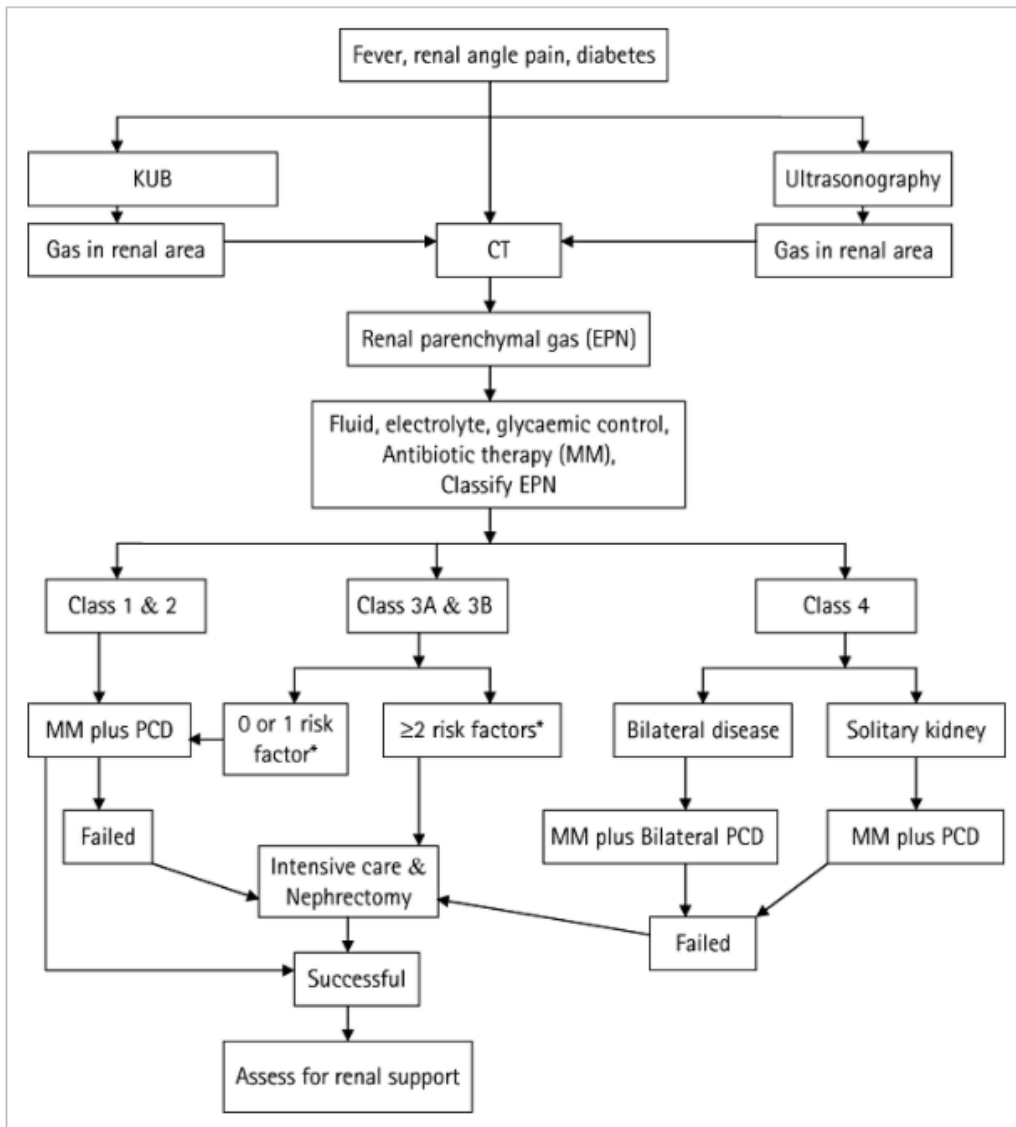


Figure 2: Management algorithm of EPN. (Risk factors: Diabetes, thrombocytopenia, acute kidney injury, altered sensorium, shock)

### Conclusion

EPN is a fatal disease that required early detection with high index of suspicion particularly in patient with signs of sepsis and pyelonephritis. Although it is rare, in subjects with pneumoperitoneum and the presence of pathology over renal area, EPN should be one of the differential diagnosis. In this case, it is possible that the presence of EPN poses stress to the patient leading to development of perforated viscus.

## References

1. Schultz EH, Klorfein EH. Emphysematous pyelonephritis. *J Urol*. 1962;87(6):762–6.
2. Misgar R, Mubarik I, Wani A, Bashir M, Ramzan M, Laway B. Emphysematous pyelonephritis: A 10-year experience with 26 cases. *Indian J Endocrinol Metab*. 2016;20(4):475–80.
3. H J Tang, C M Li, M Y Yen, Y S Chen, S R Wann, H H Lin, S S Lee YCL. Clinical characteristics of emphysematous pyelonephritis. *J Microbiol Immunol Infect*. 2001;34(2):125–30.
4. Jeng-Jong Huan C-CT. Emphysematous pyelonephritis. *Japanese J Clin Urol*. 2011;65(1):23–9.
5. Ubee SS, McGlynn L, Fordham M. Emphysematous pyelonephritis. *BJU Int*. 2011;107(9):1474–8.
6. Michaeli J, Mogle P, Perlberg S, Heiman S, Caine M. Emphysematous pyelonephritis. *J Urol*. 1984;131(2):203–8.
7. Wan YL, Lee TY, Bullard MJ, Tsai CC. Acute gas-producing bacterial renal infection: Correlation between imaging findings and clinical outcome. *Radiology*. 1996;198(2):433–8.
8. Falagas ME, Alexiou VG, Giannopoulou KP, Siempos II. Risk Factors for Mortality in Patients With Emphysematous Pyelonephritis: A Meta-Analysis. *J Urol*. 2007;178(3):880–5.
9. Somani BK, Nabi G, Thorpe P, Hussey J, Cook J, N'Dow J. Is Percutaneous Drainage the New Gold Standard in the Management of Emphysematous Pyelonephritis? Evidence From a Systematic Review. *J Urol*. 2008;179(5):1844–9.
10. Chen MT, Huang CN, Chou YH, Huang CH, Chiang CP, Liu GC. Percutaneous drainage in the treatment of emphysematous pyelonephritis: 10-Year experience. *J Urol*. 1997;157(5):1569–73.
11. Hayashi T, Yanaihara H, Kaguyama H, Hanashima F, Sakamoto H, Nakahira Y, et al. Emphysematous pyelonephritis with successful renal preservation using open drainage surgery: A case report. *Urol Case Reports*. 2018;17:76–8.