

Potential Therapeutic Effect of Bee Venom on Cisplatin-Induced Hepatotoxicity

ABSTRACT

The fact that cisplatin (CIS) can induce hepatotoxicity has limited its therapeutic uses, although it is recognised as a highly potent antineoplastic drug. Bee venom (BV) is an important toxin that exerts a potent anti-inflammatory effect and demonstrates significant pharmacological activities. The aim of this research was to investigate the therapeutic impact of BV administration orally on CIS-induced hepatotoxicity in a rat model when compared with individual drug therapy. Thirty albino male rats were used in this study. The rats were classified into three groups, each with ten rats ($n = 10$). The control group was group I, while groups II and III got CIS (a single dose of 7.5 mg/kg interperitoneally). After 24 hours, group III received BV (1 mg/kg orally), which was then administered daily for four weeks. The rats' serum liver functions were estimated. The oxidative stress, antioxidant status, inflammatory mediators and fibrogenic and apoptotic markers were determined in the liver tissues. The results revealed that the administration of CIS induced a significant elevation in the serum aspartate aminotransferase, alanine aminotransferase and bilirubin levels, which was associated with a decrease in the albumin level. Additionally, significant increases in the hepatic tissue malondialdehyde, tumor necrosis factor alpha, interferon gamma, transforming growth factor beta, fibronectin and caspase-3 levels were noted. Moreover, significant decreases in the superoxide dismutase and catalase activities as well as the glutathione level were detected in the hepatic tissues. The administration of BV resulted in the notable amelioration of the aforementioned parameters. Interestingly, these parameters were restored to almost normal levels following administration of CIS and BV. The histopathological investigation revealed multiple focal inflammation sites that appeared to be associated with hepatic necrosis in the hepatic tissues of the CIS-treated rats. The co-administration of BV preserved the normal architecture of the hepatic tissues. These results indicate that the co-administration of BV exerts potent anti-hepatotoxic and cytoprotective effects by combating oxidative stress, inflammation, fibrogenic and apoptotic markers and histopathological changes. Thus, this study provides strong evidence of the superiority of combination drug therapy when compared with individual drug therapy.

Keywords: Bee Venom, Cisplatin, Hepatotoxicity

INTRODUCTION

Cisplatin (CIS) is a platinum-based antineoplastic agent that is used to treat a variety of solid organ tumours, including testis, ovary, urinary bladder, head and neck, brain and lung tumours (1). Despite its potent antineoplastic effect, the toxic side impacts of CIS during therapy, for example, neurotoxicity, ototoxicity, nephrotoxicity,

hepatotoxicity and myelosuppression, limit its clinical uses (2). CIS is a small molecule capable of crossing the plasma membrane and entering the nucleus with ease. Once inside the nucleus, CIS induces changes to the DNA molecule's structure. Inter- and intra-chain adducts among CIS and the nitrogen bases of the DNA cause such changes (3). Prior studies that have investigated the relationship between the CIS

dose and the toxic side effects of the drug have generally found evidence of correlation between the cumulative CIS dose and its toxic side effects. This correlation has been found to be particularly prominent in relation to the liver and hematopoietic system. Interestingly, it has been shown that hepatotoxicity can develop after either a single dose or low repeated doses of CIS (4). The exact mechanism behind CIS-induced hepatotoxicity is not yet fully understood (5). However, the most widely recognised mechanisms involve the shifting of the antioxidant balance toward oxidative stress, the acceleration of apoptosis and the elevated expression of proinflammatory cytokines (2). There are no proven hepatoprotective agents for combatting CIS-induced hepatic injury, and only symptomatic treatments are currently available. Given the significant limitations of conventional therapy, the use of complementary and alternative therapies represents a potentially valuable alternative strategy. Bee venom (BV), which is also known as apitoxin, is used by bees for self-defence purposes. BV is extracted from honeybees and is widely employed in conventional Chinese medicine to alleviate pain and treat inflammatory diseases. It is believed to be a highly complex mixture of at least 18 active ingredients, which include active peptides, melittin, apamin, adolapin (6), and amines containing histamine, catecholamines, polyamines, melittin and phospholipase A2 (7). Melittin is the main ingredient of BV, accounting for roughly half of its dry weight (8). BV was used to treat a variety of inflammatory diseases (e.g. rheumatoid arthritis), and it is known to exert strong immune modulatory effects (9). The injection of BV has been found to result in the pronounced inhibition of leukocyte migration as well as a substantial decrease in the concentration of tumour necrosis factor (TNF) in mice (10). Additionally, BV exerts a curative effect in relation to oxidative stress induced by gamma irradiation (11). Moreover, BV has been reported to possess several biological properties, such as neuro- and hepatoprotective properties (12). Therefore, the present study sought to investigate the hepatic protective effect of BV through examining its effects on oxidative stress, inflammatory markers and the expression of both apoptotic and profibrotic markers in a rat model of CIS-induced hepatotoxicity.

2. MATERIALS AND METHODS

2.1 Chemicals

The CIS used in the present study was purchased from Toronto Research Chemicals, Canada. It was dissolved in 0.9% phosphate-

buffered saline (PBS). A single dose (7.5 mg/kg) was administered interperitoneally. The melittin BV was also purchased from Toronto Research Chemicals, Canada. A dose of 1 mg/kg was administered orally (gavage) using a metal orogastric tube. All the other chemicals and reagents were analytical grade and came from well-known commercial sources.

2.2 Animals

In this research, thirty male albino rats (weighing 200±250g) were used. The rats were obtained from the King Fahd Medical Research Centre's Animal House Colony in Jeddah. In a temperature-controlled room (25 + 2°C), the rats have been kept on a 12:12 light/dark cycle. At the King Fahd Medical Research Center's Animal Facility Breeding Colony, the rats had ad libitum access to food and water. The King Fahd Medical Research Centre's Ethical Committee accepted all of the methods used in this study. KSA's Jeddah. Number of approvals (163-19). Moreover, they all adopted the National Institutes of Health's Guide for the Care and Usage of Laboratory Animals guidelines (Publication No. 85-23, revised 1985).

2.3 Animal grouping and treatments

The 30 male rats were randomised into three groups (n = 10 rats per group). Only 0.9 % PBS was given to rats in group I (normal control). The rats in group II (hepatotoxic control) received CIS (7.5 mg/kg body weight) according to the procedure described by El-kott et al. (13). The rats in group III were administered 1 mg/kg/day BV after having received CIS. The treatment in this group lasted for 30 days. The BV was administered orally once per day using an orogastric tube, and throughout the experiment, the rats were given unrestricted access to food and water.

The rats have been fasted overnight and then anaesthetized with urethane (1.4 ml/kg) at the conclusion of the experiment (i.e. after 30 days). Blood samples were collected via the retro-orbital venous plexus and then centrifuged at 3000 x g for 15 minutes at 4°C using a Heraeus Multifuge X3R. The sera were stored at -20°C as aliquots. All of the rats were quickly sacrificed, and each rat's liver was extracted by means of dissection. Part of each harvested liver was homogenised in nine volumes of 0.1 M potassium phosphate-buffered saline at pH 7.4 in a Potter-Elvehjem homogeniser to reach a final concentration of 10% w/v. A cooling centrifuge was used to centrifuge the homogenates at 2000 rpm for 20 minutes (Hitachi, Japan). The aliquots of supernatant were stored at -20°C for the

biochemical assays. The other part of each liver was stored in 10% formalin-saline at 40°C before being processed for the histopathological investigation.

2.4 Biochemical analysis Liver function biomarkers

The levels of serum alanine aminotransferase (ALT) and aspartate aminotransferase (AST) were determined using Reitman and Frankel's method (14). The serum albumin concentration was determined calorimetrically according to the method described by Doumas et al. (15), while the total serum bilirubin concentration was evaluated according to the method reported by Walter and Gerade (16).

Oxidative stress markers

The lipid peroxidation (MDA) level in each liver sample was estimated using the method defined by Placer et al. (17). In addition, the hepatic reduced glutathione (GSH) level was evaluated using the method reported by Ellman (18). The determination of the hepatic superoxide mutase (SOD) activity was performed using the method defined by Nishikimi et al. (19), while the hepatic catalase (CAT) activity was measured according to the method reported by Aebi (20).

Hepatic proinflammatory cytokines and profibrogenic and apoptotic biomarkers

The hepatic tumour necrosis alpha (TNF- α), interferon gamma (IFN- γ), fibronectin (FN) and caspase-3 (CAS-3) levels were determined by means of enzyme-linked immunosorbent assays (ELISAs) according to the methods reported by Kitaura et al. (21), Tamaoki et al. (22), Sommandas et al. (23) and Colak et al. (24), respectively. The assays were performed using commercial ELISA kits (Bioassay Technology Laboratory, China) and a microtiter plate reader (Fisher Biotech, Germany).

Histopathological investigation

The liver samples have been fixed in 10% formol-saline, embedded in paraffin, and partitioned using a microtome (5- μ m thick) (Leica, Berlin, Germany). Hematoxylin and eosin solution were used to stain the sections, which were mounted on glass slides. A light microscope was then used to examine them.

2.5 Statistical analysis

The mean \pm standard error (SE) of the mean was used to express all of the findings. The data have been analysed using the Statistical Package for the Social Sciences (SPSS) version 11 and a one-way analysis of variance (ANOVA). The significance among the groups was also

compared using Duncan's post-hoc test. When $P < 0.05$, a difference was deemed significant.

3. RESULTS

3.1 Effect of BV administration on the liver function biomarkers

The administration of 7.5 mg/kg b.w. CIS induced significant elevations in the serum ALT (290.7%) and AST (164.9%) activities (Fig. 1) as well as in the total bilirubin level (417.8%). Moreover, a significantly decreased albumin level (42%) was noted when compared with the level in the control group (Fig. 2). In addition, the treatment of the CIS-intoxicated rats with 1 mg/kg b.w. BV resulted in a protective effect in relation to the CIS-induced liver injury as well as in significantly attenuated serum ALT, AST and total bilirubin levels. Further, a significantly increased albumin level was noted when compared with the CIS group (group II), likely due to the antioxidant effect of the BV.

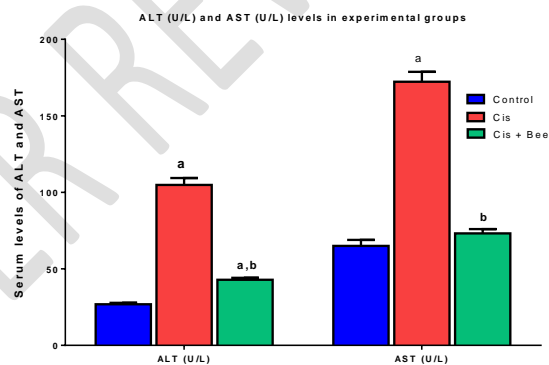


Figure (1): Comparison of the serum ALT (U/L) and AST (U/L) levels of the different studied groups. Data are expressed as the mean \pm SE of the mean. (a): significance versus control; (b): significance versus CIS. Significance was determined using a one-way ANOVA (LSD) test ($p < 0.05$).

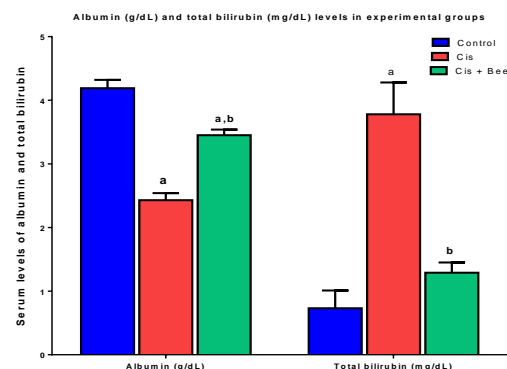


Figure (2): Comparison of the serum albumin (g/dl) and total bilirubin (mg/dl) levels of the

different studied groups. Data are presented as the mean \pm SE. (a): significance versus control; (b): significance versus CIS. Significance was determined using a one-way ANOVA (LSD) test ($p < 0.05$).

A significant increase was noted in the hepatic MDA levels (145.8%) (Fig. 3) following the administration of CIS, which was associated with a significant decrease in the hepatic SOD (-77.6%) (Fig. 3), CAT (-64.6%) and GSH (-35.6%) (Fig. 4) levels when compared to the control group. However, BV administration led to a significant improvement in the hepatic MDA levels as well as significantly restored SOD, CAT and GSH levels when compared with the CIS-induced hepatotoxicity.

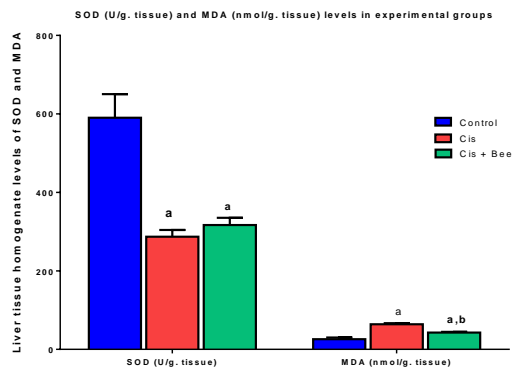


Figure (3): Comparison of the liver tissue homogenate SOD (U/g. tissue) and MDA (nmol/g. tissue) levels of the different studied groups. Data are presented as the mean \pm SE. (a): significance versus control; (b): significance versus CIS. Significance was determined using a one-way ANOVA (LSD) test ($p < 0.05$).

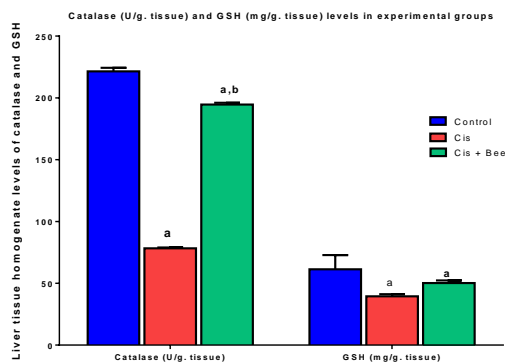


Figure (4): Comparison of the liver tissue

homogenate catalase (U/g. tissue) and reduced glutathione (GSH) (mg/g. tissue) levels of the different studied groups. Data are presented as the mean \pm SE. (a): significance versus control; (b): significance versus CIS. Significance was determined using a one-way ANOVA (LSD) test ($p < 0.05$).

3.2 Anti-inflammatory, antifibrogenic and antiapoptotic effects of BV

Significant upsurges in the hepatic TNF α , IFN- γ (Fig. 5), FN (Fig. 6A) and CAS-3 (Fig. 6B) levels (114.4%, 106.6%, 107.5% and 97.8%, respectively) were observed following the CIS treatment when compared with the control group. Moreover, the rats that were treated with BV showed a significant reduction in their TNF- α , IFN- γ , FN and CAS-3 levels when compared with the CIS-treated rats.

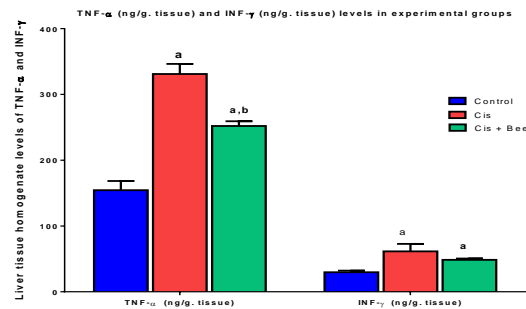


Figure (5): Comparison of the liver tissue homogenate tumour necrosis factor (TNF)- α (ng/g. tissue) and interferon (INF)- γ (ng/g. tissue) levels of the different studied groups. Data are presented as the mean \pm SE. (a): significance versus control; (b): significance versus CIS. Significance was determined using a one-way ANOVA (LSD) test ($p < 0.05$).

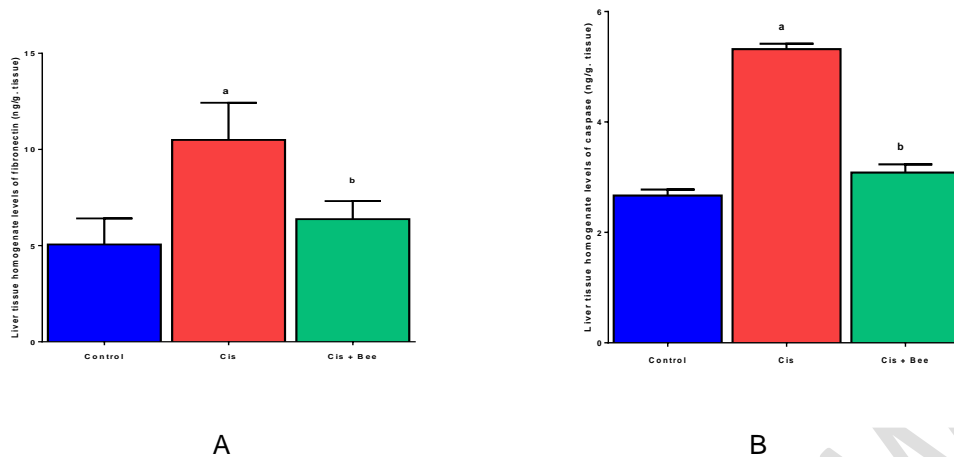


Figure (6): Comparison of the liver tissue homogenate (A) fibronectin (ng/g. tissue) and (B) caspase-3 (ng/g. tissue) levels of the different studied groups. Data are presented as the mean +/- SE. (a): significance versus control; (b): significance versus CIS. Significance was determined using a one-way ANOVA (LSD) test ($p < 0.05$).

3.3 Histopathological investigation

The hepatic tissue of the normal (control) rats showed a normal histological structure (Fig. 7A). The rats that were treated with CIS showed multiple focal inflammation sites that appeared to be randomly distributed aggregates of the inflammatory cells. The infiltrating cells were

predominantly lymphocytes. The inflammatory cell aggregates were accompanied by hepatocellular necrosis (Fig. 7B). The rats that received BV exhibited regular hepatic cords and decreased sinusoidal dilatation with an apparently normal portal area (Fig. 7C).

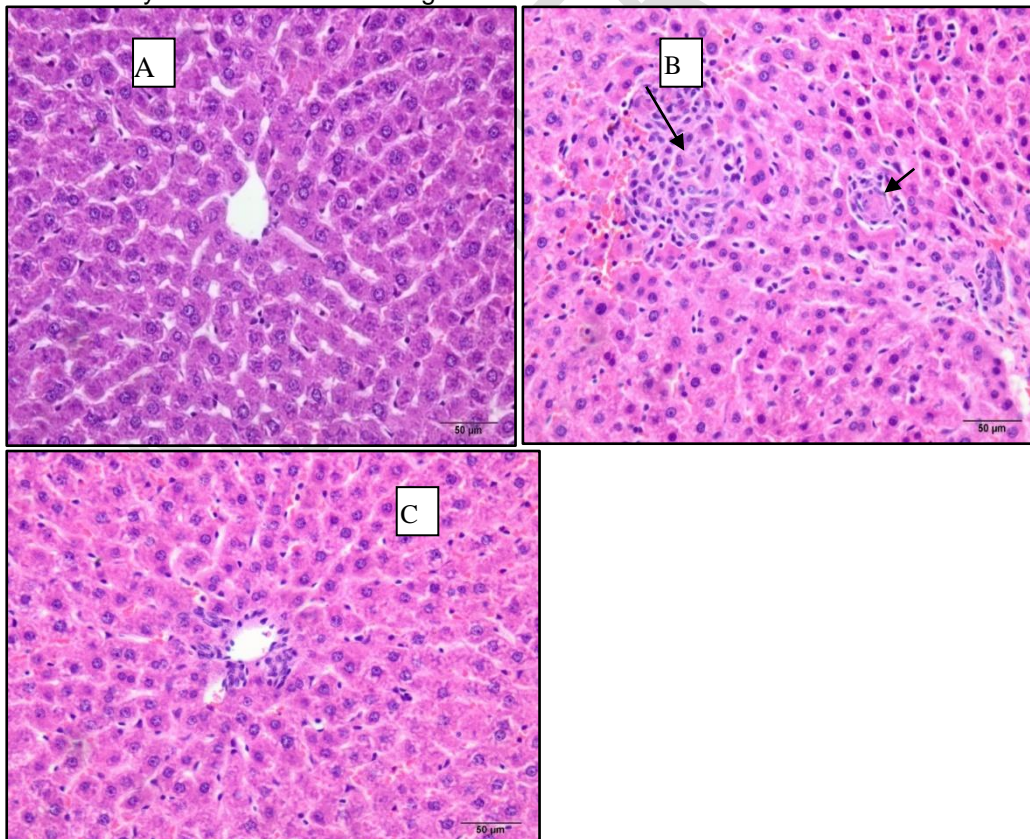


Figure (7): Histopathological examination of the liver tissue of normal rats showing a normal structure (A). Rats with CIS-induced liver toxicity showed multiple focal inflammation sites that appeared to be randomly distributed aggregates of the inflammatory cells. The inflammatory cell aggregates were accompanied by hepatocellular necrosis (arrows) (B). Rats treated with BV showed regular hepatic cords and decreased sinusoidal dilatation with an apparently normal portal area (C). Bar = 50 µm.

4. DISCUSSION

CIS is one of the most active cytotoxic agents with regard to cancer, although it is associated with several toxicities. For instance, hepatotoxicity has been found to occur following high doses of CIS (25), while some studies have reported that hepatotoxicity may also occur following a single dose or low prolonged doses of CIS (26). The present study sought to elucidate the potential protective actions of BV against hepatic injury to rats caused by CIS.

In this study, a single dose of CIS (7.5 mg/kg) was used to induce hepatotoxicity, as manifested by increases in the serum ALT and AST levels as well as the total bilirubin level, which are known to be associated with a decrease in the serum albumin level. The results of this study were in agreement with those of several previous studies (27,28). The hepatic enzymes AST and ALT as well as bilirubin are commonly used as markers of liver function, and the observed increases in these markers in the blood indicated the impairment of liver function and the presence of hepatic lesions (29). A prior study reported a marked elevation in the hepatic enzymes AST and ALT in rats following a single injection of CIS and attributed it to damage to the hepatocytes and the subsequent leakage of enzymes into the circulation (30). By oxidizing a variety of hepatic mitochondrial ingredients, which include protein sulfhydryl groups, CIS can cause mitochondrial membrane rigidification and energetic metabolism weakness. This interference stems from the ability of CIS to increase the permeability of the mitochondrial inner membrane. This may be attributed to the lipid peroxidation caused by CIS, as well as the development of free radicals, that leads to oxidative stress, which has been identified as one of the pathogenic mechanisms behind CIS's liver side effects (31). The administration of CIS caused a significant decrease in the serum albumin level. This may be attributed to the impaired synthesis of albumin in liver, which could be attributed to hepatocyte inefficiency and/or a decline in amino acid levels in the blood (32).

Following treatment with BV, the hepatotoxicity caused by CIS was reversed in the current research. This was evaluated on the basis of significant decreases in the levels of the liver markers ALT, AST and serum bilirubin, as well as a significant increase in the serum total bilirubin level, when compared with the group that had been treated solely with CIS. The hepatoprotective effect of the BV was attributed to the inhibition of the secretion of pro-

inflammatory cytokines (33) as well as the presence of PLA₂, which has a potent hepatoprotective effect (34). Thus, BV has been found to decrease the elevated serum aminotransferase enzyme levels and restore the serum protein levels in different models of induced hepatic injury (33).

The equilibrium between the production and removal of oxidants is disrupted by oxidative stress. This can result from either an excess level of oxidants generated in the body or a lack of antioxidant defence mechanisms, which is most commonly shown in relation to chemotherapy regimens, particularly those involving CIS treatment (35). The administration of CIS resulted in a significant elevation in the hepatic tissue lipid peroxide level, which is associated with the significant depletion of antioxidant markers, as indicated by the decreased levels of SOD, CAT and GSH. This impact could be a by-product of the CIS-induced rise in free radical production and/or decrease in lipid peroxidation, which protects enzymes. Hydrogen peroxide, superoxide anions, and hydroxyl radicals are examples of oxygen free radicals that can be generated by CIS. The hydroxyl radicals in membrane lipids are capable of extracting hydrogen atoms from polyunsaturated fatty acids to initiate lipid peroxidation. By interacting with macromolecules like membrane lipids, proteins, and nucleic acids, these radicals can provoke significant tissue damage (36). This alteration in the enzymatic antioxidant status suggests that enzymes have a significant role in combating tissue oxidative stress caused by free radicals. Yet, the administration of BV resulted in the significant amelioration of the oxidative stress status of hepatic tissue, as demonstrated by a substantial decrease in hepatic MDA levels, as well as the significant upregulation of the hepatic antioxidant enzymes and GSH activities. Petricevich (37) reported that BV triggered the release of nitric oxide, which protects cells from oxidative stress. As BV is composed of a mixture of active materials such as enzymes (hialuronidase, phospholipases), peptides (melittin, mastoparans, apamin, bombolitins), and low molecular weight compounds (biogenic amines, lipids, carbohydrates, acetylcholine, free amino acid), a variety of reactions could result in the production of inflammatory mediators including cytokines and nitric oxide (38).

The present study revealed a significant upsurge in the proinflammatory cytokines and profibrogenic and apoptotic markers, as evidenced by the upregulation in the hepatic tissue of TNF- α , IFN- γ , FN and Cas-3 following

the administration of CIS. CIS causes a major inflammatory response in the liver tissue, as evidenced by an increase in the proinflammatory cytokines, TNF- α and IFN- γ (39). TNF- α , in turn, exacerbates hepatic tissue inflammation by activating other cytokines and causing immune cell chemotaxis (40). Moreover, the binding of TNF- α to its receptor results in the formation of two sequential complexes (39). Complex I causes the transcription factors nuclear factor-kappa B (NF- κ B) and activator protein-1 to become activated quickly, whereas complex II leads to the formation of the death-inducing signalling complex and, ultimately, to caspase-dependent apoptosis (41). Further, Sharp et al. (42) reported that mice treated with a repeated dosing regimen of CIS exhibited increased transforming growth factor- β (TGF- β) and fibronectin levels, which suggested a robust fibrotic phenotype. Meanwhile, rats treated with BV showed the significant amelioration of the aforementioned parameters. This anti-inflammatory effect on the part of BV could be attributed to melittin, which is the major component of BV. Lee et al. focused on the protective effect of melittin in vitro and in vivo against induced inflammatory responses (43). In addition, Park et al. (44) discovered that melittin reduces hepatic damage, inflammation and hepatic fibrosis. Melittin suppresses TNF- α secretion as well as IL-1 β and IFN γ expression in TNF- α -treated hepatic stellate cells (HSCs). Moreover, by hindering the NF- κ B signalling pathway, it decreases inflammation and fibrosis. It also inhibits NF- κ B from binding to DNA and activating its promoter, implying that melittin inhibits hepatocyte apoptosis by inhibiting of NF- κ B activation (45).

5. CONCLUSION

The results of the present study indicate that BV exerts potent antihepatotoxic and cytoprotective effects by affecting several pathways. The pleiotropic effects of BV on oxidative stress, inflammation as well as fibrotic and apoptotic regulation indicates that it may be a possibly effective agent in hepatotoxicity treatment.

Based on the results of this study, it is believed that a combination of treatment with BV and conventional medicine could prove to be therapeutically beneficial and also serve to minimise the adverse effects of treatment. Further studies are required to confirm the beneficial effects of BV prior to its widespread clinical use.

COMPETING INTERESTS DISCLAIMER:

Authors have declared that no competing interests exist. The products used for this research are commonly and predominantly use products in our area of research and country. There is absolutely no conflict of interest between the authors and producers of the products because we do not intend to use these products as an avenue for any litigation but for the advancement of knowledge. Also, the research was not funded by the producing company rather it was funded by personal efforts of the authors.

REFERENCES

1. Cure MC, Cure E, Kalkan Y, Kırbaş A, Tümkaya L, Yılmaz A, Türkyılmaz AK, Şehitoğlu İ and Yüce S: Infliximab modulates cisplatin-induced hepatotoxicity in rats. *Balkan Med J.* 33:504–511. 2016
2. Karale S and Kamath JV: Effect of daidzein on cisplatin-induced hematotoxicity and hepatotoxicity in experimental rats. *Indian J Pharmacol.* 49:49–54. 2017
3. Hah SS, Stivers KM, de Vere RW, Henderson PT: Kinetics of carboplatin – DNA binding in genomic DNA and bladder cancer cells as determined by accelerator mass spectrometry. *Chem Res Toxicol.* 19: 622-626.2006
4. Astolfi L, Ghiselli S, Guaran V, Chicca M, Simoni E, Olivetto E, Lelli G and Martini A: Correlation of adverse effects of cisplatin administration in patients affected by solid tumours: A retrospective evaluation. *Oncol Rep.* 29:1285–1292. 2013
5. Kalcioğlu MT, Kizilay A, Gulec M, Karatas E, Iraz M and Akyol O. The protective effect of erdosteine against ototoxicity induced by cisplatin in rats. *Eur Arch Otorhinolaryngol.* 262(10):856–63. 2005
6. Kwon YB, Ham TW, Kim HW, Roh DH, Yoon SY, Han HJ, Yang IS, Kim KW, Beitz AJ, Lee JH. Water soluble fraction (< 10 kDa) from bee venom reduces visceral pain behavior through spinal α 2-adrenergic activity in mice. *Pharmacology Biochemistry and Behavior.* 1;80(1):181-7. 2005
7. Oršolić N. Bee venom in cancer therapy. *Cancer and Metastasis Reviews.* 1;31(1-2):173-94. 2012
8. Vogel H. Incorporation of melittin into phosphatidylcholine bilayers: study of binding and conformational changes. *FEBS letters.* 2;134(1):37-42. 1981

9. Park MH, Choi MS, Kwak DH, Oh KW, Yoon DY, Han SB, Song HS, Song MJ, Hong JT. Anti-cancer effect of bee venom in prostate cancer cells through activation of caspase pathway via inactivation of NF- κ B. *The Prostate*. 1;71(8):801-12. 2011
10. Kwon YB, Kim HW, Ham TW, Yoon SY, Roh DH, Han HJ, Beitz AJ, Yang IS, Lee JH. The anti-inflammatory effect of bee venom stimulation in a mouse air pouch model is mediated by adrenal medullary activity. *Journal of neuroendocrinology*. 15(1):93-6. 2003
11. Elshater AE, Mohi Eldin MM, Salman M, Kasem NR. The curative effect of bee venom and propolis on oxidative stress induced by γ -irradiation on blood and tissues of rats. *Egyptian Academic Journal of Biological Sciences. C, Physiology and Molecular Biology*. 1;6(1):53-69. 2014
12. Khalil WK, Assaf N, ElShebiney SA, Salem NA. Neuroprotective effects of bee venom acupuncture therapy against rotenone-induced oxidative stress and apoptosis. *Neurochemistry international*. 1;80:79-86. 2015
13. El-Kott AF, Mohanny KM. The pharmaceutical impacts of honeybee venom against thioacetamide -induced hepatic fibrosis in rats. *Advances in Life Science and Technology*. 31;85-93. 2015
14. Reitman S, Frankel S. The colorimetric method for determination of serum glutamic oxaloacetic transaminase and serum glutamic pyruvic transaminase. *Am. J. Clin. Pathol*. 28, 56–63. 1957.
15. Doumas BT, Watson WA, Biggs HG. Albumin standards and the measurement of serum albumin with bromocresol green. *Clinica chimica acta*. 1;31(1):87-96. 1971
16. Walter M, Gerade H. Colourimetric method for estimation of total bilirubin. *Microchem*. 15:231. 1970
17. Placer ZA, Cushman LL, Johnson BC. Estimation of lipid peroxidation (malondialdehyde) in biochemical systems. *Anal. Biochem*. 16, 359–365. 1966.
18. Ellman GL. Tissue sulfhydryl groups. *Arch. Biochem. Biophys*. 82, 70–77. 1959
19. Nishikimi M, Roa NA, Yogi K. Measurement of superoxide dismutase. *Biochem. Biophys. Res. Commun*. 46:849-54. 1972
20. Aebi H. [13] Catalase in vitro. In *Methods in enzymology*. Academic Press. (Vol. 105, pp. 121-126). 1984
21. Kitaura H, Sands MS, Aya K, Zhou P, Hirayama T, Uthgenannt B. Marrow stromal cells and osteoclast precursors differentially contribute to TNF-alpha induced osteoclastogenesis in vivo. *J. Immunol*. 173, 4838–4846. 2004.
22. Tamaoki J, Kondo M and Kohri K. Macrolide antibiotics protect against immune complex-induced lung injury in rats: role of nitric oxide from alveolar macrophages. *J Immunol* 163:2909–2915 (1999)
23. Sommandas V, Rutledge EA and Van Yserloo B. Aberrancies in the differentiation and maturation of dendritic cells from bone-marrow precursors are linked to various genes on chromosome 4 and other chromosomes of the BB-DP rat. *J Autoimmun* 25:1–12. (2005)
24. Colak E, Ustuner MC, Tekin N, Colak E, Burukoglu D, Degirmenci I, Gunes HV. The hepatocurative effects of *Cynara scolymus* L. leaf extract on carbon tetrachloride-induced oxidative stress and hepatic injury in rats. *SpringerPlus*. Dec;5(1):216. (2016)
25. Pratibha R, Sameer R, Rataboli P V, Bhiwgade D A, Dhume C Y. Enzymatic studies of cisplatin induced oxidative stress in hepatic tissue of rats. *Eur. J. Pharmacol*. 532, 290-293. (2006)
26. Astolfi L, Ghiselli S, Guaran V, Chicca M, Simoni E, Olivetto E, Lelli G and Martini A: Correlation of adverse effects of cisplatin administration in patients affected by solid tumours: A retrospective evaluation. *Oncol Rep*. 29:1285–1292. (2013)
27. Saad S Y, Najjar T A, Alashari M. Role of nonselective adenosine receptor blockade and phosphodiesterase inhibition in cisplatin-induced nephrogonadal toxicity in rats. *Clin. Exp. Pharmacol Physiol*. 31, 862-867. (2004)
28. Kadikoylu G, Bolaman Z, Demir S, Balkaya M, Akalin N, Enli Y. The effects of desferrioxamine on cisplatin induced lipid peroxidation and the activities of antioxidant enzymes in rat kidneys. *Hum Exp Toxicol*. 23, 29-34. (2004)
29. Mahesh A, Shaheetha J, Thangadurai D, Rao DM. Protective effect of Indian honey on acetaminophen induced oxidative stress and liver toxicity in rat. *Biologia*. 64:1225–31 (2009).
30. İşeri S, Ercan F, Gedik N, Yüksel M, Alican I. Simvastatin attenuates cisplatin-induced kidney and liver damage in rats. *Toxicology*. 230:256–64 (2007).
31. Martins NM, Santos NA, Curti C, Bianchi ML, Santos AC. Cisplatin induces mitochondrial oxidative stress with resultant energetic metabolism impairment, membrane rigidification and apoptosis in rat liver. *J Appl Toxicol.*, 28: 337–344 (2008)
32. Shibayama K, Wachino J, Arakawa Y, Saidijam M, Rutherford NG, Henderson PJ. Metabolism of glutamine and glutathione via gamma glutamyl transpeptidase and

- glutamate transport in *Helicobacter pylori*: possible significance in the pathophysiology of the organism. *Mol Microbiol.*, 64(2): 396-406. (2007).
33. Hyunseong K, Gihyun L, Soojin P, Hwan-Suck C, Hyojung L, Jong-Yoon K, Hyunsu B. Bee venom mitigates cisplatin-induced nephrotoxicity by regulating CD4(+) CD25(+) Foxp3(+) regulatory T cells in mice. *Evidence-based Complementary and Alternative Medicine*, 2013, 1–10. (2013).
34. Darwish S F, El-Bakly W M , Arafa H M, El-Demerdash E. Targeting TNF- α and NF- κ B Activation by Bee Venom: Role in Suppressing Adjuvant Induced 8(11) , e79284 (2013).
35. Koyuncu I, Kocyigit A, Gonel A, Arslan E, Durgun M. The protective effect of naringenin on cisplatin-induced toxicity in rats. *Biochemistry research international*. 2017;2017.
36. Emerit J, Beaumont C , Trivin F. Iron metabolism, free radicals and oxidative injury. *Biomed Pharmacother.* 55, 333-339(2001).
37. Petricevich VI. Cytokine and nitric oxide production following severe envenomation. *Curr Drug Targets Inflamm Allergy.*, 3: 325-332. (2004).
38. Hassanein N, Hegab A. Bee Venom -Lead Acetate Toxicity Interaction *Aust. J. Basic & Appl. Sci.*, 4(8): 2206-2221, 2010
39. Rehman MU, Ali N, Rashid S, Jain T, Nafees S, Tahir M, et al. Alleviation of hepatic injury by chrysin in cisplatin administered rats: probable role of oxidative and inflammatory markers. *Pharmacological reports: PR.*;66(6):1050–9 (2014).
40. Lawrence T. The nuclear factor NF- κ B pathway in inflammation. *Cold Spring Harbor perspectives in biology.* 1(6):a001651 (2009)
41. Micheau O , Tschopp J. Induction of TNF receptor I-mediated apoptosis via two sequential signaling complexes. *Cell*, 114: 181-190. (2003).
42. Sharp CN, Doll MA, Dupre TV, Shah PP, Subathra M, Siow D, Arteel GE, Megyesi J, Beverly LJ, Siskind LJ. Repeated administration of low-dose cisplatin in mice induces fibrosis. *Am J Physiol Renal Physiol* 310: F560–F568,(2016).
43. Lee WR, Kim KH, An HJ, Kim JY, Chang YC, Chung H, Park YY, Lee ML, Park KK. The protective effects of melittin on *Propionibacterium acnes*-induced inflammatory responses in vitro and in vivo. *J. Investig. Dermatol.* 134:1922–1930 (2014).
44. Park JH, Lee WR, Kim HS, Han SM, Chang YC, Park KK. Protective effects of melittin on tumor necrosis factor- α induced hepatic damage through suppression of apoptotic pathway and nuclear factor- κ B activation. *Exp. Biol. Med.* 239:1705–1714. (2014).
45. Kim KH, Sung HJ, Lee WR, An HJ, Kim JY, Pak SC, Han SM, Park KK. Effects of melittin treatment in cholangitis and biliary fibrosis in a model of xenobiotic-induced cholestasis in mice. *Toxins.* ;7:3372–3387 (2015).