

***Allium sativum* (Garlic) Extract and Ascorbic Acid Comparatively Ameliorate Renal Parenchyma of Gentamicin-induced Nephropathic Rats**

ABSTRACT

To comparatively assess ameliorative effect of Ascorbic acid (AA) and *Allium sativum* ethanol extract (ASEE) on renal parenchyma of gentamicin-induced nephropathic rats.

Thirty Wistar rats (weighing between 180-205 g) were randomly divided into five groups (A-E). These include Group A administered with 0.9 % Normal Saline (0.5 ml/kg body weight (b.w.)), Group B administered with gentamicin (GM, 200 mg/kg b.w.) intraperitoneally (i.p.), Group C administered with GM (200 mg/kg b.w.) i.p. and AA (200 mg/kg b.w.) orally, Group D administered with GM (200 mg/kg b.w.) i.p. and ASEE (200 mg/kg b.w.) orally and Group E administered with GM (200 mg/kg b.w.) i.p. and AA (200 mg/kg b.w.) orally and ASEE (200 mg/kg b.w.) orally. All administrations were done once daily for a period of ten (10) days. The body weight of study animals was recorded at the beginning and end of study period. After the study period, renal tissue of study animals was harvested, weighed, processed, stained using H & E technique. Stained sections were examined under microscope for histopathological changes within the renal parenchyma and were scored using image-J software.

The results of this study showed that exposure to GM results into significant ($P < 0.05$) reduction in body and renal tissue weight. However, therapeutic exposure to AA and ASEE either as individual or combined treatment regimen culminated into relatively null body and renal tissue weight loss among treatment groups C-E. In addition, exposure to GM precipitates prominent histopathological changes within renal parenchyma of study animals. As observed with body and renal tissue weight changes, treatment with AA and ASEE also comparatively ameliorate GM-induced nephropathy within renal parenchyma of study animals in treatment groups.

The findings of this study therefore showed that AA and ASEE comparatively exhibit ameliorative effect on the renal parenchyma of gentamicin-induced nephropathic rats either as distinct or combined treatment regimen.

Keywords: *Allium sativum*; Ascorbic acid; gentamicin-induced nephropathy; renal parenchyma; wistar rats

1. INTRODUCTION

The renal tissue is among most versatile body tissues that perform or significantly contribute to several vital body functions which include excretion of metabolic waste products and foreign chemicals, body fluid and electrolyte homeostasis, regulation of acid-base balance, regulation of arterial pressure as well as hemopoietic and endocrine functions (Sembulingam and Sembulingam, 2010; Young et al, 2014; Teslariu et al, 2016). These functions can predispose the renal tissue to exposure and possible accumulation of potential nephrotoxins that may in turn trigger nephropathic changes within the renal parenchyma. Histopathological changes that characterized nephropathy, which may result into renal functional impairment or renal failure, include epithelial necrosis, glomerular congestion, interstitial oedema and inflammation, tubular dilatation and so on (Teslariu et al, 2016; Alarifi et al, 2012; Omotoso et al, 2020).

Nephropathy has been associated with application of some chemotherapeutic agents such as aminoglycosides antibiotics like gentamicin (GM) (Lakshmi and Sudhakar, 2010). In addition, experimental models of gentamicin-induced nephropathy are commonly used to probe ameliorative or

protective potential of chemical or phytochemical compounds against nephropathic effects of the nephrotoxin. As a potential nephrotoxin, GM can induce nephropathy by stimulating production of reactive oxygen species (ROS) leading to oxidative damage of renal parenchyma (Ozbeck et al, 2009; Morales et al, 2010). In essence, chemical or phytochemical compounds with antioxidant activity may exhibit ameliorative or protective effect against nephropathic effects of nephrotoxins such as GM.

Ascorbic acid (AA) has been described as a natural antioxidant which exhibits its potent antioxidant activity through down-regulation of ROS production and suppression of free radicals reactivity (Padayatty et al, 2003; Ibegbu et al, 2013; Acharya et al, 2013; Okwuonu et al, 2020-AAI). Similarly, *Allium sativum* is a common food spice that possesses antioxidant property and has been extensively applied for various therapeutic purposes such as anti-diabetic, anticancer and hepatoprotective (Mohandas et al, 2011; Chinnala et al, 2018; Omotoso et al, 2019-JMAS).

In this study, ameliorative effect of AA and *A. sativum* ethanolic extract (ASEE) on renal parenchyma of gentamicin-induced nephropathic Wistar rats was comparatively assessed.

2. MATERIALS AND METHODS

2.1 Chemical reagents and plant material

Chemical reagents used in this study were procured from Bristol Scientific Co. Ltd. (Lagos, Nigeria) while fresh bulbs of *A. sativum* were obtained from commercial sources in Benin City, Nigeria.

2.2 Extract Preparation

Fresh bulbs of *A. sativum* were air-dried at room temperature (22-24^oC) for four weeks and pulverized into powder form. 200 g of powdered *A. sativum* was dissolved in ethanol for 72 hours with intermittent agitation. The preparation was then filtered and evaporated to produce 22 g yield (percentage yield of 11%) used as ethanolic extract for treatment.

2.3 Study animals

Thirty Wistar rats, weighing between 180–205 g, were employed for this study. The animals were housed in plastic cages at room temperature and exposed to 12 hour light/dark cycle. They were fed with standard animal feed and allowed access to drinking water *ad libitum*. This study was carried out in the Central Animal House, Igbinedion University, Okada, Edo State, Nigeria.

2.4 Design of study

After the 14-day period of acclimatization, study animals were weighed and randomly divided into five groups (A-E) comprising of 6 animals each (n=6). Group A represented normal control; group B represented experimental control while groups C-E represented treatment groups. Group A was administered with 0.9 % Normal Saline (NS; 0.5 ml/kg body weight (b.w.)), Group B was administered with GM (200 mg/kg b.w.), Group C was administered with GM (200 mg/kg b.w.) and AA (200 mg/kg b.w.), Group D was administered with GM (200 mg/kg b.w.) and ASEE (200 mg/kg b.w.) while Group E was administered with GM (200 mg/kg b.w.) and AA (200 mg/kg b.w.) and ASEE (200 mg/kg b.w.). Administrations of NS and GM were done intraperitoneally while AA and ASEE done orally; once daily for ten days. Dosages employed in this study were considered safe and without toxic effects (Mohandas et al, 2011; Adeneye and Olagunju, 2009; Khan et al, 2011).

2.5 Collection and processing of study tissue

After the treatment period, each study animal was weighed, sacrificed via cervical dislocation and their right and left renal tissues harvested, weighed and processed. The processing of renal tissues to produce tissue blocks for histopathological study involved the following protocol: fixation using 10% Neutral-Buffered Formalin, dehydration using ascending grades of Alcohol (from 70% to absolute Alcohol), clearing using xylene and embedding using paraffin wax.

2.6 Sectioning of tissue blocks and staining of tissue sections

Renal tissue blocks were sectioned at thickness of 5 μ , mounted on microscope slides and stained using Haematoxylin and Eosin (H & E) staining technique. The H & E staining protocol employed in this study is given as follows: tissue sections were dewaxed in xylene, hydrated with descending grades of Alcohol (from absolute alcohol to 70% alcohol), stained in Haematoxylin, rinsed in water, differentiated in 1% Acid Alcohol, blued in Scott's tap water, rinsed in water, stained in Eosin, rinsed in water, dehydrated with ascending grades of Alcohol, cleared in xylene and mounted with Distrene polystyrene xylene DPX (Fischer et al, 2008).

2.7 Histopathological study

Stained renal tissue sections were viewed under microscope to assess the histomorphology of renal parenchyma of all study animals. Photomicrographs were generated for stained sections and observable renal histopathological features such as interstitial inflammation, epithelial necrosis, glomerular congestion and tubular dilatation within the renal parenchyma of study animals were evaluated using image-J software (NIH, Bethesda, MA, USA).

2.8 Statistical analysis

Data obtained during this study was analyzed using IBM-SPSS version 20 (IBM Corp, NY, USA) and results presented as Mean \pm standard error of mean (SEM). Comparison of statistical results was done using *t*-test and one way analysis of variance (ANOVA) with the probability level of $p < 0.05$ regarded as statistically significant.

3. RESULTS AND DISCUSSION

3.1 Evaluation of Body Weight of Study Animals

The mean values of total body weight of study animals in Groups A – E recorded at the beginning and end of the study period were given in Fig. 1. In comparison with normal control group A, mean values of body weight of group B animals showed significant ($p < 0.05$) reduction while those of treatment groups C – E showed no significant weight loss.

3.2 Evaluation of Renal Tissue Weight of Study Animals

The mean values of right and left kidney weight of study animals in Groups A – E recorded at the end of study period were given in Fig. 2. Similar to body weight changes, mean weight values of renal tissue of group B animals showed significant ($p < 0.05$) reduction in comparison with normal control group A. However, treatment groups C – E showed no significant renal tissue weight loss.

3.3 Histopathological Results

Histomorphology of renal parenchyma of study animals in Groups A – E were revealed in Fig. 3. Evaluation of renal histopathological features such as inflammation, necrosis and glomerular congestion showed significant ($p < 0.05$) prominence within renal parenchyma of group B relative to normal control group A. However, renal parenchyma of treatment groups C – E showed no significant prominence of renal histopathological features (Figs. 4).

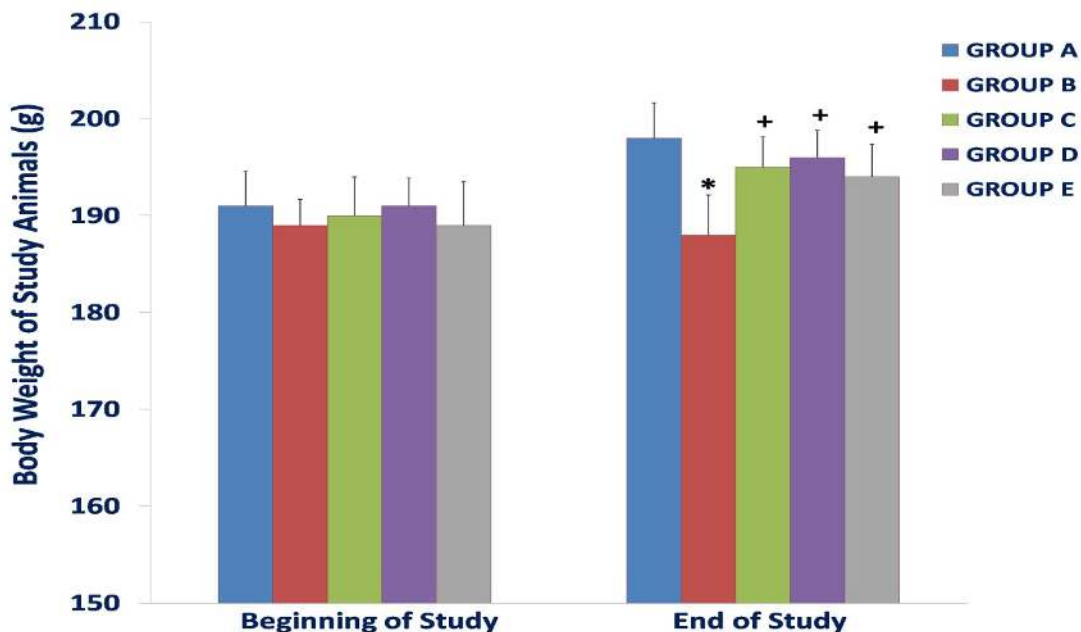


Fig. 1: Mean values of body weight of study animals in Groups A – E

(*,+ indicate significant difference from normal and experimental controls respectively at $P < 0.05$).
Group A = Normal control (NS), Group B = Experimental control (GM), Group C = GM+AA,
Group D = GM+A SEE, Group E = GM+AA+A SEE

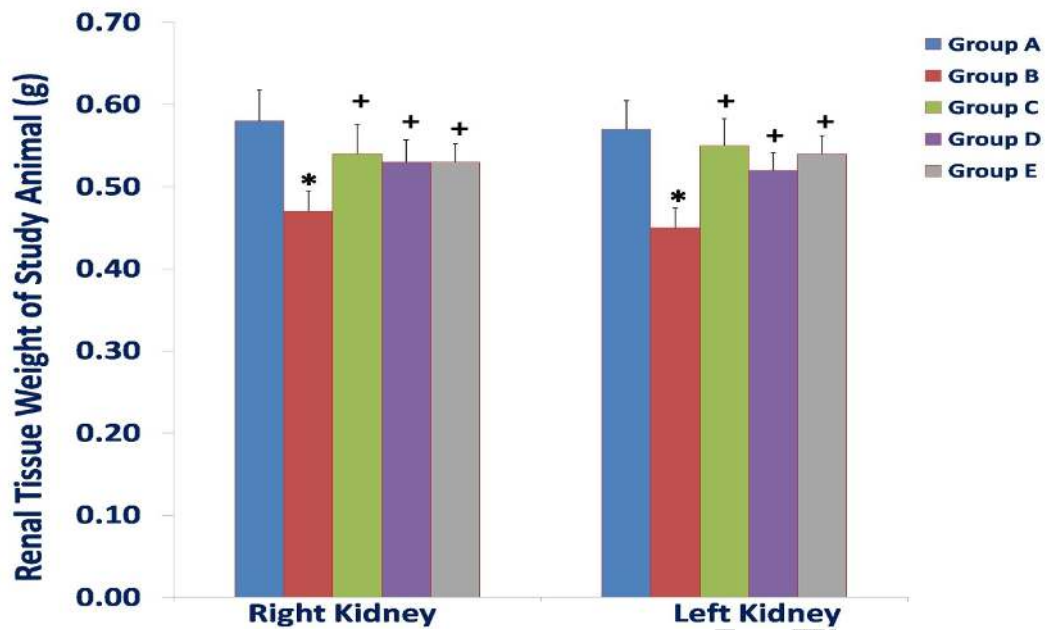


Fig. 2: Mean values of right and left kidney weight of study animals in Groups A – E (*, + indicate significant difference from normal and experimental controls respectively at $P < 0.05$). Group A = Normal control (NS), Group B = Experimental control (GM), Group C = GM+AA, Group D = GM+ASEE, Group E = GM+AA+ASEE

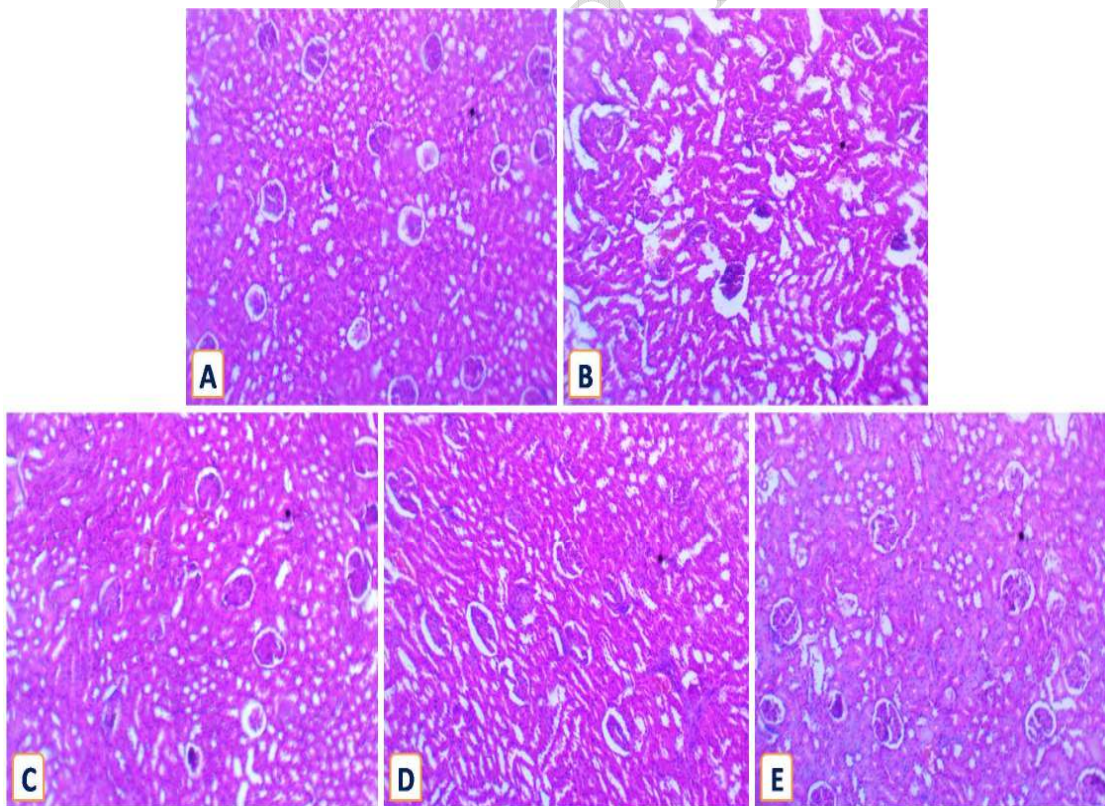


Fig. 3: Representative photomicrograph of renal tissue showing histopathological changes within renal parenchyma of study animals in Groups A – E (H & E X100) Group A = Normal control (NS), Group B = Experimental control (GM), Group C = GM+AA, Group D = GM+ASEE, Group E = GM+AA+ASEE

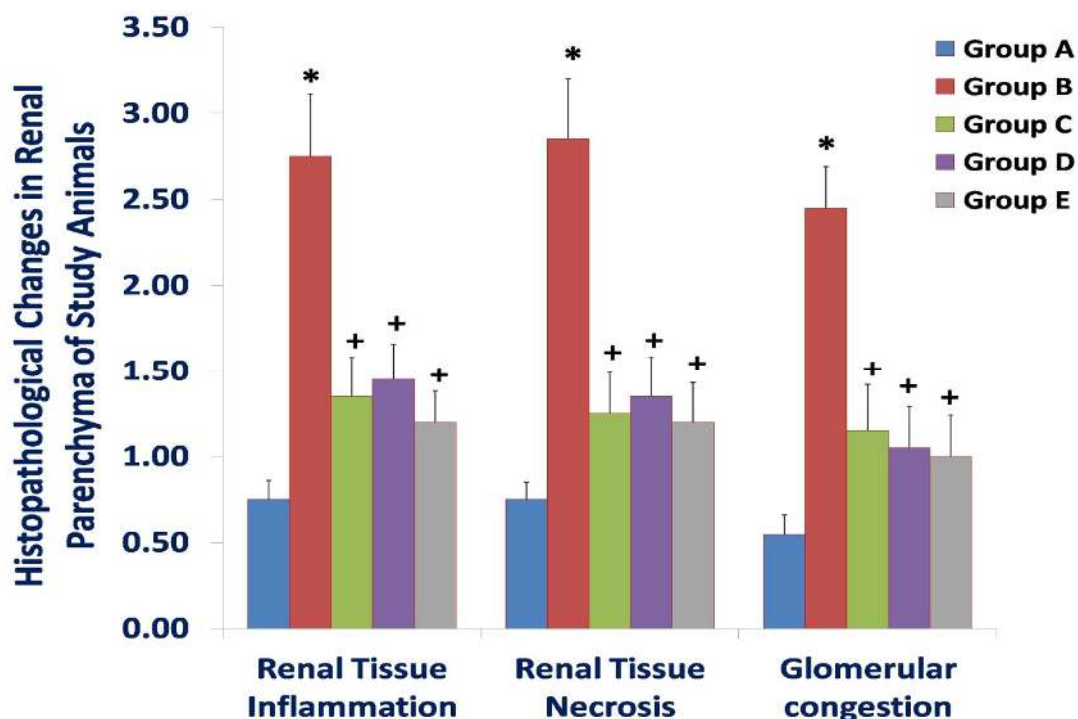


Fig. 4: Evaluation of histopathological changes within renal parenchyma of study animals in Groups A – E

(*,+ indicate significant difference from normal and experimental controls respectively at $P < 0.05$).
 Group A = Normal control (NS), Group B = Experimental control (GM), Group C = GM+AA,
 Group D = GM+ASEE, Group E = GM+AA+ASEE

The therapeutic application of aminoglycoside antibiotics such as GM has been reported to cause nephrotoxicity or nephropathy in about 30% of cases (Yarjani et al, 2016; Varatharajan et al, 2017). In principle, the activation of oxidative stress has been described as primary mediator of nephropathic effects of GM and potent antioxidants or ROS scavengers can be of therapeutic value in preventing or ameliorating deleterious effect of GM exposure (Acharya et al, 2013; Mazzon et al 2001; Maldonado et al, 2003). GM-induced nephropathy is often characterized by tubular damage, necrosis, fibrosis, oedema, inflammation and glomerular congestion which can in turn lead to renal dysfunction (Varatharajan et al, 2017; Balakumar et al, 2010; Lopez-Novoa et al, 2011).

According to results of this study, the exposure to GM results into significant ($P < 0.05$) reduction in body and renal tissue weight (Figs. 1 and 2). This can be linked with deleterious effects of GM exposure on the study animal body in general and their renal tissue in particular. However, it can be observed that therapeutic exposure to AA and ASEE as individual or combined treatment regimen culminated into relatively null body and renal tissue weight loss among treatment groups C-E. In addition, exposure to GM precipitates prominent histopathological changes within renal parenchyma of study animals (Figs. 3 and 4). As observed with body and renal tissue weight changes, treatment with AA and ASEE also comparatively ameliorate GM-induced nephropathy within the renal parenchyma of study animals in treatment groups C-E.

As a naturally occurring vitamin, AA can be readily sourced from citrus fruits, strawberries and vegetables and as antioxidant; it acts to suppress ROS production or activation in tissues (Dawud et al, 2012). Each molecule of AA has in its structure two hydrogen atoms that bear two high-energy electrons which can be readily donated to stabilize ROS (Oguntibeju, 2008; Afifi and Embaby, 2016). Based on the results of this study and in comparison with previous studies, AA potentially acts to suppress ROS reactivity thereby functioning as free radical scavenger that ameliorates ROS-induced oxidative damage caused by GM exposure in renal tissue (Kadkhodae et al, 2005; Ariharan et al, 2012; Kadi and Dahdouh, 2016).

Furthermore, *A. sativum* is a member of *Liliaceae* family commonly used as food spice. It is one of the most popular herbs with numerous therapeutic properties and widely used in modern folkloric

medicine. Its characteristic strong odour is due to its sulphur-containing compounds (especially S-allylcysteine sulphoxide or allicin) which also confer the potent therapeutic properties (Mahesar et al 2010; Hussein 2014; Omotoso et al, 2019-JMAS; Thomson et al, 2007). *A. sativum* has been reported to contain phytochemicals with potent antioxidant property which constitute the primary basis of its therapeutic activity against oxidant-mediated tissue pathologies like GM-induced nephropathy (Anwar and Meki, 2003; Thomson et al, 2007). In comparison with previous studies, ameliorative effect of ASEE against GM exposure observed in this study can be related with antioxidant activity of its phytochemical constituents which suppresses oxidative renal tissue damage that follows GM exposure,

4. CONCLUSION

The findings of this study showed that AA and ASEE comparatively exhibit ameliorative effect on the renal parenchyma of gentamicin-induced nephropathic rats either as distinct or combined treatment regimen. The ameliorative effect of both AA and ASEE can be comparatively associated with their distinct antioxidant activity.

ETHICAL APPROVAL

This study was approved by the Research and Ethics Committee of Igbinedion University, Okada, Edo State, Nigeria. The study protocols were in compliance with International guidelines for handling and care for experimental animals.

COMPETING INTERESTS DISCLAIMER:

Authors have declared that no competing interests exist. The products used for this research are commonly and predominantly use products in our area of research and country. There is absolutely no conflict of interest between the authors and producers of the products because we do not intend to use these products as an avenue for any litigation but for the advancement of knowledge. Also, the research was not funded by the producing company rather it was funded by personal efforts of the authors.

REFERENCES

1. Sembulingam K, Sembulingam P. Essentials of Medical Physiology. Fifth Edition. Jaypee Brothers Medical Publishers Ltd, St Louis, USA. 2010; p 288.
2. Young B, O'Dowd G, Woodford P. Wheater's Functional Histology: a text and colour atlas. Sixth Edition. Elsevier Churchill Livingstone PA, USA. 2014; p 292.
3. Teslariu O, Pasca AS, Mititelu-Tartau L, Schiriac CE, Gales C, Saftencu PM, Nechifor M. The protective effects of Zinc in experimental gentamicin induced acute renal failure in rats. J Physiol Pharmacol 2016; 67(5): 751-757.
4. Alarifi S, Al-Doaiss A, Alkahtani S, Al-Farraj, Al-Eissa MS, Al-Dahmash B, Al-Yahya H, Mubarak M. Blood chemical changes and renal histological alterations induced by gentamicin in rats. Saudi J Biol Sci 2012; 19(1): 103-110. DOI: 10.1016/j.sjbs.2011.11.002
5. Omotoso DR, Lawal OS, Olatomide OD, Okojie IG. Nephroprotective effect of *Cissampelos owariensis* extract on renal histomorphology of Wistar rats during exposure to carbon tetrachloride-induced nephropathy. Asian J Biol 2019; 8(4): 1-10. DOI: 10.9734/AJOB/2019/v8i430071
6. Lakshmi BVS, Sudhakar M. Protective effect of *Zingiber officinale* on gentamicin-induced nephrotoxicity in rats. Int J Pharmacol 2010; 6(1): 58-62.
7. Ozbeck E, Cekmen M, Ilbey YO, Simsek A, Polat EC, Somay A. Atorvastatin prevents gentamicin-induced renal damage in rats through the inhibition of p38-MAPK and NK-kappa B pathways. Ren Fail 2009; 31: 382-392.
8. Morales AI, Demaille D, Prieto M, Puente A, Briones E, Arevalo M, Leverage X, Lopez-Novoa JM, El-Mir M. Metformin prevents experimental gentamicin-induced nephropathy by a mitochondria-dependent pathway. Kidney Int 2010; 77(10): 861-869.

DOI: 10.1038/ki.2010.11

9. Padayatty SJ, Katz A, Wang Y, Eck P, Kwon O, Lee J, Chen S, Corpe C. Vitamin C as an antioxidant: evaluation of its role in disease prevention. *J Am Coll Nutr* 2003; 22(1): 18-35.
10. Ibegbu AO, Animoku AA, Ayuba M, Brosu D, Adamu SA, Akpulu P, Hamman WO, Umana UE, Musa SA. Effect of Ascorbic acid on mercuric chloride-induced changes on the cerebral cortex of Wistar rats. *Afr J Cell Pathology* 2013; 1: 23-29.
11. Acharya C, Thakar H, Vajpeyee SK. A study of oxidative stress in gentamicin induced nephrotoxicity and effect of antioxidant Vitamin C in wistar rats. *Nat J Physiol Pharm Pharmacol* 2013; 3(1): 14-20.
DOI: 10.5455/njppp.2013.3.14-20
12. Okwuonu UC, Omotoso DR, Bienonwu EO, Adagbonyin O, Dappa J. Histomorphological profile of liver and kidney tissues of albino Wistar rats following exposure to cadmium-induced damage and ascorbic acid supplementation. *Acad Anat Int* 2020; 6(1): *in press*
13. Mohandas R, Paramesha S, Suchetha KN, Damodara GKM, Vidhya GG. Effect of Garlic on total antioxidants in Alloxan induced Diabetic mellitus rats. *Int J Biomed Adv Res* 2011; 2(9): 317-328.
14. Chinnala KM, Jayagar PP, Motta G, Adusumilli RC, Elsani MM. Evaluation of hepatoprotective activity of *Allium sativum* extract in thioacetamide-induced hepatotoxicity in albino Wistar rats. *Am J Res Med Sci* 3(2): 48-53.
15. Omotoso DR, Akinola AO, Daramola OO. Possible stimulatory role of CTLA-4 gene in anti-diabetic activity of ethanolic extracts of *Allium sativum* (Garlic) using rat model. *J Med Allied Sci* 2019; 9(2): 90–95.
DOI: 10.5455/jmas.49716
16. Adeneye AA, Olagunju JO. Protective effect of oral Ascorbic acid (Vitamin C) on acetaminophen-induced renal injury in rats. *Afr J Biomed Res* 2009; 12(1): 55-61.
17. Khan MR, Badar I, Siddiquah A. Prevention of hepatorenal toxicity with *Sonchus asper* in gentamicin treated rats. *BMC Compl Alt Med* 2011; 11:113.
18. Fischer AH, Jacobson KA, Rose J, Zeller R. Haematoxylin and eosin staining of tissue and cell sections. Cold Spring Harbor Protocols; Cold Spring Harbor, NY, USA: Cold Spring Harbor Press; 2008.
19. Yarijani ZM, Najafi H, Hamid Madani S. Protective effect of crocin on gentamicin-induced nephrotoxicity in rats. *Iran J Basic Med Sci.* 2016;19:337-43.
20. Varatharajan R, Jun LH, Kai TZ, Jian LW, Anburaj J, Vijayan V. Morphological and morphometric study of Edaravone in gentamicin-induced nephrotoxicity in Sprague Dawley Rats. *J Young Pharm* 2017; 9(1): 31-35. DOI: 10.5530/jyp.2017.9.6
21. Mazzon E, Britti D, De Sarro A, Caputi AP & Cuzzocrea S. Effect of N-acetylcysteine on gentamicin-mediated nephropathy in rats. *Eur J Pharmacol* 2001; 424, 75–83.
22. Maldonado PD, Barrera D, Rivero I, Mata R, Medina-Campos ON, Hernandez-Pando R & Pedraza-Chaverri J. Antioxidant S-allylcysteine prevents gentamicin-induced oxidative stress and renal damage. *Free Radic Biol Med* 2003; 35, 317–324.
23. Balakumar P, Rohilla A, Thangathirupathi A. Gentamicin-induced nephrotoxicity: Do we have a promising therapeutic approach to blunt it?. *Pharmacol Res* 2010; 62:179–86.
24. Lopez-Novoa JM, Quiros Y, Vicente L, Morales AI, Lopez-Hernandez FJ. New insights into the mechanism of aminoglycoside nephrotoxicity: an integrative point of view. *Kidney Int* 2011; 79: 33-45.
25. Dawud FA, Eze ED, Ardja AA, Isa AS, Jimoh A, Bashiru M, Malgwi IS. Ameliorative effects of Vitamin C and Zinc in Alloxan-induced Diabetes and oxidative stress in Wistar rats. *Curr Res J Bio Sci* 2012; 4(2): 123-129.
26. Oguntibeju OO. The biochemical, physiological and therapeutic roles of ascorbic acid. *Afr J Biotechnol* 2008; 7(25): 4700-4705.
27. Afifi OM, Embaby AS. Histological study on the protective role of Ascorbic acid on cadmium induced cerebral cortical neurotoxicity in adult male Albino rat. *J Microsc Ultrastruct* 2016; 4: 36-45. DOI: 10.1016/j.jmau.2015.10.001
28. Kadkhodae M, Khastar H, Faghihi M, Ghaznavi R, Zahmatkesh M. Effects of co-supplementation of vitamins E and C on gentamicin-induced nephrotoxicity in rat. *Exp Physiol* 2005; 90(4): 571-576. DOI: 10.1113/expphysiol.2004.029728
29. Ariharan VN, Kalirajan K, Meena Devi VN, Prasad NP. An exotic fruit which forms the new natural source for vitamin-C. *Rasayan J Chem* 2012;5:356-9.
30. Kadi IE, Dahdouh F. Vitamin C pretreatment protects from nickel-induced acute nephrotoxicity in mice. *Arh Hig Rada Toksikol* 2016;67:210-215
31. Mahesar H, Bhutto MA, Khand AA, Najero NT. Garlic used as an alternative medicine to control diabetic mellitus in alloxan-induced male rabbits. *Pak J Physiol* 2010; 6(1): 39-41.

32. Hussein ZM. Effect of garlic on dyslipidemic patients with diabetes mellitus (Type 2). Diyala J Med. 2014; 6(1):100-4.
33. Thomson M, Al-Amin ZM, Al-Qattan KK, Shaban LH, Ali M. Anti-diabetic and hypolipidaemic properties of garlic (*Allium sativum*) in streptozotocin-induced diabetic rats Int J Diabetes & Metabolism 2007; 15: 108-115
34. Anwar MM, Meki AR. Oxidative stress in streptozotocin-induced diabetic rats: effects of garlic oil and melatonin. Comp Biochem Physiol A Mol Integr Physiol 2003; 135: 539-547.

UNDER PEER REVIEW