

## **Hysteroscopic diagnosis of uterine artery pseudo-aneurysm as a cause of recurrent severe secondary postpartum hemorrhage: A case report**

**Running title:** hysteroscopic diagnosis of uterine artery pseudo-aneurysm

### **Abstract:**

**Aim;** is to raise the value of hysteroscopy in diagnosing uterine artery pseudo-aneurysm in patients with secondary postpartum haemorrhage.

**Presentation of Case;** Here we report a case of 34 year-old woman presented to the emergency department with recurrent attacks of secondary postpartum hemorrhage after cesarean delivery. Diagnostic hysteroscopy was done after controlling of the bleeding and confirmed a large cesarean scar defect with a large pulsating vessel in its left side wall that was diagnosed later by angiography as left uterine artery pseudo-aneurysm. Despite trans-catheter arterial embolization of both uterine arteries, the patient developed severe attack of bleeding with hypovolemic shock necessitating emergency hysterectomy.

**Discussion;** Uterine artery pseudo-aneurysm is a rare cause of secondary postpartum hemorrhage that should be suspected in cases of recurrent bleeding after caesarean section with the absence of remnants of conception.

Uterine artery pseudo-aneurysm diagnosed by color Doppler sonography and computed tomography (CT), magnetic resonance imaging, and angiography. Diagnostic hysteroscopy is a minimally invasive procedure that should be used to diagnose uterine artery pseudo-aneurysm in suspected cases after controlling of the bleeding.

**Conclusion;** Hysteroscopy should be used to exclude uterine artery pseudo-aneurysm before any attempt to do uterine curettage in patients with secondary postpartum hemorrhage after cesarean section, where the aneurysm might be injured accidentally during the procedure resulting in uncontrollable hemorrhage.

### **Introduction:**

Secondary postpartum hemorrhage (PPH) is defined as abnormal or excessive bleeding from the birth canal between 24 hours and 12 weeks postnatally<sup>1</sup>, with retained products of conception and endometritis are considered the commonest etiologies; partial or complete dehiscence of the lower uterine segment incision<sup>2</sup> and vascular anomalies being a rarer causes<sup>3</sup>. Uterine artery pseudo-aneurysm (UAP) should be considered as a differential diagnosis in patients presenting with significant, painless and recurrent postpartum hemorrhage, particularly after an operative delivery<sup>4</sup>.

In Egypt, as in the whole world, the past decade has witnessed a sharp increase in the prevalence of cesarean section (CS) with recent reports that Egypt ranked 3rd among world countries with an estimated rate of Cesarean section of 51.8%<sup>5</sup>. As a result of the increase in the rate of caesarean deliveries, cesarean scar defect (CSD) and uterine artery pseudo-aneurysm (UAP) can be faced in an increasing number of cases presenting with secondary postpartum hemorrhage or abnormal uterine bleeding. Herein, we report a case of recurrent severe secondary PPH caused by UAP in a CSD that was diagnosed with hysteroscopy.

### **Presentation of Case**

We present a case of multiparous woman of 34 years old who delivered by caesarean section for failed progress of labor five months prior to her presentation to our hospital. Starting from the third week postpartum, the patient developed two episodes of secondary postpartum hemorrhage,

for which she received seven units of blood and two operations of dilatation and curettage based on the diagnosis of remnants of conception. The patient was admitted to Ain shams maternity hospital with a third episode of severe postpartum hemorrhage for which she received 4 units of packed red blood cells, intravenous haemostatic and antibiotics. There was no history suggestive of puerperal infection as fever, abnormal vaginal discharge, or wound infection. On examination, the patient abdomen was lax; CS abdominal scar was healed by primary intention without abdominal tenderness or masses. On pelvic examination, the uterus was not tender, slightly enlarged with closed internal cervical os. Her hemoglobin was 9 gm/dl, Platelet count and coagulation profile were within the normal range and pelvic ultrasound examination revealed no remnants of conception. An intrauterine balloon tamponade was applied where the bleeding stopped few hours later. Diagnostic hysteroscopy revealed a large caesarean section scar defect with a large pulsating blood vessel on its left side wall {(Figure 1) and supplementary video}. Interventional radiology was consulted and digital subtraction angiography confirmed left uterine artery pseudo-aneurysm (Figure 2) and the decision for trans-catheter arterial embolization (TAE) of both uterine arteries was taken and was performed with the use of gelfoam which is the only available in the emergency settings in our hospital. The delayed angiogram demonstrated absence of flow in both uterine arteries; with no immediate post-procedural complication. Three days later the patient developed severe attack of bleeding with hypovolemic shock that was failed to be controlled by hemostatic, aggressive fluid and blood transfusion measures and the decision was taken for emergency laparotomy. At laparotomy, there was no hemo-peritoneum and there was a dehiscence of the caesarean section scar where a total abdominal hysterectomy was performed (Figure 3, 4). The patient received 18 units of packed red blood cells in our hospital; in total 25 units after cesarean delivery.

## **Discussion:**

Uterine artery pseudo-aneurysm is a rare life-threatening cause of secondary postpartum hemorrhage. Extended uterine incision, additional hemostatic sutures and repeated caesarean sections are the risk factors associated with the occurrence of pseudo-aneurysm after cesarean section<sup>3</sup>. UAP should be listed as a possible cause of postpartum hemorrhage after CS that can present with sudden, painless, severe hemorrhage at any stage, even years later<sup>4</sup>.

Trauma to the uterine artery during surgery may cause a defect in the arterial wall, through which arterial blood escapes and diffuses to the adjacent tissues, resulting in the formation of a hematoma, when this hematoma is in continuity with the uterine artery that supplies continuous blood flow, a pseudo-aneurysm forms, that can be differentiated from a true aneurysm by the absence of a three-layered arterial wall lining<sup>6</sup>.

Lack of recognition of UAP frequently leads to incorrect management and poor outcomes, including repeated blood transfusions, multiple emergency room visits, repeated cervical dilatation and curettage, and even hysterectomy in severe cases.<sup>7</sup>

Proper treatment requires an accurate diagnosis, which might be delayed as the best method of diagnosis has not been well established because uterine artery pseudo-aneurysm is considered a rare condition; generally diagnosis is based on the results of color Doppler sonography and computed tomography (CT), magnetic resonance imaging, and angiography<sup>6</sup>.

Previously Chummun et al, reported that hysteroscopy has a limited role in identifying uterine pathology in cases of secondary PPH during the bleeding attack<sup>4</sup>. Although most of the cases presented with recurrent attacks of bleeding, they are free from bleeding in between the attacks and most of them were discharged home after stabilization or after evacuation.<sup>8,9</sup>

Hysteroscopy can be a beneficial tool in excluding the presence of placental remnants as most of reported cases underwent unnecessary uterine evacuation and curettage<sup>6,8,9</sup>. Moreover, it is the gold standard in diagnosing CSD<sup>10</sup> that has been raised as a cause of 2ry PPH<sup>6</sup> and here in this case, we report the first case of uterine artery pseudo-aneurysm diagnosed with the hysteroscope. The significance of this case report is that the uterine artery pseudo-aneurysm presented through CSD could be injured accidentally during the blind curettage for the remnants of conception, leading to a massive intractable hemorrhage during the operation necessitating immediate hysterectomy that could occur in unsuitable hospital settings putting the patient life in danger. Treatment options of UAP include hysterectomy, surgical ligation of uterine arteries and arterial embolization; that should be considered as the treatment of choice for stable patients. Many studies have documented the safety and effectiveness of TAE for secondary PPH with reported clinical success rates reaching 90%.<sup>11</sup> In the current case report, uterine arteries embolization with the use of gelfoam resulted in immediate complete occlusion of both uterine arteries; however, three days later the patient developed severe attack of bleeding and emergency hysterectomy was done. This incidence was explained later by the dislodgement of the gelfoam plug from the occluded vessels where coiling of the pseudo-aneurysm with stainless steel coil via selective catheterization of the uterine artery is the one that should be used in cases of pseudo-aneurysm, but unfortunately it was not available in our hospital at that time. Previous cases that showed recurrent bleeding after embolization resulting from anastomotic vascular supply that refeed the pseudo-aneurysm after occlusion of the uterine artery as the ovarian arteries, or the other uterine artery<sup>3</sup>, which can be diagnosed and managed by further angiography and embolization, this was not feasible in our case as the woman was in hypovolemic shock and

failed to respond to resuscitation measures with hemostatic, intravenous fluids and blood transfusion.

Recurrence of the bleeding do not signify a failed embolization but rather bleeding from other vessel that refeed the false aneurysm; redistribution and redirection of blood or hypoxia-induced neovascularization are suggested as a cause of bleeding from another vessel after the initial embolization<sup>3</sup>.

**Conclusion:** Dehiscent caesarean section scar with uterine artery pseudo-aneurysm should be one of the differential diagnoses of secondary postpartum hemorrhage especially in the absence of evidence of remnants of conception or endometritis. Moreover, hysteroscopy should be used to exclude its presence before any attempt to do uterine curettage or balloon tamponade, where the aneurysm could be injured accidentally during the procedure resulting in uncontrollable hemorrhage.

#### References:

1. Mavrides E, Allard S, Chandraharan E, Collins P, Green L, Hunt BJ, Riris S. Prevention and management of postpartum haemorrhage. *BJOG*. 2016; 124 :e106–e149. <https://doi.org/10.1111/1471-0528.14178>
2. Wagner MS and Bédard MJ. Postpartum uterine wound dehiscence : a case report. *Journal of Obstetrics and Gynaecology Canada*. 2006 ; 28( 8) : 713–715.
3. Wu CQ, Nayeemuddin M, Rattray D. Uterine artery pseudoaneurysm with an anastomotic feeding vessel requiring repeat embolization. *BMJ Case Reports*. 2018; 224656. <https://doi.org/10.1136/bcr-2018-224656>
4. Chummun K, Kroon N, Flannelly G, Brophy D. Severe Postcoital Bleeding From a Uterine Artery Pseudoaneurysm 4 Months after Cesarean Delivery. *Obstet Gynecol*. 2015;126(3):638-41. <https://doi.org/10.1097/AOG.0000000000000849>.
5. Kandil M .The Sky rocketing rate of Cesarean section in Egypt. *Glob Drugs Therap*.2018; 3. <https://doi.org/10.15761/GDT.1000153>
6. Yeniel AO, Ergenoglu AM, Akdemir A, Eminov E, Akercan F, Karadadaş N. Massive secondary postpartum hemorrhage with uterine artery pseudoaneurysm after cesarean section. *Case Rep Obstet Gynecol*. 2013; 285846. <https://doi.org/10.1155/2013/285846>

7. Parr K, Hadimohd A, Browning A, Moss J. Diagnosing and treating postpartum uterine artery pseudoaneurysm. *Proc (Bayl Univ Med Cent)*. 2018; 31(1):56–58. <https://doi.org/10.1080/08998280.2017.1400301>
8. Kovo M, Behar DJ, Friedman V, Malinger G. Pelvic arterial pseudoaneurysm-a rare complication of Cesarean section: diagnosis and novel treatment. *Ultrasound Obstet Gynecol*. 2007; 30(5):783-5.
9. Eason DE, Tank RA. Avoidable morbidity in a patient with pseudoaneurysm of the uterine artery after cesarean section. *J Clin Ultrasound*. 2006; 34(8):407-11.
10. El-Mazny A, Abou-Salem N, El-Khayat W, Farouk A. Diagnostic correlation between sonohysterography and hysteroscopy in the assessment of uterine cavity after cesarean section, *Middle East Fertility Society Journal*,2011;16 (1): 72-76. <https://doi.org/10.1016/j.mefs.2010.07.015>.
11. Park H, Shin JH, Yoon HK, Kim JH, Gwon DI, Ko GY, Sung K B. Transcatheter Arterial Embolization for Secondary Postpartum Hemorrhage: Outcome in 52 Patients at a Single Tertiary Referral Center. *Journal of Vascular and Interventional Radiology*. 2014; 25(11): 1751–1757. <https://doi.org/10.1016/j.jvir.2014.05.009>

## Figure Legends:

Figure 1: hysteroscopic view of the left uterine artery pseudo aneurysm (arrow 1), the cesarean scar defect (arrows 2) and uterine cavity (arrow 3)

Figure 2: angiography revealing left uterine artery pseudo-aneurysm (arrow)

Figure 3 A (Arrow shows dehiscence of cs scar)

Figure 3 B (Arrows show 1. dehiscence of cs scar. & 2. left uterine artery pseudoaneurysm)

Supplementary video: diagnostic hysteroscopy in a case of 2ry postpartum hemorrhage showing large cesarean scar defect with pulsating left uterine artery pseudo aneurysm

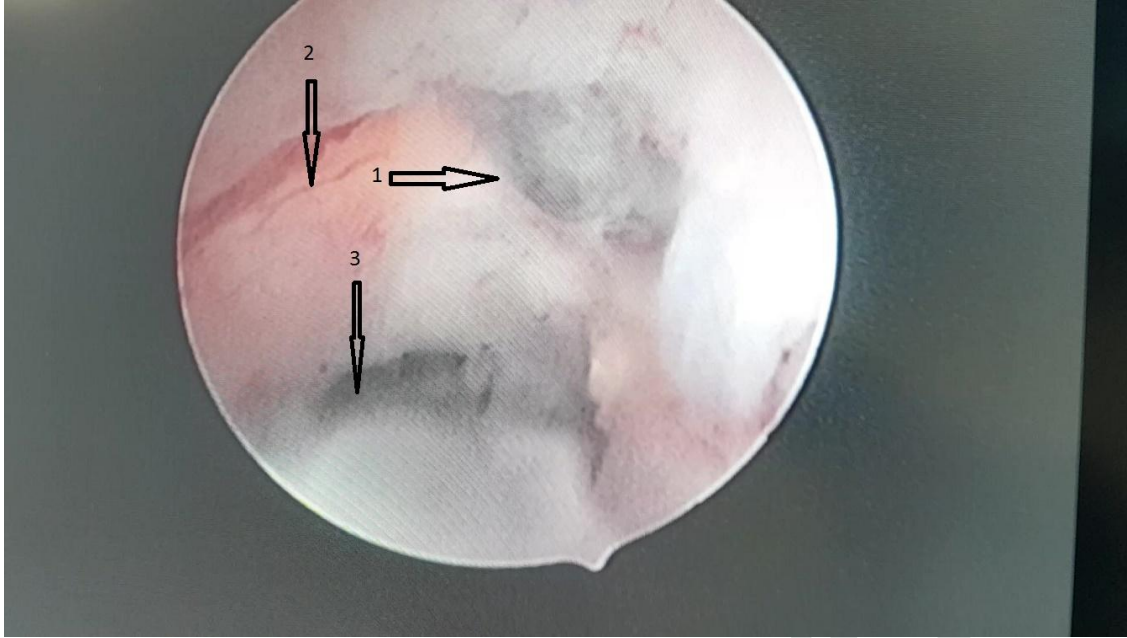


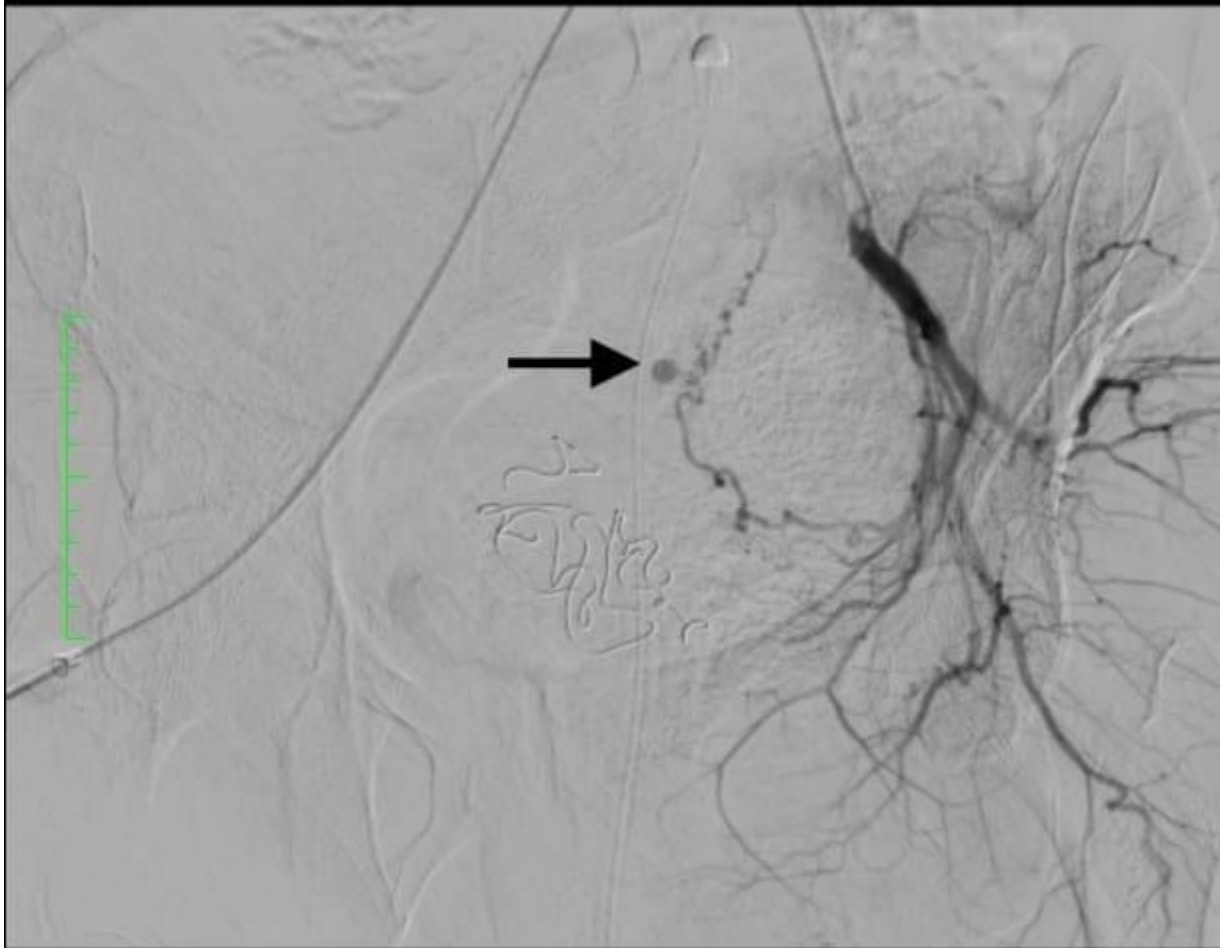
Figure 1: hysteroscopic view of the left uterine artery pseudo aneurysm (arrow 1), the cesarean scar defect (arrows 2) and uterine cavity (arrow 3)

UNDER PEER REVIEW



Image size: 512 x 512  
WL: 511 WW: 1023

722028-1703-201909151336042 ( -, - )  
Abdomen  
Head



Zoom: 119%  
Im: 9/11 Series: 4  
LittleEndianExplicit

9/15/19, 2:05:33 PM  
1 hr, 54 min  
Made In OsiriX

Figure 2: angiography revealing left uterine artery pseudo-aneurysm (arrow)

UNDER PEER REVIEW

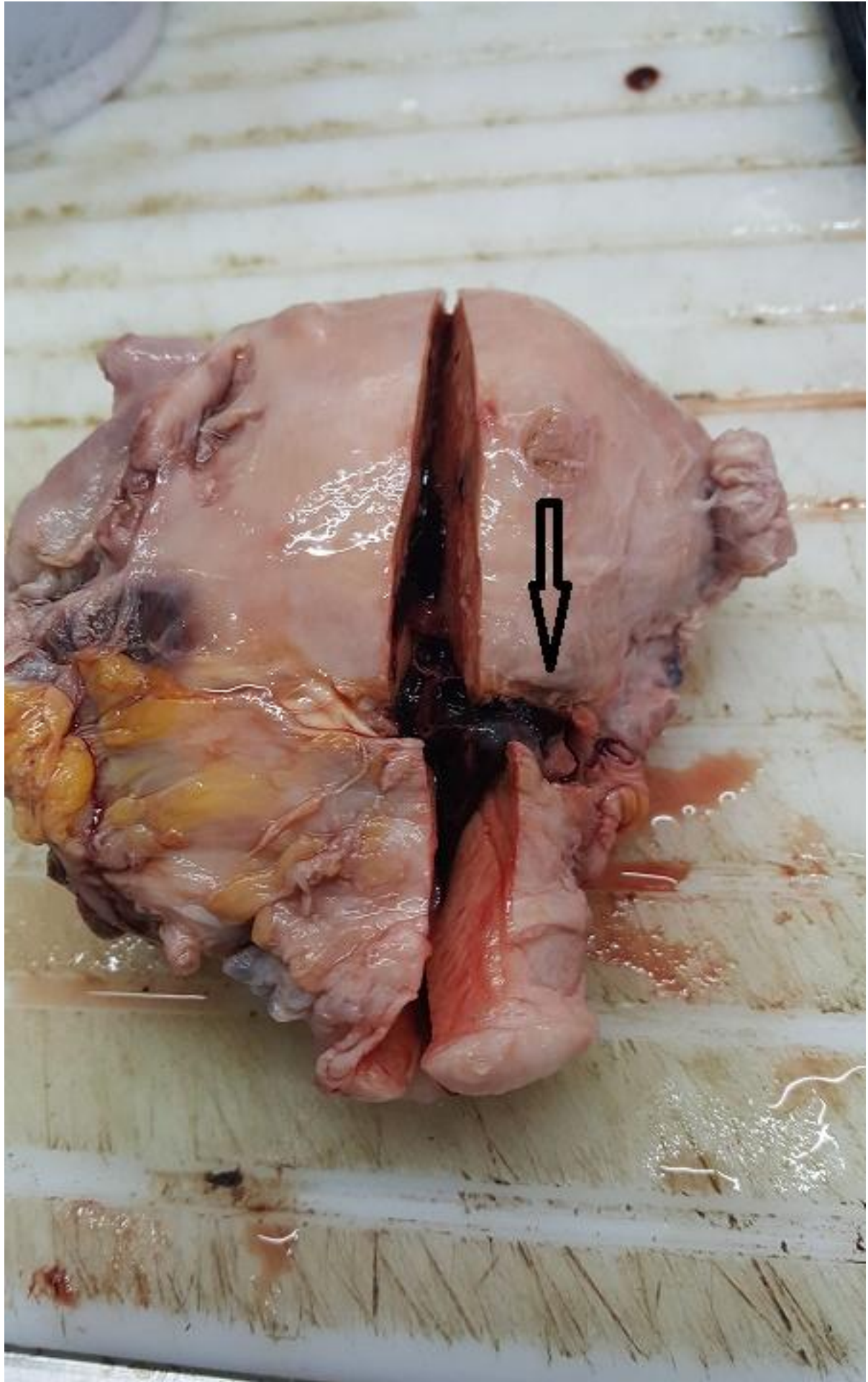


Figure 3 A (Arrow shows dehiscence of cs scar)

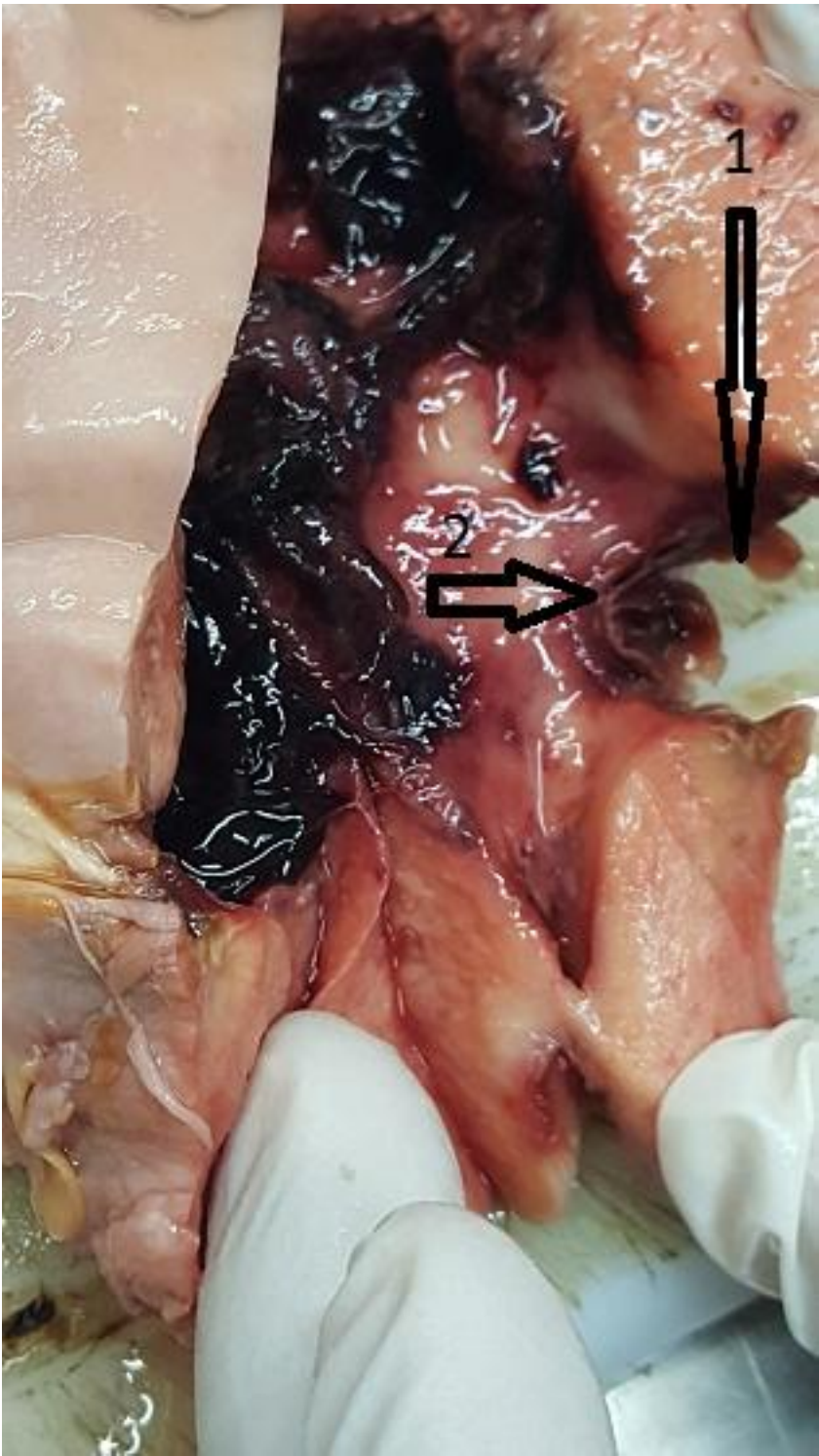

Figure 3 B (Arrows show 1. dehiscence of cs scar. & 2. left uterine artery pseudoaneurysm)

UNDER PEER REVIEW