

# COMPARATIVE EFFECT OF GINGER (*Zingiber officinale*) SUPPLEMENT ON HEPATO.-RENAL DAMAGES INDUCED BY ACETAMINOPHEN TOXICITY IN WISTAR RATS

## Abstract

**Background:** Acetaminophen toxicity is one of the widespread causes of both planned and unplanned health related issues in the world today. It is a familiar cause of liver and kidney damage particularly in adolescents and children. **Aims:** With the growing focus in the mitigating and therapeutic roles of herbal drugs in toxicity studies, it is perceptible to investigate the comparative, prophylactic and curative effect of the ginger supplement on acetaminophen-induced liver and kidney damage using wistar rats as model. **Methodology:** **Study design:** Twenty (20) adult wistar rats weighing 185g-220g was obtained from animal house of the department of Pharmacology University of Port Harcourt were divided into four groups having five rats each. **Methodology:** Twenty adult wistar rats were divided into four (4) groups of five animal each and treated orally as follows: Group A (normal control) received distilled water (7days), group 2 received 1000mg/kg acetaminophen (APAP) (2 days). Group 3 Ginger (GINE+APAP) received ginger supplements 500mg/kg respectively one hour before administration of APAP for 7 days, whereas group 4 received APAP (2 days) followed by 500mg/kg Ginger for 5 days (APAP+GINE). At the end of the experiment, animals from different groups were anaesthsized, blood samples collected, liver and kidney tissues dissected and subjected to different biochemical, antioxidants, and histopathological test. **Statistical** analysis was done using One Way Anova and Tukey's Post-hoc Test. **Results** APAP caused significant ( $P<0.05$ ) decrease in creatinine ( $130.00\pm 6.16^*$ ) ( $115.20\pm 9.92$  with significant ( $P<0.01$ ) ( $57.20\pm 3.99$ ) ( $98.20\pm 5.77^{**}$ ) ( $90.80\pm 3.64^{**}$ ) increase and decrease in liver enzymes and hepatic ( $1.83\pm 0.53$ ,  $0.43\pm 0.08^{**}$   $1.80\pm 0.29$ ) catalase levels respectively in relation to normal control. Treatment of rats with the ginger supplements attenuated the elevated liver and kidney biochemistry, histopathological alterations by APAP treatment. **Conclusively**, the extracts demonstrated therapeutic ability and the herbal drugs may be more effective when use prophylactically than curatively. Further research work is needed to validate the finding.

**Key Words:** Biochemical, histopathology, Acetaminophen, Prophylactic, Curative, Supplement, Ginger

**Abbreviations:** NORC (NORMAL CONTROL), APAP (ACETAMINOPHEN), GINE (GINGER)

## 1.1 Introduction

N-Acetyl-p-Aminophenol (APAP), also known as acetaminophen, is the most commonly used over-the counter analgesic and antipyretic medication. However, its overdose leads to both liver and kidney damage. APAP-induced toxicity is considered as one of the primary causes of acute liver failure; numerous scientific reports have focused majorly on APAP hepatotoxicity and nephrotoxicity. (1)

Ginger (*Zingiber officinale*) is a plant of the zingiberaceae family, and is from the same family with turmeric. It originated in Malaysia and India and is estimated to have been used for about

5000 years. It is very rich in minerals and vitamins B1, B2, B3, and C but once it is dried, the vitamin is lost entirely (2). Studies show that it protects the liver, it acts as a powerful anti-inflammatory agent, protects health and proper functioning of the body, it acts as an appetizer, it reduces intestinal pain, reduces gas and bloating, vomiting, nausea, motion sickness, help to prevent cancer of the colon intestine and reduces the toxicity of certain food. It contains Gingerol, shogaol and zingerones which reduces muscle pain and soreness protect against Alzheimer disease, active ingredient in Ginger helps to fight infections (3, 4).

Because of all these basic functions the kidneys perform and the toxins they encounter the kidney are prone to various problems. Subsequently reliance on medicinal plants is progressively rising in developing countries (5, 6). Their roles as curing or preventing ailments are something no one can neglect, since it is necessary in ethnomedicine. The question is what are these herbal drugs? At what extents were they able to mitigate the hepato-renal toxicity? Are there comparative reports on the most effective method of drug administrations?

Regularly taking of certain over the counter medication such as non-steroidal anti-inflammatory drugs, can cause liver and kidney damage over time. (7).

Ginger as a medicinal/herbal plant possesses various physiological and pharmacologic activities such as anti-inflammatory, anti-ulcer, antifungal, antioxidant and antitoxic as shown in various studies. Generally it has been extensively used orthodoxy to cure virtually most of the ailments in the world by the traditional herbal users.

Additionally, in the absence of reliable kidney and liver protective and curative drugs in modern medicine; herbal drugs play a major role in the treatment of hepatic and renal disorders. Moreover, scientific literatures have prescribed various medicinal plants/herbs for the cure of hepatic and renal disorders which have curative properties due to the presence of various complex chemical substances possessing hepato-nephroprotective activities. There is dearth of

literature on the comparative, prophylactic and curative effects of this herbal drug on acetaminophen-induced liver and kidney damage.

Therefore this study was designed to ascertain the comparative prophylactic and curative effect of ginger supplement on acetaminophen induced liver and kidney damage.

## **2.0 Materials and Methods**

### **2.1 Procurement of Animals**

Twenty (20) healthy adult wistar rats weighing 185-220g were obtained from the animal house of the Department of Pharmacology of the University of Port Harcourt.

The rats were maintained under 12 hour's light-dark cycle. Rats were housed in polypropylene cages and fed with finishers' marsh. They were allowed free access to regular tap water *ad libitum*.

Rats were acclimatized for one week before the start of the study. Handling of experimental animals was in accordance with the National Institute of Health Guide for care and use of Laboratory Animals (8).

### **2.2 Drugs/Chemical**

Acetaminophen (APAP) capsules were purchased from Tuyil Pharmaceutical Industry Limited Ilorin, Nigeria.

Ginger (GINE) powder supplement was purchased from Nestins Global Link Limited Lagos, Nigeria.

### **2.3 Experimental Design:**

The prophylactic studies were done according to the method described previously by (9), with

slight modifications. This is where the animals were administered with the test drugs for a period of time before the administration of the toxin. Twenty (20) adult wistar rats were divided into six groups having 5 rats each (n=5). The powder supplements of the herbal drug were dissolved in distilled water.

The animals were fasted for twenty four hours, prior to the experiment under standard laboratory condition, but were allowed free access to water *ad libitum*. After 24 hours, group A which serves as normal control (NORC) received distilled water (0.5ml/kg) orally from the 1<sup>st</sup> day of the experiment to the seventh day. Acetaminophen (APAP) group which serves as negative control group received a single dose of acetaminophen (APAP) (1000mg/kg) dissolved in 5ml of distilled water orally for two days. Ginger (GINE+APAP) group, were given powdered ginger powder supplement dissolved in distilled water (500mg/kg) orally, Acetaminophen capsule dissolved in distilled water was given one hour after administering powder supplement orally for seven days (**Prophylactic group**).

APAP+GINE which served as **curative** group were administered with Acetaminophen only on day 1 and 2 and the drug supplement from day 3 to day 7 according to the method described by (Matthew *et al.*, 2011) with slight modification.

The weight of the animals was measured on the first, fourth, and seventh day of drugs and extracts administration respectively and dosage administrations adjusted according to changes in body weight.

Twenty four hours after drugs administrations the animals in each group were anaesthetized. Blood samples were collected. After blood samples collection, animals were sacrificed, liver and kidney tissues removed for histopathological tests (10, 11).

## 2.4 Biochemical Evaluation

All the rats were fasted for 12 hours at the end of the treatment period. The blood was collected

by cardiac puncture using sterile disposable syringes under mild chloroform anesthesia. Sera were separated out by centrifuging at 3000rpm for 10 minutes to get serum for Biochemical parameters study. The animals were then sacrificed by cervical and homogenized for histopathological studies.

### **2.5 Liver and Kidney Enzymes Assessment**

Using the standard liver enzymes Kidney biochemical assessment method, the serum collected was assayed. Liver enzymes assayed are; Alanine Aminotransferase (ALT), Alkaline Phosphatase (ALP) and Aspartate Aminotransferase (AST), Bilirubin, Total Protein, and Albumin levels. Kidney enzyme assessments like Creatinine, Blood Urea Nitrogen (BUN), and cholesterol. Blood Electrolyte such as sodium, potassium, chlorides was measured using the Hitachi 902, Automatic Chemical Analyzer.

### **2.6 Histopathology**

The liver tissue were dissected out and fixed in the 10% formalin, dehydrated in gradual ethanol cleared in Xylene and embedded in paraffin wax sectioned (50 $\mu$ m) with a rotary microtome and were stained with Haematoxylin and eosine (H&E).

The liver sections were evaluated histologically with light microscope with camera attached to it. The liver sections were scored and evaluated to the severity of the hepatic injury.

The kidney was freed from connective tissue coverings and gently removed, weighed and examined microscopically 3-5mm<sup>2</sup> thick pieces were excised from the organ and fixed in 10% formalin solutions, dehydration in ascending grades of alcohol (ethanol), cleared in xylene and embedded in paraffin. 50 $\mu$ m thick sections were obtained and subsequently stained with eosine and haematoxylin and PAS and examined under light microscope (5).

## **2.7 Antioxidant Studies/ Biomarkers**

Hepatic and Renal Antioxidant: GSH (Glutathione), SOD (Superoxide Dismutase), MDA (Malondialdehyde) and Catalase (CATA) were determined using method described by (18) in (19) with slight modification.

## **2.8 Statistical Analysis**

Statistical Analysis was conducted using Statistical package for Social Sciences (SPSS) version 16.0 (Chicago IL, USA) The mean value of data collected was represented as means, standard error of mean (S.E.M). The data were analyzed using one way analysis of Variance (ANOVA) and the difference between the groups was determined using Tukey's Post Hoc test. Statistical significant was set at the  $P < 0.05$  levels.

# **RESULTS AND DISCUSSION**

## **3.1 Effects of Extracts on Biochemical Parameters**

### **Effect on the Liver Enzymes**

The effect of the drugs on serum enzymes of APAP intoxicated rats is shown in Table 1

GINE +APAP treatments, insignificantly ( $P < 0.01$ ) decreased the levels of AST, ALP, ALT.

AST= (98.20-88.40), ALP (58.40-55.80), ALT (48.60-43.40) compared to negative control.

There was significant reduction in the ALP (58.40-36.00) APAP+GINE, ( $P < 0.05$ ).

Insignificant reduction in AST (98.20-90.80) compared to APAP GROUP

**Table 1: Effects of the supplements on the Liver Function**

| Groups       |              |              |              |            |            |             |             |
|--------------|--------------|--------------|--------------|------------|------------|-------------|-------------|
|              | AST (U/L)    | ALP (U/L)    | ALT (U/L)    | TP(g/L)    | ALB (g/L)  | TB (g/L)    | CB (μmol/l) |
| NORC(A)      | 57.20±3.99   | 37.00±2.07   | 27.00±2.03   | 63.40±3.54 | 38.40±0.98 | 5.34±0.25   | 4.36±0.42   |
| APAP (B)     | 98.20±5.77** | 58.40±2.38** | 48.60±2.82** | 65.40±2.52 | 37.80±0.86 | 7.60±0.57   | 3.98±0.42   |
| GINE+APAP(C) | 88.40±4.80** | 55.80±3.97** | 43.40±2.42*  | 61.00±0.45 | 39.40±1.36 | 6.98±0.38   | 3.86±0.33   |
| APAP+GINE(D) | 90.80±3.64** | 36.00±1.95   | 48.80±2.63** | 57.60±0.87 | 30.80±3.40 | 8.94±0.49** | 5.32±0.23   |

Values are given as mean ± SEM for 5 rats in each group; experimental groups are compared with Group A. \*p<0.05, \*\*p<0.01 vs Group B. P: statistical level of significance as determined by one-way Analysis of Variance (ANOVA) followed by Tukey's post-hoc test

### 3.2 Effect on the Kidney Biochemistry

Table 2 showed that, there was significant (98.40-130.00) elevation in creatinine level on the kidney biomarkers of the group administered with APAP compared to normal control.

In (GINE+APAP) group, there was significant (P<0.05) reduction in creatinine level (130.00-115.20) compared to negative control.

**Table 2: Effect on Kidney biochemistry parameter**

| Groups       |            |           |          |              |             |            |
|--------------|------------|-----------|----------|--------------|-------------|------------|
|              | Sodium     | Potassium | Urea     | Creatinine   | Cholesterol | Chloride   |
| NORC(A)      | 113.80±4.5 | 5.42±0.27 | 2.74±0.3 | 98.40±4.70   | 42.00±2.78  | 26.20±3.1  |
| APAP (B)     | 142.20±88  | 7.58±10.4 | 4.68±0.2 | 130.00±6.1*  | 49.20±1.24  | 26.80±1.2  |
| GINE+APAP(C) | 140.60±84  | 6.70±0.89 | 3.68±0.6 | 115.20±9.92  | 52.20±1.6*  | 26.80±1.6  |
| APAP+GINE(D) | 117.00±20  | 4.26±0.20 | 4.50±0.9 | 127.80±9.53* | 39.20±2.18  | 26.80±1.36 |

Values are given as mean  $\pm$  SEM for 5 rats in each group; experimental groups are compared with Group A. \* $p < 0.05$ , \*\* $p < 0.01$  vs Group B.

### 3.3 Effects of Different Extracts on the Liver Anti-Oxidant Parameter

Prophylactically, administration of drugs in all treated groups caused a significant ( $P < 0.01$ ) differences in hepatic CAT and GSH in the liver antioxidant parameters in comparison with normal control but curatively there was significant increase (0.43-1.80) catalase in comparison to APAP. As illustrated in table 3

**Table 3. Effect of the supplement extract on Liver biomarkers**

| Groups        |                   |                  |                 |                   |
|---------------|-------------------|------------------|-----------------|-------------------|
|               | CATA              | SOD              | MDA             | GSH               |
| NORC (A)      | 1.83 $\pm$ 0.53   | 0.56 $\pm$ 0.12  | 0.39 $\pm$ 0.09 | 1.46 $\pm$ 0.09   |
| APAP (B)      | 0.43 $\pm$ 0.08** | 0.57 $\pm$ 0.05  | 0.34 $\pm$ 0.05 | 0.29 $\pm$ 0.03** |
| GINE+APAP(C)  | 0.31 $\pm$ 0.02** | 0.49 $\pm$ 0.05  | 0.51 $\pm$ 0.05 | 0.37 $\pm$ 0.02** |
| APAP+GINE (D) | 1.80 $\pm$ 0.29   | 0.92 $\pm$ 0.02* | 0.27 $\pm$ 0.03 | 0.39 $\pm$ 0.03** |

Values are given as mean  $\pm$  SEM for 5 rats in each group; experimental groups are compared with Group A. \* $p < 0.05$ , \*\* $p < 0.01$  vs Group B. P: statistical level of significance as determined by one-way Analysis of Variance (ANOVA) followed by Tukey's post-hoc test

### 3.4 Effect on Renal Antioxidant Biomarkers.

Table 4 shows the effects of drugs administration on renal antioxidant.

Treatments in all the groups showed significant ( $P < 0.01$ ) reduction in the level of renal CAT and renal GSH compared to normal control group.

**Table 4: Effect on Renal Antioxidant Biomarkers.**

| Groups |
|--------|
|--------|



|               | CATA        | SOD       | MDA       | GSH         |
|---------------|-------------|-----------|-----------|-------------|
| NORC (A)      | 1.32±0.11   | 0.31±0.05 | 0.70±0.05 | 1.11±0.06   |
| APAP ( B)     | 0.64±0.09** | 0.37±0.07 | 0.57±0.08 | 0.39±0.01** |
| GINE+APAP(C)  | 0.48±0.10** | 0.35±0.06 | 0.60±0.05 | 0.38±0.01** |
| APAP+GINE (D) | 0.38±0.07** | 0.33±0.04 | 0.71±0.03 | 0.46±0.03** |

Values are given as mean ± SEM for 5 rats in each group; experimental groups are compared with Group A. \*p<0.05, \*\*p<0.01 vs Group B. P: statistical level of significance as determined by one-way Analysis of Variance (ANOVA) followed by Tukey's post-hoc test

### 3.5 Effects on Initial and Final effects on the Mean body Weight of Rats

Though there was weight gain but there were no significant (P>0.05) changes in the body weight of the treated rats in all the groups rather there appear to be general increase in weight of the rats as compared to group A and B. As shown in Table 5.

**Table 5: Effects of the Extracts on the Mean Body Weight of Rats**

| Groups       |                     |                   |
|--------------|---------------------|-------------------|
|              | Initial body weight | Final body weight |
| NORC (A)     | 133.60±6.61         | 139.00±9.34       |
| APAP ( B)    | 105.00±4.28         | 128.00±4.62       |
| GINE+APAP(C) | 96.20±6.39          | 114.80±5.95       |

Values are given as mean  $\pm$  SEM for 5 rats in each group; experimental groups are compared with Group A. No significant difference compared to Group A at  $p < 0.05$ . P: statistical level of significance as determined by one-way Analysis of Variance (ANOVA) followed by Tukey's post-hoc test

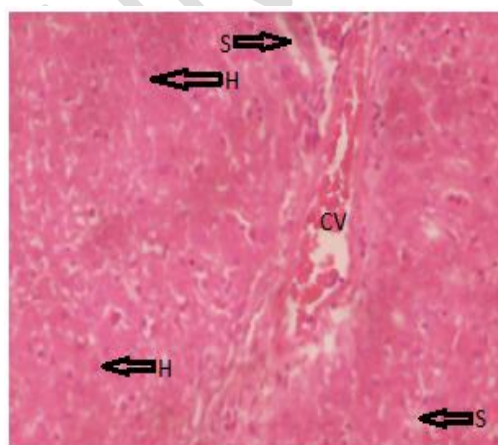
### 3.6 Effects on Hepatic Histology

The hepatic tissues of the experimental animals are illustrated histologically in the photomicrographs presented in plates (1-4). Plates 1 illustrated histologically normal liver showing: hepatocytes (H) that are histologically good. There was present of central vein (CV) containing blood cells, hepatic sinusoids; that are histologically normal as shown in plate 1.

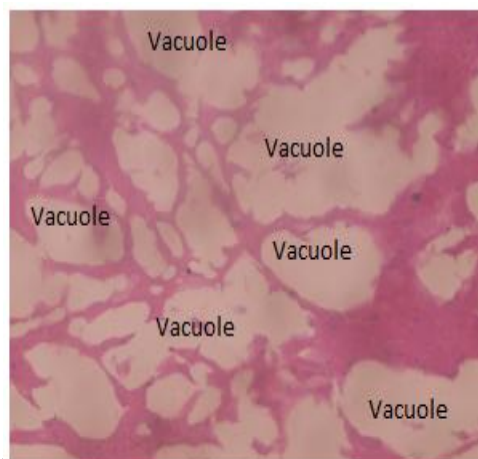
APAP treated rats groups as illustrated in plate 2 (B1b) indicated distorted tissue and deteriorated cords of hepatocytes, sinusoids, central vein and portal triad.

GINE+ APAP treated rats group as illustrated in plate 3 (C1b) indicated generalized vacuolation replacing the entire histology of the liver.

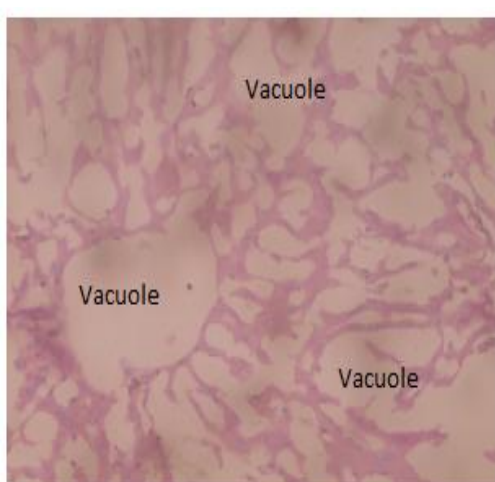
The liver tissue of group (APAP +GINE) treated rats group as illustrated in plate 4 (G3b) showed distorted liver tissue with generalized vacuolations with narrow lines of normal hepatocytes.



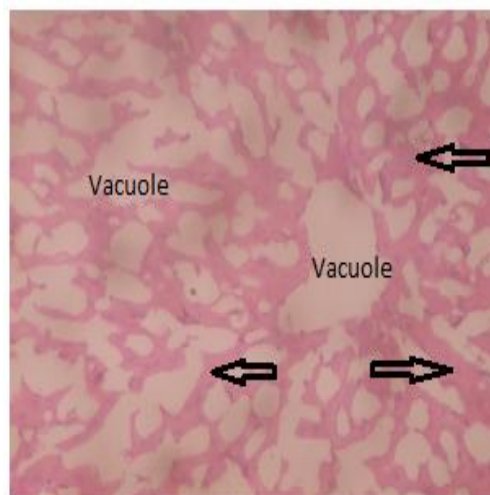
A2b



B1b



C1b



G3b

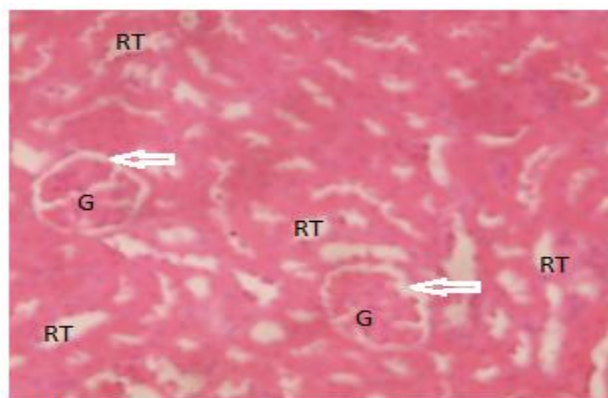
Plate 1-4: histopathological photomicrographs of liver tissues of rats treated with acetaminophen after different extracts treatment (\*400). (A1b) Normal control, (B1b) Acetaminophen (negative control), (C2b) Ginger (prophylactic) (G3b) Ginger (curative).

The kidney section of the control group in plate 5 (NORC), showed histologically normal renal tubules.

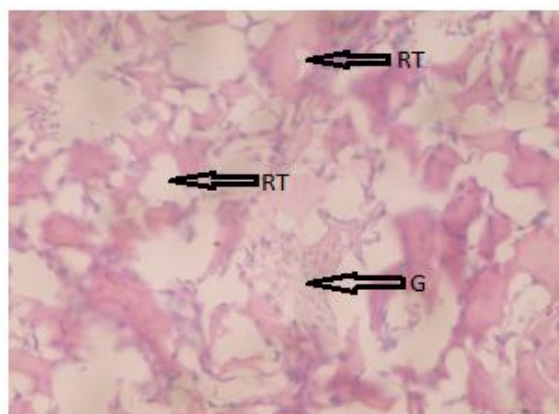
Kidney section of APAP group in plate 6 (B1b) showed kidney sections with severe distortion of the renal tubules, and shrinkage of glomeruli. Kidney sections of the rats in

GINE+APAP group as shown in plate 7 (C2b) showed distorted renal tubules that have basis features of renal tubules, distorted glomeruli, and glomerular tufts are not clearly seen, with

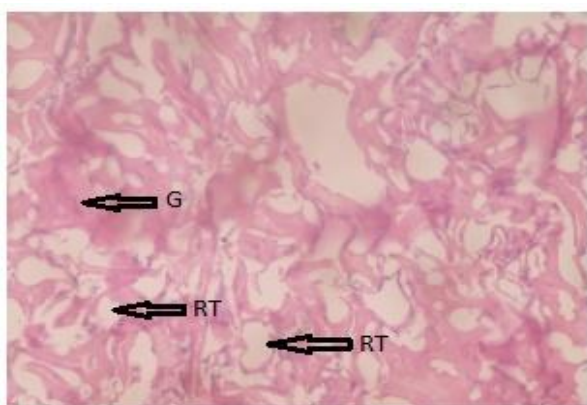
obliterated bowman corpuscles. Kidney sections of APAP+GINE groups in (plate 8 (Gib) indicated distorted kidney renal tubules (RT) with some preserved features and distorted glomeruli (G) with sparsely distributed preserved glomeruli.



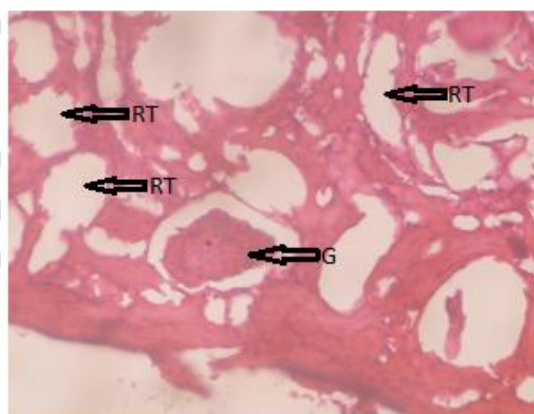
A1b



B1b



C2b



G1b

Plates 5-8: Histopathological photomicrographs of Kidney tissues of rats treated with acetaminophen after Ginger extract supplement treatment (x400). (A1b) Normal control, (B1b) Acetaminophen (negative control), (G1b) Ginger (prophylactic), (G1b) Ginger (curative)

## DISCUSSION

### 4.1 Prophylactic Studies

Abuse of Acetaminophen, causes a large amount of APAP to generate cytochrome P450 enzymes Cyp2e1 in rats, leading to the formation of reactive metabolite N-acetyl P-benzoquinoneimine (NAPQI), thereby resulting in the saturation of the hepatic glucuronide and sulphate, then increasing the P450 sulphate conjugation pathway, triggering the oxidation pathway (12, 13, 14).

Damage to or effect on target organs often results in increase in clinical chemistry parameters. Such as ALP, AST, ALT (liver) Urea and creatinine (kidney) increase in levels of the serum creatinine and urea had been considered as index of assessing nephrotoxicity. Severity of the kidney damage is caused by the paracetamol (15). In the present study, the ability of Ginger supplement to protect or cure drug- induced hepato-renal toxicity was assessed.

The rise in the levels of alanine amino transferase (ALT), aspartate aminotransferase (AST) and alkaline phosphatase (ALP) activities in the serum were used to measure liver damage while rise in the blood urea nitrogen and creatinine were used to measure the level of damage to the kidney. Therefore, serum hepatic biomarkers analysis is important for identification of liver damage (16). In this work, high level of AST and ALT was shown which indicated that AST and ALT were released into circulation indicating liver damage. Rise in AST and ALT (is a more specific marker of liver damage) showing cellular leakage and loss of functional cohesion of parenchyma cell in the liver.

Acetaminophen overdose or abuse results in permanent obliteration of liver cells in turn resulting in alarming and absolute high elevation in serum level of enzymes ALT, ALP, and AST (17). This is in agreement with (18, 19) who reported that paracetamol intoxication produced a significant increase in AST, ALT ALP. In our work, APAP administration (1000mg/kg) caused acute liver injury in rats, characterized by an increase in serum activity of transaminase and phosphatases (AST, ALT and ALP).

This is also similar to (20, 21) who reported that acetaminophen administration produced a significant rise in liver enzymes and this leakage of enzymes is due to hepatotoxicity which caused the alteration of the activity of the liver function.

When there is damage of cell, cytoplasmic transaminase will be released thereby leading to the damage of the liver structure binding, because these are normally located on the cytoplasm, mitochondrial and microsome released into the circulation after cellular damage (2) or due to the

alteration to the cell membrane permeability, increase anabolism and reduction in breaking down of amino transferase. This is also in agreement with (22) who found out that serum levels of both ALT and AST were elevated almost four folds in acetaminophen treated group in relation to control. Decrease in serum, plasma level of total protein, albumin is also the evidence of chronic liver damage.

Similar to our work, <sup>23</sup> reported that acute acetaminophen toxicity induced remarkable elevation on plasma ALT, AST and ALP action and significantly decline in plasma level of total protein and albumin of rats. It is also in agreement with (24) who revealed that acetaminophen induced toxic injury on the liver of rats as seen by significant decrease in albumin level. This indicated the decrease in capacity of hepatic to synthesize protein and consequently liver weight.

The present study also revealed that administration of GINE+APAP. Ginger caused no significant decrease in serum levels of liver enzymes in prophylactic group relative to APAP group showing the near normal restoration of damaged liver enzymes decrease in the liver enzymes levels triggered by APAP administration.

This result slightly disagreed with (24) who reported that administration of ginger 100mg/kg to paracetamol (1000mg/kg) intoxicated rats showed decrease in serum albumin as compared to paracetamol group. The different in our result can be as a result of different in dosage of ginger. Prophylactically, ginger could not protect against APAP toxic effects on the liver. This is in tune with (25) who reported that ginger failed to restore the damaged liver cell and reduced serum albumin indicating severe liver damage. This may be due to the ability of the ginger to increase gastrointestinal absorption of APAP because some active compounds of ginger were reported to stimulate digestion, absorption, relieved constipation and flatulence by increasing muscular activity in the digestive tract. Also<sup>23</sup> reversibly reported lowered hepatic marker enzymes and restoration of the level of protein. This may also be due to differences in doses concentration of

GINE+APAP, time dependant and different route of exposure. This may also be due to different drugs interactions.

Administration of APAP to the rats in our result reviewed that acetaminophen caused elevation in serum blood urea nitrogen and serum creatinine level indicating kidney damage. Our findings were in line with an earlier reported work of (26, 15) that sera levels of creatinine and urea in kidney diseases will rise because the rate of production exceeds the rate of clearance due to the defect in kidney function and these elevated state of urea and creatinine had been considered as guide of assessing nephrotoxicity, supporting to this, the disturbance of the renal functions was further reflected on its faulty re-absorptive power of albumin and protein in plasma levels, which led to their facade in high quantities in the urine and thus decreased in sera levels (20).

In addition, attenuation of total protein and albumin associated with improved serum urea and creatinine was a further indication of kidney glomerular damage after APAP injection (27). Thus, significant rise in creatinine level in the present study confirmed renal damage in rats following APAP overdose. A previous study shows that elevations in the urea and creatinine plasma levels have been demonstrated to the cause of renal disease in a range of animal models and man (15).

Ginger extract supplement exert its antioxidant effect by quenching free radicals due to the effect of polyphenol compounds (6 Gingerols and its derivatives).

In the APAP treated group, the liver tissue as illustrated in Plates 2 showed distorted and destroyed liver with vacuolation. This is in consistent with (28) who reported ballooning and degeneration as well as sinusoidal congestion of the liver 24 hours after APAP administration. This also agreed with (20) who reported that in paracetamol treated group, there was distortion of liver architecture, there were also vacuolation of hepatocytes, infiltration with inflammatory cells, Cellular protein after covalent bonding of acetaminophen and its metabolites might trigger

some series of events which resulted to liver damage. This is in line with our result which showed vacuolated hepatocytes, distorted liver and sinusoidal.

Liver architecture of the rats treated with Ginger (GINE+APAP) after acetaminophen administration as shown in Plates 3, in prophylactic use also indicated distorted liver tissue and vacuolation. The prophylactic effects may be due to swift absorption of both acetaminophen and Ginger in the liver tissue. This is similar to (29) who used lead as toxicant, when treated with Ginger showed regenerated nucleated hepatocytes arranged in cord with obvious sinusoidal arrays, minimal fat vacuoles and minimal inflammatory lymphocytic infiltrations.

The photomicrographs of the renal tissues of the experimental animals when illustrated histologically in plate 5-8. The kidney of the control groups shows glomerular surrounded with bowman capsules and renal tubules of control groups.

Hence, in kidney sections APAP as illustrated in plate 6 caused severe changes in renal cells, distorted renal tubules and glomerular. This is similar to (10) who reported toxic effects of APAP on the kidney. This report also agreed with (13) who reported that kidney sections of APAP treated group caused severe alterations in renal cells. (12) also reported disorganized glomerulus, dilated and inflammatory tubules. Kidney tissue of the rats treated with Ginger in prophylactic use (GINE+ APAP) as illustrated in plate.3 (C1b) showed indistinct glomerular.

This was in disagreement with earlier report by (30) that aqueous extract of Ginger has therapeutic potential against APAP induced renal injury in rats by ameliorating the kidney histopathological structure and thus improved the kidney function. This may be due the fact that Ginger and acetaminophen are easily absorbed by the body thus their rapid absorption.

#### **4.2 Curative Studies**

There was also significant increase in ALT and AST levels indicating liver damage and also insignificant decrease in ALP level in curative group indicating the near normal restoration of



liver enzymes. The insignificant effect in the activities of ALT and AST is dissimilar to (25, 31) which reported that administration of Ginger and paracetamol significantly decrease serum ALT and AST as compared to paracetamol. Ginger powder supplement unleash their antioxidant effect by scavenging free radicals due to its antioxidant called 6- Gingerols and derivatives free radicals (Gingerol, flavonoids, flavones, glycosides and rutin).

In our work, administration of Ginger after acetaminophen administration causes reduction in liver enzymes, Total protein and Albumin compared to B as observed curatively. This is also in consonant with the work of (31) who reported that APAP +GINE oral administration were able to decrease the level of ALP. There was also significant decreased in cholesterol levels compared to APAP group. This is in agreement with (31) who reported that Ginger can lower cholesterol level.

In the kidney function test, treatment of rats with Ginger insignificantly reduced the elevated level of creatinine caused by Acetaminophen. Ginger might possessed the antioxidant characteristics which might have reduce or slow down the spread of the rate of nephrotoxic thereby delaying the on-set of renal damage or stop the effects entirely.

The serum level of total protein, albumin and total bilirubin was also measured. There was significant increase in serum total bilirubin in relation to APAP. In contrast with (23) who reported restoration in total bilirubin after being treated with ginger supplement. The dissimilarity in the result may be due to different in dosages.

Hepatic CAT in Ginger curative was almost closer to normal control group. This is in agreement with (32) who reported that Ginger restored antioxidant levels and decrease hepatic MDA in acetic acid induced colitis in rats.

Administration of APAP + GINE has negative effect on the hepatic GSH antioxidant and this

reduction in hepatic GSH may be due to the interaction of herb and drug (2).

APAP+GINE) plate 4, the liver tissue showed normal lines of normal hepatocytes and ability to show normal line of hepatocytes in curative use indicated present of antioxidants

Then curatively, (29) also reported that the structural organization of the liver appeared almost normal with distinct hepatocytes having regeneration of central vein. This indicated that APAP+GINE rats' livers are well protected from APAP toxicity when compared to APAP rats' liver (plate 4).

The renal architecture of rats treated with APAP indicated destroyed renal tubules and shrinkage of glomeruli (plate 6) indicating total destruction of the kidney structure. This is in agreement with (12) who reported disorganized glomerulus, dilated and inflammatory tubules.

(APAP+GINE) there were some preserved features shown with sparsely distributed glomeruli as shown in plate 8. This was also reported by (30) that aqueous extract of Ginger has curative potential against APAP induced renal injury in rats by ameliorating the kidney histopathological structure and thus improved the kidney function. Thus this indicated the antioxidant properties of Ginger.

## CONCLUSION

The study concluded that the ginger administrations is preferably prophylactically in liver and kidney biochemistry, in hepatic antioxidant and histopathological examinations, ginger supplement administrations are preferable in curative uses. Conclusively, the supplement drug was comparable to normal control in protection and treatment of liver and kidney damage caused

by acetaminophen intoxication.

## REFERENCES

1. Kaplowitz N & Laurie. Drug-Induced Liver Disease (3<sup>rd</sup> edition).Elsevier Incorporated. New York, 2013
2. Mohammad S I, Mustafa IA, Abdulqader SZ. Ameliorative Effects of Aqueous Extract of *Zingiber officinale* on the Cadmium- Induced Liver and Kidney Injury in Female Rats. *Jordan Journal of Biological Sciences*.2013; 6(3): 231-234.
3. Shalaby M A and Hamowieh A R. Pharmacological studies on ginger- Pharmacological actions of pungent constituents of 6-gingerol and 6-shogaol. *Journal of Pharmacobiodyn*, 2010; 7,836848.<https://www.ncbi.nlm.nih.gov/pubmed/6335723>
4. Leach J. 11 proven health benefits of ginger [www.healthcare .com](http://www.healthcare.com).2017
5. Abere TA, Okoto PE, Agoreyo FO. Antidiarrhoea and Toxicological Evaluation of the leaf Extract of *Dissotis rotundifolia* Triana (Melastomatacea). *BMC Complement Alternative Medicine*. 2010; 10:71
6. Odo GE, Avoaja DA, Ivoke N, Debua U EM, Onyeke CC, Ajugwu CG et al. Effects of Ethanolic Extracts of *Pentaclethra macrophylla* Leaves in Experimentally Induced Diarrhoea in Albino Rats (*Rattus novengicus*) *Internationals Journal of Indigenous Medicinal Plant*, 2013; 46. 1376-1385
7. Mazhar F, Akram S. Acute Renal Damage in Acetaminophen poisoning. *Journal of Young Pharmacology*, 2016; 8(4): 505-506.
8. Clark DJ, Gebhart GF, Gonder JC, Keeling ME, Kohn D.F. The 1996 Guide for the Care of Laboratory Animals. *Institute for Laboratory Animals Research Journal*, 1997; 3(1):41-48
9. Daszeasah PEA. Safety evaluation and Hepatoprotective Activity of the Aqueous Stem Bark Extract of *Spathodeacampanulata*. An unpublished Thesis. Kwame Nkurumah

- University of Science and Technology, Kumasi; 2012
10. Gulnaz, H., Tahir, M., Mumir, B and Sami, W. (2010). Protective effects of garlic oil on Acetaminophen-induced nephrotoxicity in male albino rats. *Biomedical*, 26 (7): 9-15
  11. Mahmoud M F, Diaai AA, Ahmed F. Evaluation of the Efficacy of Ginger, Arabic Gum, and Boswellia in Acute and Chronic Renal failure. *Renal Failure*, 2012; 34,73-82. <http://doi.org/10.3109/0886022x.2011.623563>
  12. Abdul Hamid, Z S, Budin N, Jie A, Hamid K, Mohamed HJ. Nephroprotective effects of *Zingiber zerumbet* Smith ethyl acetate extract against paracetamol-induced nephrotoxicity and oxidative stress in rats. *Journal of Zhejiang University Science B*, 13, 2012, 176-185.
  13. El Badwi SM, Al Tayib OA. Assessment of ameliorative effects of aqueous extracts of *Moringa oleifera* on acetaminophen- induced nephrotoxicity in rats. *JOSR Journal of Humanities and Social Sciences (LOSR-JHSS)*, 2016; 21(9): 1-7
  14. Guengerich P. Mechanism of Cytochrome P450 Catalyzed Oxidations. *National Center for Biotechnology*. 2016; 8(12):10964-10976
  15. Pathan M.M, Khan MA, Moregaonkar SD, Somkuwar AP & Gaikwad NZ. Amelioration of Paracetamol- Induced Nephrotoxicity by *Maytenusemarginata* in Male Wistar Rats. *International Journal of Pharmacy and Pharmaceutical Sciences*, 2013; 5(4):471-474
  16. Al-Qudah M M.A, Haddad M A, EL-Qudah J M F. The effects of aqueous ginger extract on pancreas histology and on blood glucose in normal and alloxan monohydrate-induced diabetic rats. *Biomed Res.*, 27, 350-356. [https://www.researchgate.net/publication/301649907\\_The\\_effects\\_of\\_aqueous](https://www.researchgate.net/publication/301649907_The_effects_of_aqueous) ;2016
  17. Senders P. Causes of high liver enzyme test (ALT, AST and ALP). Explain- Health.com, 2011
  18. Mathew C, Nair C, Shenoy T, Varghese J. Preventive and curative effects of *Acalypha indica* on acetaminophen induced hepatotoxicity. *International Journal of Green Pharmacy*; 2011; 49-54.
  19. Subramaya S, Venkataraman B, Meeran MFN, Goyal SN, Patil CR & Shreesh O. (2019). Therapeutic Potential of Plants and Plant derived Phytochemicals against Acetaminophen

- Induced Liver Injury. *International Journal of molecular Sciences*, 2019; 19, 3776-3918(43 pages)
20. Masoud RE. Hepatoprotective effect of curcumin versus silymarin on paracetamol induced hepatotoxicity in rats. *International Journal of Pharmacology and Biological Sciences*, 2017; 8(2): 134-141.
  21. Mingzhi Y, Hongbo H. Mechanisms of Acetaminophen-induced liver injury and its implications for therapeutic interventions. *Redox Biology*, 2018; 17:274-283
  22. Elkott AF, El-Sayed S M, Abdel- Aziz A M. The effects of Ginger (*Zingiber officinale*) on histology and immunohistochemistry of liver and kidney and certain haematological parameters in Alloxan- induced Diabetic rats. *Egypt Journal of Experimental Biology (zoology)*, 2018; 6(1):61-70.
  23. Abdel-Azeem, A.S, Hegazu A.M, Abraham K, Mahmud A, El-Sayed H. Hepatoprotective, Antioxidant, and ameliorative Effects of Ginger (*Zinger officinale* Roscoe) and Vitamin E in Acetaminophen treated Rats. *Journal of Dietary Supplement*, 2013; 10 (3): 195-209..
  24. Lebda MA, Nabil MT, Korshim M, Amandour AA, Goda RI. Ginger (*Zingiber officinale*) potentiates paracetamol induced chronic hepatotoxicity in rats. *Journal of Medicinal Plants Research*, 2013; 7(42): 3164-3170.
  25. Ibrahim T, Agnihotri TI Agnihotri AK. Paracetamol Toxicity: An Overview. *Emergency Medicine*, 2013; 3:158, 3 pages: open access.
  26. Badwi SM. Ameliorative effects of aqueous extracts of *Moringa oleifera* on acetaminophen- induced nephrotoxicity in rats. *Journal of Humanities and Social Sciences*, 2016; 12(9): 1-7
  27. Paliwal R, Sharma V, Precheta S, Yadav S, Sharma S. Anti-nephrotoxic effect of administration of moringa oleifera Lam in amelioration of DMBA induced renal carcinogenesis in swiss albino mice. *Biology and Medicine*, 2011; 3(2): 27-35
  28. Mannem P. Protective Effects of Ginger Extract against Lead Induced Hepatotoxicity in Male Albino Rats. *Journal of Environmental Sciences, Toxicology and Food Technology*, 2014; 8(5): 53-59.
  29. Hamed MA, Ali SA, El-Rigal N S. Therapeutic potential of ginger against renal injury induced by carbon tetrachloride in rats. *The Scientific World Journal, Article ID 840421*, 2012; s12 pages, <http://doi.org/10.1100/2012/840421>

30. Eugenio-Perez. Role of food-derived anti-oxidant agents against Acetaminophen-induced hepatotoxicity. *Pharmaceutical Biology*, 2016; 54(10): 2340-2352
31. Murad S, Nlaz K and Aslam H. Effect of Ginger on LDL-C, Total Cholesterol, Body weight. *Clinical Medicine Biochemistry*.2018; 4:140-142
32. Elmasry A, Daba MH, El-Karet AA. Possible effects of *Moringa oleifera* versus Ginger (*Zingiber officinale*) on experimental colitis in mice. *British Journal of Medicine and Medical Research*, 2016; 16(2):1-19

UNDER PEER REVIEW