

Hydatidiform Mole Coexisting with Healthy and Alive Fetus at Birth: Case Report in Mexico

ABSTRACT

Aims: Describe a case of hydatidiform mole coexisting with healthy and alive fetus at birth in Mexico.

Presentation of case: A 35 years old patient, pregnant at 18.5 weeks of gestational age and a viable fetus by ultrasound, with atypical pneumonia, plus scant bilateral pleural effusion and partial mole implants on admission to hospital. At week 39 of gestation, the pregnancy was interrupted abdominally; a fourth gestation product was obtained, alive, female, and without malformations. The patient did not present complications. The histopathological report of the placenta was compatible with a partial mole.

Discussion: Gestational trophoblastic disease includes partial hydatidiform mole, its occurrence in coexistence with alive and healthy fetus at birth is 0.005-0.01% respect to the total number of pregnancies. The viability of the term of pregnancy will depend on maternal comorbidities, fetal well-being and accessible medical surveillance. The ultrasound is the main diagnostic tool. Clinical monitoring is of vital importance after the end of pregnancy, mainly in mother, due to the risk of developing metastatic disease and recurrence of molar pregnancy.

Conclusion: The case report described is relevant, due to its infrequency. In addition, the imaging findings, emphasizes the importance of a complete and adequate evaluation of the placenta and the fetus, in viable gestation conditions in coexistence with partial mole.

Keywords: gestational trophoblastic disease, maternal health, perinatal health, placental abnormalities.

1. INTRODUCTION

In gestational trophoblastic disease, one of the less common entities is the coexistence of a partial hydatidiform mole with a healthy, alive fetus at birth [1]. This condition occurs between 0.005-0.01% respect to the total number of pregnancies [2, 3]. It usually happens sporadically, having a multifactorial etiology [4].

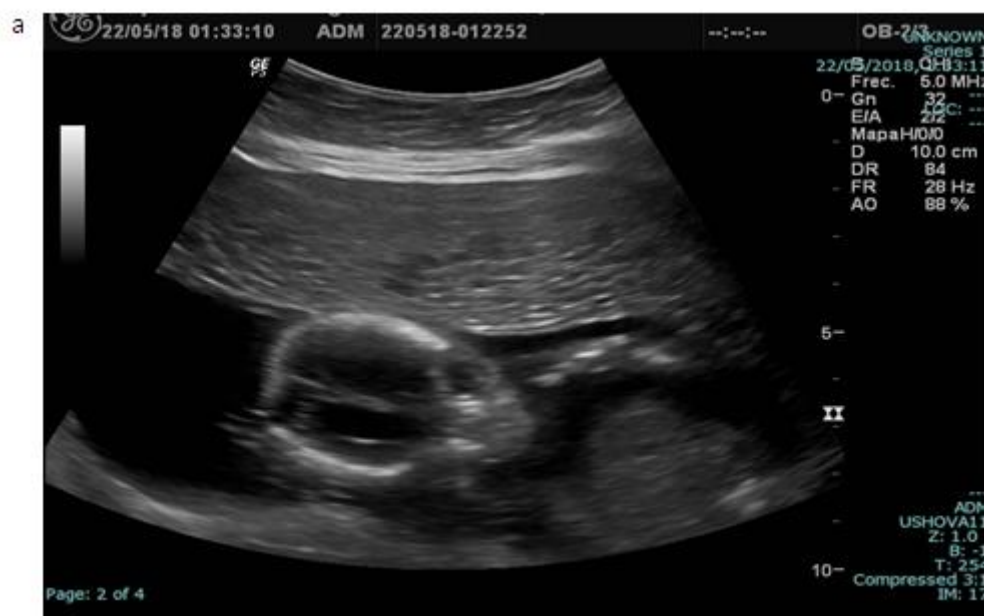The serious risks and complications that can occur during pregnancy, before and after delivery [5] require a timely differential diagnosis, providing the basis to proper management and follow-up. The objective of the present work is to describe a case of hydatidiform mole that coexists with alive and healthy fetus at birth in Mexico.

2. PRESENTATION OF CASE

35-years old female patient, pregnant, without prenatal control, intake folic acid, ferrous fumarate or immunizations, who initially attended to General Hospital "La Piedad" in La Piedad de Cavada, Michoacan, Mexico on May 18, 2018. She had an intense headache of

frontal location with eight days of evolution, unquantified febrile picture, dyspnea when performing minimal physical effort; and denying abdominal pain or transvaginal leakage. She was hospitalized for four days due to a probable infectious focus of a pulmonary location. However, she was sent to General Hospital "Dr. Miguel Silva" from Morelia, Michoacan, Mexico on May 22, 2018, due to lack of improvement, and increased hypoxemia. The patient at admission indicated by interview: complete primary education, married, housewife, with no chronic degenerative family history, drug addiction, relevant infectious disease or neoplasms. Likewise, menarche at 14 years, beginning of active sexual life at 17 years, a sexual partner, without use of contraceptive methods, negative pap smear for malignancy in 2017, pregnancy: four, and childbirth: three.

A chest x-ray confirmed an infectious pulmonary process, which is treated. In the obstetric ultrasound, multiple circumscribed, round intraplacental lesions, typical of partial mole, were observed; without apparent fetal alterations and a gestational age of 18.5 weeks (Fig. 1).



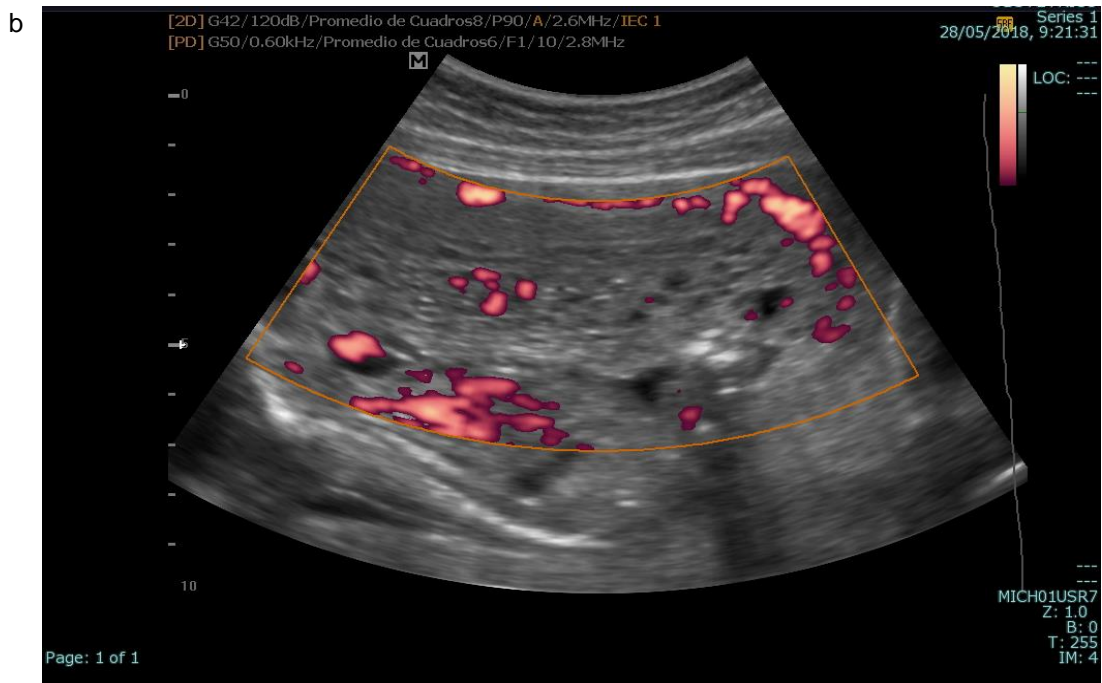


Fig. 1. Ultrasound image performed on May 22, 2018, demonstrating alive and healthy fetus with 18.5 weeks of gestation, as well as parts of the molar tissue (a); color doppler performed on May 28, 2018 showing partial mole (b).

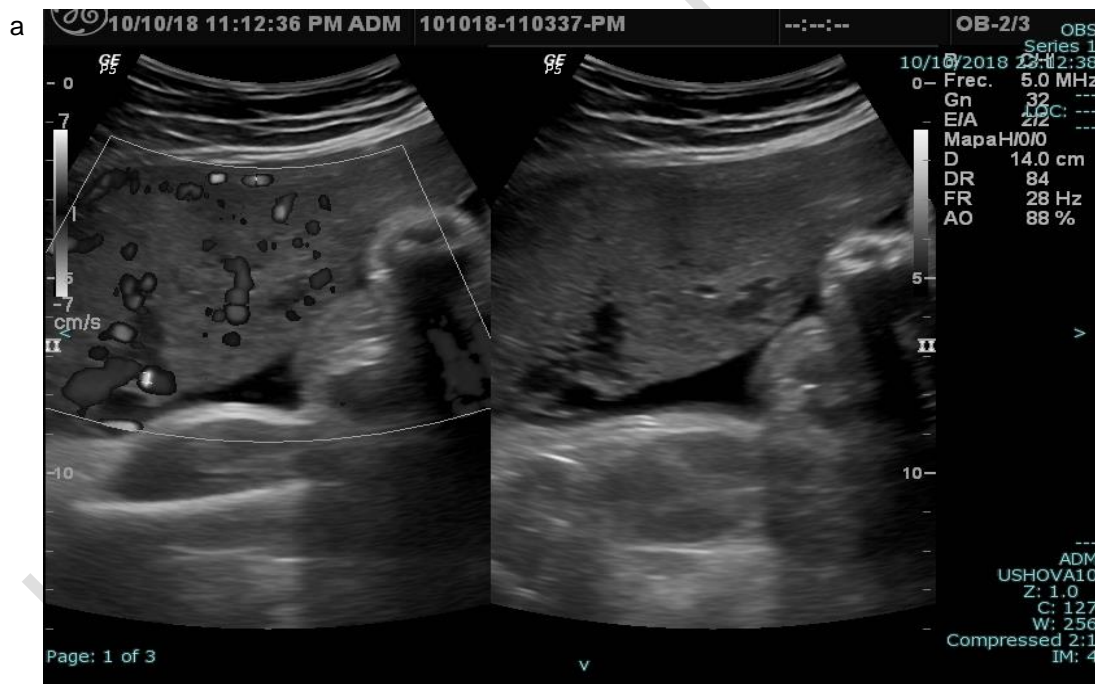The results of hematic biometry, lipid profile, and general urine were found in normal ranges. The liver and blood chemistry tests are shown in Table 1, in which minimal alterations are observed. Negative to hepatitis B and C antibodies, as well as HIV. Two quantifications of β -HCG were carried out, registering values of 18,261 and 15,801 mIU/ml. On June 1, 2018, he was discharged due to an improvement in his respiratory condition.

Table 1. Blood chemistry and liver function tests during hospitalization.

Clinical study	Date and time of sampling			
	22-05-2018 01:52 a.m.	23-05-2018 07:55 a.m.	23-05-2018 05:54 p.m.	24-05-2018 07:46 a.m.
Blood chemistry				
Glucose (mg/dL)	66	60	73	69
Urea (mg/dL)	10.1	11.6	8.7	8.5
Blood urea nitrogen-BUN (mg/dL)	4.7	5.4	4.1	4.0
Glomerular filtration rate (mL/min)	133.22	137.68	140.15	137.68
Serum creatinine (mg/dL)	0.42	0.38	0.36	0.38
Uric acid (mg/dL)	2.31	1.20	1.20	1.50
Cholesterol (mg/dL)	-	-	-	150.5
Triglycerides (mg/dL)	-	-	-	466.20
Lactic dehydrogenase (UI/L)	-	-	-	899
Liver function tests				
Aspartate aminotransferase (U/L)	274	177	-	181

Alanine aminotransferase (U/L)	137	108	-	119
Alkaline phosphatase (U/L)	125.3	121.0	-	200.0
C-reactive protein (mg/L)	169.0	242.4	-	97.6
Total proteins (g/dL)	4.2	4.4	-	5.9
Albumin (g/dL)	2.1	2.0	-	2.8
Globulins (g/dL)	2.1	2.4	-	3.1
A/G ratio	1.0	0.8	-	0.9
Total bilirubin (mg/dL)	1.18	1.04	-	1.40
Direct bilirubin (mg/dL)	0.88	0.76	-	1.10
Indirect bilirubin (mg/dL)	0.30	0.28	-	0.30

The interruption of the pregnancy was carried out on October 10, 2018, via abdominal, with a gestational age of 39 weeks, and the patient's hemodynamic stability. By ultrasonographic tracing, the product presented, right back longitudinal cephalic position, a fetal heart rate of 145 L / m. An anterior corporal placenta was observed, with cystic areas and lacunar areas due to a partial mole (Fig. 2) in addition, a probable subchorionic hematoma measuring 6x7 cm. Alive newborn was obtained, female, 3,130 g, height 52 cm, cephalic perimeter 34 cm, thoracic of 33 cm, abdominal 31 cm, foot 8 cm, umbilical cord with three vessels, APGAR 8-9. The amniotic fluid was normal and the placenta was completely extracted, his histopathological report concludes a partial mole (Fig. 3).



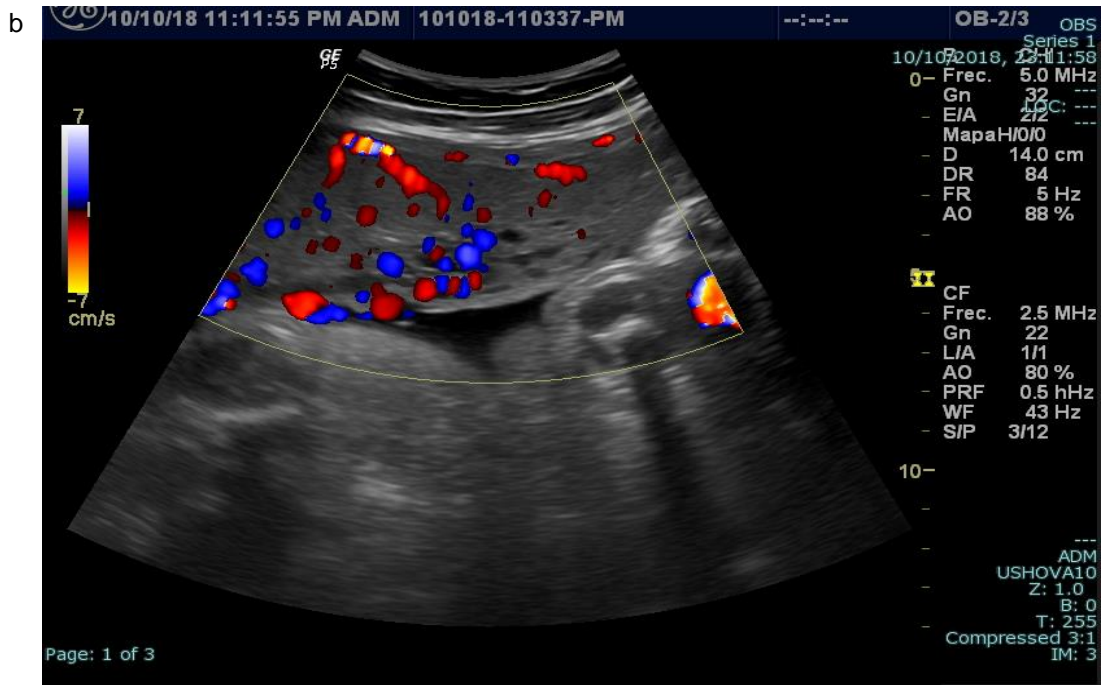
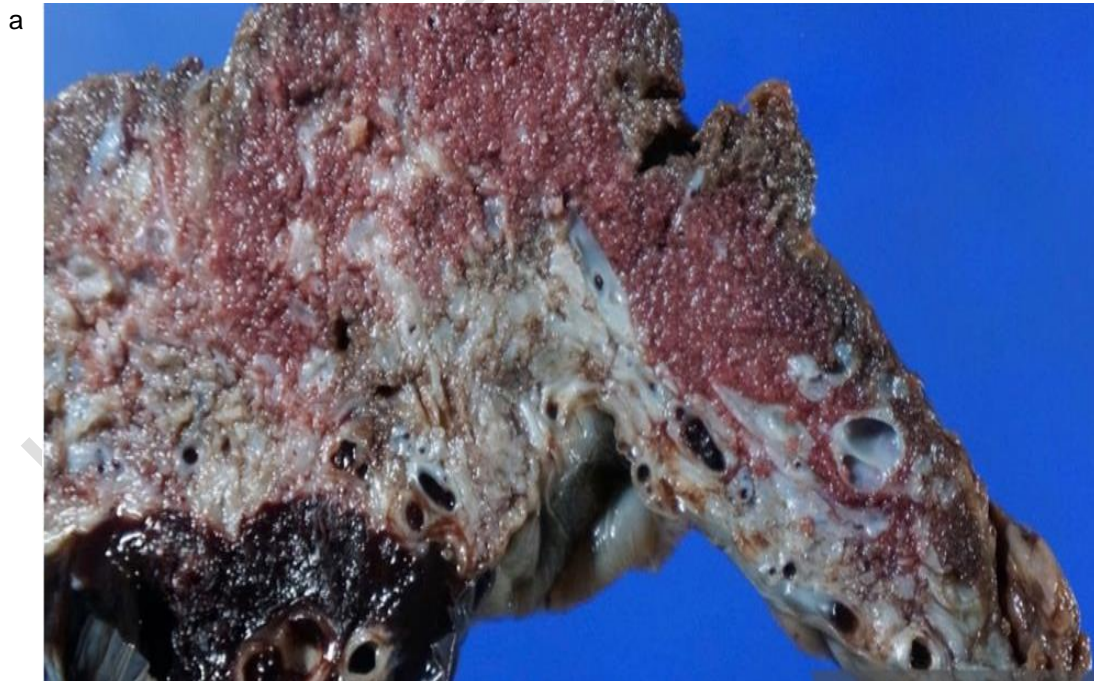


Fig. 2. Ultrasound images performed on October 10, 2018, showing a healthy and alive fetus with 39 weeks of gestation, as well as parts of the molar tissue (a) color doppler showing partial mole (b).



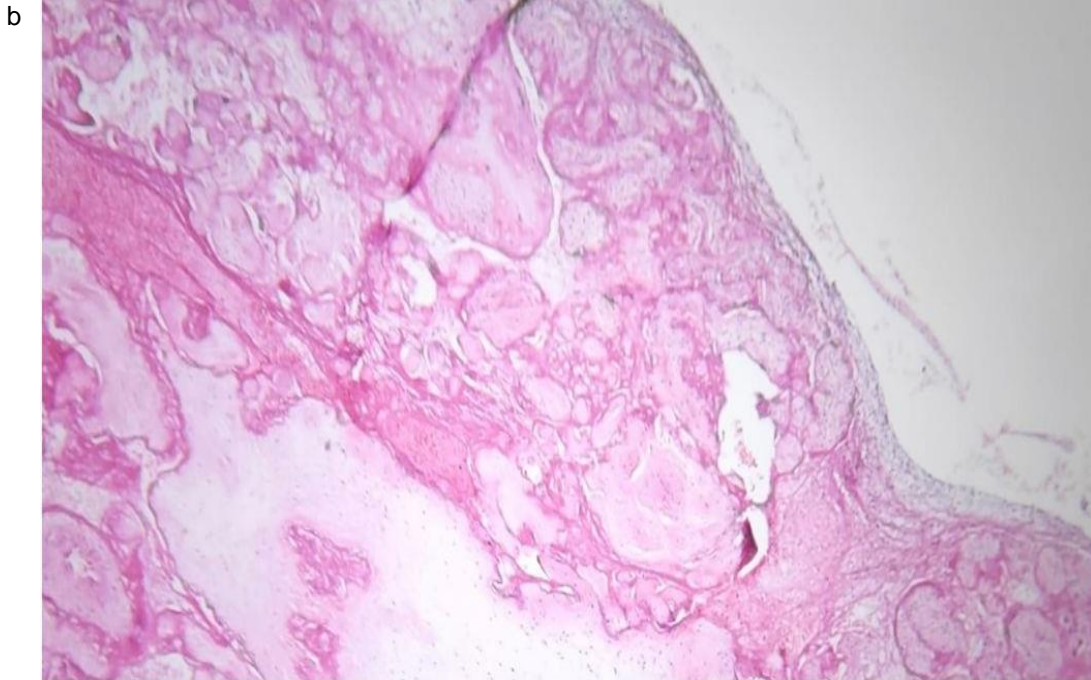


Fig. 3. Macroscopic (a) and microscopic (b) section of the placenta.

3. DISCUSSION

Gestational trophoblastic disease includes a large number of tumors that are interrelated, and with different propensities for local invasion and metastasis. Presenting as complete and partial hydatidiform mole, invasive mole, choriocarcinoma, placental site trophoblastic tumor, and epithelioid trophoblastic tumor [5, 6].

The incidence of gestational trophoblastic disease varies according to the geographical area [7], in Mexico it is estimated to be 2.4 per 1,000 pregnancies; in invasive mole 1 in 40 molar pregnancies, and in 1 in 150,000 normal pregnancies [8]. In the case of partial hydatidiform mole, its occurrence in coexistence with alive and healthy fetus at birth worldwide is between 0.005-0.01% with respect to the total number of pregnancies [2, 3].

Viability at term of pregnancy will depend on maternal comorbidities, fetal well-being and accessible medical surveillance [7] coinciding with the present case report, since the patient and the fetus did not develop complications. Carrying out clinical studies (hematic biometry, blood chemistry, liver function tests, β -HCG) during pregnancy are of vital importance [9, 10].

In addition to the follow-up of clinical studies, ultrasound is the main diagnostic tool to early and adequate identification of possible gestational trophoblastic disease [10]. Clinical follow-up has a vital importance after the end of pregnancy, mainly in mother, due to the risk of developing metastatic disease and recurrence of molar pregnancy. Therefore, the histopathological study of the placenta is a required [11].

4. CONCLUSION

The case report described is relevant, due to its infrequency, in addition the imaging findings, emphasizes the importance of a complete and adequate evaluation of the placenta

and the fetus in viable gestation conditions in coexistence with partial mole. The viability of the term of pregnancy will depend on maternal comorbidities, fetal well-being and accessible medical surveillance. Clinical monitoring is vital importance after the end of pregnancy, mainly in mother, due to the risk of developing metastatic disease and recurrence of molar pregnancy. Finally, it recommended to continue a research related to the subject, in order to provide alternatives that improve maternal and perinatal health.

CONSENT

All authors declare that written informed consent was obtained from the patient for publication of this case report and accompanying images.

ETHICAL APPROVAL

The research work was examined and approved by the hospital research and ethics committee.

REFERENCES

1. Uemura, N., Takai, Y., Mikami, Y., Ogasawara, M., Saitoh, M., Baba, K., et al. Molecular cytogenetic analysis of a hydatidiform mole with coexistent fetus: a case report. *Journal of medical case reports*. 2019;13(1):1-5.
2. De Franciscis, P., Schiattarella, A., Labriola, D., Tammaro, C., Messalli, E. M., La Mantia, E., et al. A partial molar pregnancy associated with a fetus with intrauterine growth restriction delivered at 31 weeks: A case report. *Journal of medical case reports*. 2019;13(1):1-5.
3. Atuk, F. A., Basuni, J. B. M. Molar pregnancy with normal viable fetus presenting with severe pre-eclampsia: a case report. *Journal of medical case reports*. 2018;12(1):1-3.
4. Nguyen, N. M. P., Bolze, P. A., Slim, R. Hydatidiform moles. In: Hashkes P., Laxer R., Simon A. (eds) *Textbook of Autoinflammation*. 2019;485-497. Springer, Cham. DOI: 10.1007/978-3-319-98605-0_27.
5. Lipi, L. B., Philp, L., Goodman, A. K. A challenging case of twin pregnancy with complete hydatidiform mole and co-existing normal live fetus—A case report and review of the literature. *Gynecologic oncology reports*. 2020;31:100519. DOI: 10.1016/j.gore.2019.100519.
6. Suksai, M., Suwanrath, C., Kor-Anantakul, O., Geater, A., Hanprasertpong, T., Atjimakul, T., Pichatechaiyoot, A. Complete hydatidiform mole with co-existing fetus: predictors of live birth. *European Journal of Obstetrics & Gynecology and Reproductive Biology*. 2017;212:1-8. DOI: 10.1016/j.ejogrb.2017.03.013.
7. Buza, N., McGregor, S. M., Barroilhet, L., Zheng, X., Hui, P. Paternal uniparental isodisomy of tyrosine hydroxylase locus at chromosome 11p15.4: spectrum of phenotypical presentations simulating hydatidiform moles. *Modern Pathology*. 2019;32(8):1180-1188.
8. Diagnosis and treatment of gestational trophoblastic disease. Evidence and recommendations. General Health Council. Accessed 29 March 2021. Available: http://www.cenetec.salud.gob.mx/descargas/gpc/CatalogoMaestro/228_SS_09_Enf_trofoblastica_Gest/EyR_SS_228_09.pdf.

9. Liu, Y., Zheng, X., Wang, Y., Li, Y., Liu, C. Identification of a hydatidiform mole in twin pregnancy following assisted reproduction. *Journal of assisted reproduction and genetics*. 2019;1-8.
10. Tang, Y., Zhu, C., Zhu, C., Liang, F., Lee, A., Yao, X., et al. The impact of pre-evacuation ultrasound examination in histologically confirmed hydatidiform mole in missed abortion. *BMC Women's Health*. 2020;20(1):1-6. DOI:10.1186/s12905-020-01064-9.
11. Aggarwal, A., Singh, C., Sharma, S., Reddy, A., Kaul, A. A Case of a Complete Hydatidiform Molar Pregnancy with a Co-existent Live Fetus. *Journal of Fetal Medicine*. 2018;5(4):205-207. DOI: 10.1007/s40556-018-0179-x.

UNDER PEER REVIEW