

## **AN AYURVEDAMANAGEMENT OF SHWITRA – A CASE STUDY**

**(1)DR. SHALLU SHARMA,(2)DR.SWAPNIL RASKAR**

(1)PG scholar of Department of *Kaumarbhritya*, Parul Institute of Ayurveda, Vadodara Gujarat, India

(2)Associate professor of Department of *Kaumarbhritya*, Parul Institute of Ayurveda, Vadodara Gujarat, India

### **ABSTRACT:-**

Shwitra is a condition characterised by white patches on the body. It's possible that it's linked to Vitiligo in modern science. In Ayurveda, all skin illnesses are classified as KusthaRoga. It is caused by *Tridosha* vitiation. It is an autoimmune disease that can be linked to other autoimmune diseases such as diabetes mellitus, pernicious anaemia, and Addison disease. Leukoderma affects one percent of the population . For the patient, this sickness becomes a source of social disgrace as well as a financial hardship.

**Aim:-** To Evaluate The Efficacy Of Ayurvedic Treatment In Shwitra.

**Study Design:-** Simple Single Arm Study

**Place :-** Parul Ayurved Hospital, Parul University,Limda, Vadodara, Gujarat.

**Duration Of Study :-** 2 Months

**Methodology:-** Kosthashuddhi With Internal Medication And Rasaaushidhi For External Medication.

Which provides a fresh hope for providing efficient and safe treatment. It was in much better shape than before.

**Key Words:** Shwitra, KusthaRoga, leukoderma, Virechana Karma, Rasausadhi

## **INTRODUCTION:-**

Our body's largest organ, the skin, forms the outermost covering of our body. It is a complicated organ that interacts physiologically and pathologically with the majority of other organs. UV protection is provided by the pigment melanin. Our body's largest organ is our skin. The condition of one's skin, encompassing physical and psychological health, determines one's beauty and attraction. Shwitra is a skin illness that has a significant negative impact on human existence. The Shwitra is a group of symptoms that appear as white spots on the skin and generate a cosmetic imbalance in the body, which leads to a number of socialised psychological stigmas in the patient's life.

White, red, or copper red coloured spots on the skin, loss of skin lustre, loss and colouring of hair, roughness, dryness, itching, and burning feeling of the patches are all signs and symptoms of Shwitra. It was linked to vitiligo and leukoderma, according to modern research.

Leukoderma is defined as skin depigmentation caused by the destruction of melanocytes in the body, which can be localised or full. Leukoderma looks a lot like vitiligo, which is characterised by white patches on the skin. Thyroid disease, diabetes mellitus, Addison's disease, traumatic occurrences, eczema, and psoriasis are all examples of autoimmune conditions that can cause leukoderma. Leukoderma is not a painful, harmful, or contagious condition, but it has a significant psychological impact on the individual who suffers from it. The size of leukoderma patches varies. (1-2)

It is a psycho-emotional disease reflected in the skin as pigmentation problem. In today's world everyone is beauty conscious. White patches that appear on the skin exhibit beauty mainly in females. It degrades the moral of a person with regards to beauty and also leads to lack in confidence.

The following case was treated for two months with internal medication and rasaushadhi, with excellent results as evidenced by inspection and photographs.

The results of this clinical trial will shed more light on the effects of Ayurvedic medicine on leukoderma.

## **AIM AND OBJECTIVES:-**

To evaluate the efficacy of Ayurvedic treatment in Shwitra.

## **CASE DESCRIPTION:-**

On 10/10/2020, a female patient aged 12 years, opd reg. no. 20016517, visited opd of kaumarbhritya, parul ayurved hospital, with pale discoloration over limbs, face, and scalp for 1.5 years, minor itching, burning sensation, and dryness, presented to opd of kaumarbhritya, parulayurved hospital.

## **HISTORY OF PRESENT ILLNESS:-**

Before 1.5 years, the patient was in good health. She gradually acquired some white discoloration over her right elbow joint, first with minor irritation and a very little lesion. The patient was unconcerned about it and ignored it, but her mother saw more white patches on both legs' lower limbs and ankle joints after a month. With presented with severe itching, burning sensation, dryness, and the color of the patches were white. After that patient's parents took her nearby hospital. There she was diagnosed with vitiligo and given suitable

medicine her. The patient took 7 months of treatment but she did not get relief. To get a suitable solution they visited our hospital Parul Ayurved hospital for further management.

**ASSOCIATED SYMPTOMS:-**

Constipation was present from 1 year.

**PAST HISTORY:-**

No history of above skin complaints from past 1.5 year.  
No any history of thyroid disorder or any metabolic disorder.

**FAMILY HISTORY:-**

Her grandmother was suffering with same skin affecting complaints. She expired 3 years back.

**IMMUNIZATION STATUS:-**

scheduled as per age .

**PERSONAL HISTORY:-**

Bowel:- Constipation

Urine :- 4-5 Times /Day

Sleep :- Sound

Krida :-Outdoor

**SOCIAL HISTORY:-**

Residential Area:- Rural

Personal Hygiene :- Poor

Sanitation :- Poor

Drinking Water :- Tubewell

Family:- Joint

**DEVELOPMENTAL STATUS:-**

Gross Motor:- Achieved

Fine Motor :- Achieved

Personal And Social :- Achieved

Language :\_ Achieved

Toilet Training :- Achieved

**ETHICALN ISSUE :- NONE**

**IEC :- DONE ( PU/PIA/IECHR/2019/167)**

**DIETETIC HISTORY:-**

Vegetarian diet.

**CLINICAL ASSESMENT****A)General examination:-**

Heart Rate :- 88/M

Temperature :- 98.8 F

Respiratory Rate :\_ 20/M

**B) Systemic Examination:-**

Respiratory System:-AEBE Normal

Cardiovascular System:- S1S2 Normal

GIT System :- P/A Soft And Non Tender

Central Nervous System:- Patient Was Concious And Oriented

**LOCAL EXAMINATION:-**

Site Of Lesion:- Skin

Distribution :- Irregular

Character Of Lesions :- Present

Itching:- Present

Dryness:- Present

Roma Vivaranta :- Present

**MATERIAL AND METHOD:-**

**CENTRE OF STUDY:-**This study was carried out in kaumarbhritya department of PARUL AYURVEDA HOSPITAL,LIMDA,VADODARA.

**TREATMENT:-**

**TABLE 1:- LINE OF TREATMENT- KOSTHA SHUDHI AND BAHYA CHIKITSA.(3-4)**

Day	Manibhadra Avaleha	Mansheeladi Ointment
15 <sup>th</sup> Day	18 gm In Three Divided Doses BF	Over Effected Area qs
30 <sup>th</sup> Day	18 gm In Three Divided Doses BF	Over Effected Area qs
45 <sup>th</sup> Day	18 gm In Three Divided Doses BF	Over Effected Area qs
60 <sup>th</sup> Day	18 gm In Three Divided Doses BF	Over Effected Area qs

Medication has given to the patient for 60 days with 4 follow from 0<sup>th</sup> day to 60<sup>th</sup> day. Manibhadra avaleha was given to the patient for koshtashuddhi and mansheeladi ointment given to the patient for bahyachikitsa.

**TABLE 2:- ASSESMENT GRADING FOR SUBJECTIVE PARAMETER(5)**

Symptoms	Grading		
Twakrukshata	Grade 0 Grade 1 Grade 2 Grade 3	Normal Mild Moderate Severe	No dryness Dryness on exposure to sunlight or other allergens Dryness during exposure to cold environment Always dry
Kandu	Grade 0 grade 1 grade 2 Grade 3	Normal mild moderate Severe	No itching Itching on exposure to cold ,sunlight or allergens Itching on exposure to cold env. Severe itching
Daha	Grade 0 Grade 1 Grade 2 Grade 3	Normal Mild Moderate Severe	No burning sensation Burning sensation on exposure to midnoon sunlight Burning sensation on exposure to morning sunlight or irritants Always burning sensation
Twakshwetata	Grade 0 Grade1 Grade2 Grade 3	Normal Mild Moderate Severe	Normal skin colour Less depigmentation at margins and more on a lesions Depigmentation is more than pigmentation or equal on lesions No pigmentation only white colour

Roma vivarnata	Grade 0	Normal	Normal hair colour
	Grade 1	Mild	Less than 20 % of hair on lesions has vivarnta
	Grade 2	Moderate	25-75% of hair over the lesions has vivarnata
	Grade 3	Severe	More than 75% of hair overthe lesions has vivarnata

**TABLE 3 ASSESMENT CRITERIA FOR NO. OF PATCHES(6)**

NUMBER OF PATCHES	SCORE
1	1
2	2
3	3
4	4
>4	5

**TABLE 4 ASSESMENT CRITERIA FOR COLOUR OF PATCHES(7)**

COLOUR OF PATCHES	SCORE
NORMAL SKIN COLOUR	1
RED COLOUR	2
WHITE TO REDDISH	3
RED TO WHITISH	4
WHITE	5

**OBSERVATION AND RESULTS:-**

Regular oral and external use of manibhadraavaleha and mansheeladi ointment was observed. Which help in minimized the size of the shwitra patches and colour of the patches.

**TABLE 5 OBSERVATION DURING TREATMENT(SUBJECTIVE PARAMETER)**

SYMPTOMS	GRADING				
	0 <sup>TH</sup> DAY	15 <sup>TH</sup> DAY	30 <sup>TH</sup> DAY	45 <sup>TH</sup> DAY	60 <sup>TH</sup> DAY
TWAK SHWETATA	2	2	1	1	1
TWAK RUKSHATA	2	2	1	0	0
KANDU	2	1	1	0	0
DAHA	2	1	1	0	0
ROMA VIVARANTA	2	2	2	1	1

**TABLE 6 OBSERVATION DURING TREATMENT COLOUR OF PATCHES (OBJECTIVE PARAMETERS)**

COLOR OF PATCHES	GRADING				
	0 <sup>TH</sup> DAY	15 <sup>TH</sup> DAY	30 <sup>TH</sup> DAY	45 <sup>TH</sup> DAY	60 <sup>TH</sup> DAY
NORMAL SKIN CLOUR	-	-	-	-	-
RED COLOUR	-	-	-	-	2
WHITE TO REDDISH	-	-	-	3	-
RED TO WHITISH	-	-	4	-	-
WHITE	5	5	-	-	-

**TABLE 7 OBSERVATION DURING TREATMENT NUMBER OF PATCHES (OBJECTIVE PARAMETERS)**

NUMBER OF PATCHES	GRADING				
	0 <sup>TH</sup> DAY	15 <sup>TH</sup> DAY	30 <sup>TH</sup> DAY	45 <sup>TH</sup> DAY	60 <sup>TH</sup> DAY
1	-	-	-	-	-
2	-	-	-	-	-
3	-	-	-	3	-3
4	-	-	4	-	-
>4	5	5	-	-	-

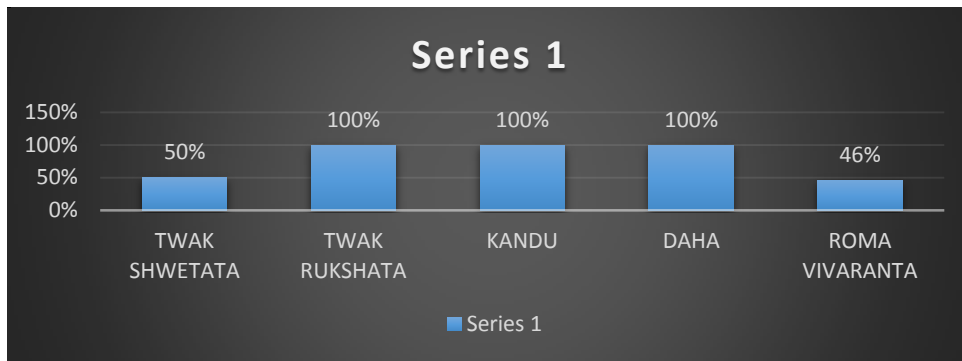
**TABLE 8 OBSERVATION DURING TREATMENT VASI SCORE(8)**

VASI SCORE(CM SQ)		PERCENTAGE RELIEVED
BT	AT	
163 CMSQ	70CM SQ	42.94%

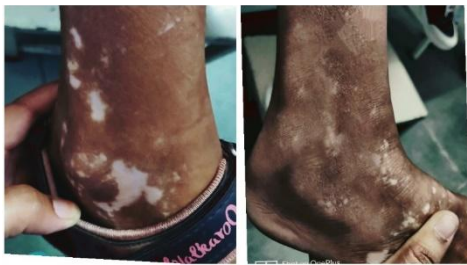**TABLE 9 SYMPTOMATIC RELIEF**

SYMPTOMS	PERCENTAGE
TWAK SHWETATA	50%
TWAK RUKSHATA	100
KANDU	100
DAHA	100
ROMA VIVARANTA	46%

**GRAPH 1:- GRAPHICAL PRESENTATION OF SYMPTOMATIC RELIEF**

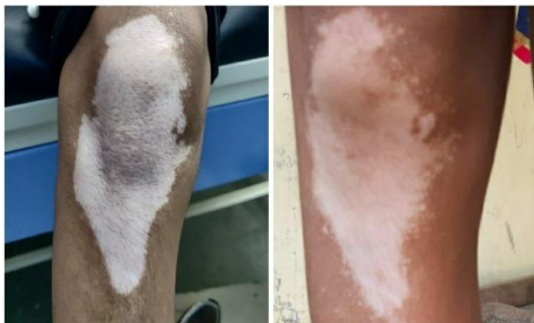

#### PHOTOS OF CASE STUDY:- NO. 1



Before treatment	After treatment
------------------	-----------------

#### NO. 2



Before treatment	After treatment
------------------	-----------------

### DISCUSSION

#### MANIBHADRA AVLEHA:-

It contains amalaki, haritaki, vidang, trivrit and guda.

In which amalaki has vitamin c which enhances the late differentiation of keratinocytes, reduce oxidative stress and keep the integrity of the entire cuticle. Which ensure the characteristics of the skin barrier and stopping pores and skin water loss, which helps in flip the problem.(9)

Amalaki also is vata, kapha, pitta har which helps in removal of doshas and reduce the burning sensation in skin due to sheet virya.(10)

Haritaki has tri-ethyl chebula which is a sturdy antioxidant and free radical scavenger, which assist for anti oxidative capability. This help in pigmentation of white skin in *shwitra*.(11)



It is also *pitta* , *kapha* and *vatahar*. Due to *katu* and *Kashaya rasa* it helps in purification of *rakta dhatu* which helps in change in the color of skin.(12)

*Vidanga* has energetic concept i.e estrogenic factor. Which accelerate the thyosinase interest of human melanocyte, and promotes the formation of melanin.(13)

*Trivrit* act as a purgation which helps in shodhna of the body and eliminates the vitiated doshas which is curx of the pathology of shwitra.(14)

Guda contains calcium, zinc ,vitamin b12 which plays important role in the manner of melanigenesis. Vitamin b12 act as a pseudo t-tyrosine which help in the regulation of melanocytes and help in melanin formation.(15)

## **MANSHEELADI OINTMENT**

Mustard seed has phytotoxins which act as anti bacterial and anti fungal activity, which help to prevent the spread of patches of shwitra. It also has anti inflammatory mechanism which help in wound healing and burning sensation.(16)

Arkadugdh is bhedaka , teekshna , kaphvata shamaka in nature due to which it cures the shwitra.(17)

Hartala breaks the pathogenesis of shwitra which prevent the self destruction of melanocytes. The vyavayi and ashukari properties of hartala may help the other drugs to reach the site quickly and remove the obstruction of shwitra.(18)

Mansheela act a toxic warmness on skin which promote the quick absorption of other drugs. It also has katurasa,ushnavirya,saraguna which helps in vatakapha shaman and also varnya karma act on bharajak pitta which mainly invlved in colouration of skin.(19)

Maricha( pipernigrum)it has many important active constituents like piperine,piperidine,piperamide which increase the absorption of vitamin b , beta – carotene and as well as other nutrients. Maricha has anti oxidant properties.(20)

## **CONCLUSION:-**

*Shwitra* (leukoderma) is one of the skin ailments producing psychosomatic trauma to individual and it is of more concern especially in children. Ayurveda remedies have highest potential to control the *Shwitra*. In this study encouraging results was obtained in *Shwitra*. There is significant reduction in the patches with the use of *Manibhadra Avaleha* and *Manasheeladi* Ointment and is found to be safe and effective.

## **ACKNOWLEDGEMENTS:-**

I would like to thank board members of PARUL UNIVERSITY, dean sir of PARUL INSTITUTE of **AYURVEDA** and my all faculty in department of **kaumarbhritya** for their valuable guidance, support, suggestions and encouragement.

## **COMPETING INTERESTS:-**

There were no other people or organizations that influences this work. No funding, no patent application /registration has been requested or granted. So, authors have declared that no competing interests exist.

#### **AUTHORS'S CONTRIBUTION:-**

Author 1 designed the study, performed the statistical analysis wrote the protocol and wrote the first draft of the manuscript. And author 2 managed the analyses of the study. Authors read and approved the final manuscript.

#### **ETHICAL APPROVAL:-**

This confirm that this study is not against the public interest. The ethical approval from institute have been obtained.

#### **REFERENCES:-**

1-2.Ref. Dr. Deepikatyagi kc-2010 gaacahmedabadgaujamnagar, thesis

Ref. Dr. Nirankkumar kc-2017 [pgtragaujamnagar,thesis

3-4.Charaksamhita sutra sthan 3/11, acharyavidyadharshukla, prof. Ravidutttripathi, chaukhambasanskritpratisthan,delhi

Ashtangsangrhaya chapter chikitsasthan 21/28 dr. Jyotimitraacharyakritsanskritchaukhambasanskrit series, varanasi.

5.Radhika injamuri, suryanarayana mudadla . A clinical study on the therapeutic effect of dhatryadi kwatha& aparajithalepain switrain children

6-7.A comparative clinical study between DhatryadiKwatha and ManhshiladiLepa along with and without Trivritadi Yoga Virechana administrated in the management of Shvitraw.s.r. to vitiligo

8. Kawakami T, Hashimoto T. Disease severity indexes and treatment evaluation criteria in vitiligo. Dermatology Research and Practice. 2011 Jan 1;2011.A clinical study on the therapeutic effect of dhatryadikwatha&aparajithalepa in switra in children

7.Ashtangsangrhaya chapter chikitsasthan 21/28 dr. Jyoti mitra acharyakrit Sanskrit chaukhamba sanskrit series, Varanasi

8. Wang K, Jiang H, Li W, Qiang M, Dong T, Li H. Role of vitamin C in skin diseases. Frontiers in physiology. 2018 Jul 4;9:819. <https://www.ncbi.nlm.nih.gov/pmc/articles/PMC6040229/>

9. Dasaroju S, Gottumukkala KM. Current trends in the research of Emblica officinalis (Amla): A pharmacological perspective. Int J Pharm Sci Rev Res. 2014;24(2):150-59.

<https://globalresearchonline.net/journalcontents/v24-2/25.pdf>

Dodke PC, Pansare TA. Ayurvedic and Modern aspect of Terminalia chebula Retz. Haritaki An Overview. International Journal of Ayurvedic and Herbal Medicine. 2017;7(2):2508-17.

10. Meher SK, Panda P, Das B, Bhuyan GC, Rath KK. Pharmacological profile of Terminalia chebula Retz. and Willd.(Haritaki) in Ayurveda with evidences. Research journal of Pharmacology and Pharmacodynamics. 2018;10(3):115-24.
11. Kaur M, Chandola H. Role of Virechana Karma in cure and prevention of recurrence of Vicharchika (Eczema). Ayu. 2012 Oct;33(4):505.
12. Yildirim M, Baysal V, Inaloz HS, Kesici D, Delibas N. The role of oxidants and antioxidants in generalized vitiligo. The Journal of dermatology. 2003 Feb;30(2):104-8.
13. Nagai K, Ichimiya M, Yokoyama K, Hamamoto Y, Muto M. Successful treatment of non-segmental vitiligo: systemic therapy with sex hormone-thyroid powder mixture. Hormone Research in Paediatrics. 2000;54(5-6):316-7.
- Tjioe M, Gerritsen MJ, Juhlin L, Van De Kerkhof PC. Treatment of vitiligo vulgaris with narrow band UVB (311 nm) for one year and the effect of addition of folic acid and vitamin B12.
14. Umate PR, Deogade M, Pargaonkar A, Umate JP, Kanyal L. Comparison of Properties of Naveen, Puran and Suryatapi Guda (Jaggery) with Respect to Guru and Laghuguna-An Observational Study. Int J Cur Res Rev| Vol. 2020 Aug;12(15):92.)
- Tjioe M, Gerritsen MJ, Juhlin L, Van De Kerkhof PC. Treatment of vitiligo vulgaris with narrow band UVB (311 nm) for one year and the effect of addition of folic acid and vitamin B12.
15. Charaksamhita sutra sthan 3/11, acharyavidyadharshukla, prof. Raviduttripathi, chaukhambasanskritpratisthan,delhi
16. Divya V, Ragamala KC. The Effect of Mulaka Beejadi Lepa and Pruthu Nimba Panchaka Churna in the Management of Vicharchika WSR to Eczema. International Journal of Ayurvedic Medicine. 2018 Jun 1;9(3):185-90.
- Neethu P, Vijayan V, Athulya CM, Arathi R. A review on anti-toxic effect of sweta sarshapa. Pharma Innovat J. 2019;8:261-4.
17. Rabb UN. Pharmacological Activities of Arka Dwaya-A Literary Review.
18. A clinical study on the role of oral intake of *bakuchi churna* and local application of *avalgubeejadi lepa* in the management of *shvitra* w.s.r. vitiligo
- Wu J, Shao Y, Liu J, Chen G, Ho PC. The medicinal use of realgar (As<sub>4</sub>S<sub>4</sub>) and its recent development as an anticancer agent. Journal of Ethnopharmacology. 2011 Jun 1;135(3):595-602.
19. Senevirathna GG, Weerasekera KR. A Basic Analytical Study of Romashatana Churna (Powder) for Arsenic Contain. International Journal of Ayurveda. 2021 Jan 29:47-51.
- Shingadiya RK, Chaudhary S, Prajapati PK. Clinical Efficacy Of Savarnakara Yoga And Kanakabindvarishta In The Management Of Shvitra (Vitiligo). Journal of Research and Education in Indian Medicine. 2017;23(2):91-9.
20. Divya V, Ragamala KC. The Effect of Mulaka Beejadi Lepa and Pruthu Nimba Panchaka Churna in the Management of Vicharchika WSR to Eczema. International Journal of Ayurvedic Medicine. 2018 Jun 1;9(3):185-90.

