

Original Article

Cone-beam computed tomography guidance in functional endoscopic sinus surgery: a retrospective cohort study.

Abstract

Introduction: Image-guided **intra-operative navigation imaging** in surgeries has become widely accepted as an effective tool for improvement of surgical outcomes and reduction of complication in **Functional Endoscopic Sinus Surgery (FESS)**. **Cone-beam CT (CBCT)** is a variant of computed tomography imaging that has developed as a cross-sectional and potentially low-dose technique to visualize bony structures in the head and neck. In current study it was tried to survey surgeons' satisfaction with CBCT **intra-operative navigation imaging** and image quality prior to FESS and post-operative complications.

Methods: In this prospective study, the patients who were candidates for FESS underwent CBCT from January to June 2019 were included in the study. The data regarding demographic information, CBCT findings and diagnosis were extracted from the documents. The surgeons' satisfaction with **intra-operative navigation imaging** and image quality was quantified was obtained using **Visual Analogue Scale (VAS)** (ranging 0 – 10). Furthermore, patients were contacted 3 months later to ask for about their satisfaction with the operation with VAS and post-operative complications.

Results: Finally, 39 patients were included. The mean age was 40.74 ± 5.75 and 20 patients (51.28 percent) were male. The most frequent **diagnosis was 32 cases in patients with extensive polyposis. (82.1 percent)**. Two surgeons performed this operation separately; one of the surgeons performed 20 (51.28 percent) FESS and the other performed 19 (48.71 percent). The

mean satisfaction of the surgeons of CBCT guided FFESS was 8.69 ± 0.92 . After the 3-month follow up, patients' satisfaction score was 8.21 ± 1.89 . No postoperative complications were reported.

Conclusion: Based on the surgeons' point of view, CBCT was shown to be reliable for image-guided FFESS. Furthermore, the outcome and complications of performed surgeries were similar to those performed with computed tomography **intra-operative navigation imaging**.

Keywords: Cone-Beam Computed Tomography, Paranasal Sinuses, Sinusitis, Surgery, Endoscopy

UNDER PEER REVIEW

Cone-beam computed tomography guidance in functional endoscopic sinus surgery: a retrospective cohort study.

Introduction

Nowadays, functional endoscopic sinus surgery (FESS) is the choice treatment for the skull base diseases and rhinosinusitis (1). This technique includes insertion of a slender endoscope and other tools through nostrils to widen sinus pathways by removing tissue and bones (2). The extent of FESS varies according to the surgeons' individual practice and the extent of disease. This manipulation during the surgery is of great importance because the aforementioned bones and cartilages are adjacent to some critical anatomical structures such as optic nerve, carotid and anterior ethmoidal artery (3). Damage to these structures is the main source of the major complications of FESS such as hemorrhage, blindness, oculomotor deficits and cerebrospinal fluid leak (4-6). Therefore, one of the fundamentals for successful FESS is knowledge of the complex anatomy of the paranasal sinuses.

Introduction of imaging-guided surgeries (IGS) in this field has drastically decreased rate of complications (7). Furthermore, IGS has led to surgeries with an increased efficacy including decreased operation duration, decreased workload and improved surgical outcomes (8). Computed tomography is the method of choice for the evaluation of osteomeatal complex and paranasal sinuses. Despite the high sensitivity and specificity of this method, its high radiation dose, high cost and required infrastructure have made this modality limited to be applied routinely (9). One of the relatively new modalities developed is Cone-beam Computed Tomography (CBCT). The relatively compact design and low radiation dose of CBCT have made this modality an attractive one for diagnosis, surgical planning and intra-operative application in head and neck surgeries (10, 11). CBCT permits multi-planar visualization of craniofacial structures for the evaluation of various

pathologies and problems (12). Albeit these advantages, CBCT has some limitations compared to routine computed tomography scanning, including absence of a Hounsfield scale, poor density resolution in soft-tissue imaging, and higher noise (13).

In line with the previous advances in **image-guided surgery (IGS)**, to decrease the invasiveness and decrease expenses in surgeries, which is one of the main objectives of health care systems all over the world, the current study was designed to evaluate the efficacy of CBCT guidance in FESS based on the surgeons' experience and outcome of operations.

Methods

In the current single-center prospective study, all patients who were candidates for FESS underwent CBCT in Firouzgar Clinical-Educational Center, which is the referral center for maxillofacial surgeries in Iran, during January to June 2019 were included in the study. This was in concordance with ethical principles of the Helsinki Declaration (1964) and was approved by the Ethics Committee at the Iran University of Medical Sciences.

The inclusion criteria included:

1. Revision sinus surgery
2. Distorted sinus anatomy of development, postoperative or traumatic origin
3. Extensive sinonasal polyposis: pathology involving the frontal, posterior ethmoid, and sphenoid sinuses
4. Disease abutting the skull base, orbit, optic nerve or carotid artery
5. CSF rhinorrhea or conditions where there is a confirmed or suspected skull base defect

6. Benign and malignant sinonasal neoplasms

Finally, 39 patients met the criteria and were included in the study. After obtaining CBCT images, patients with positive pathologic findings on CBCT underwent therapeutic sinus endoscopy under general anesthesia, and those without pathologic findings on CBCT underwent diagnostic sinus endoscopy under regional anesthesia within 1 week after CBCT scanning. The corresponding medical records were extracted from the hospital database. The information about age, gender, physical examinations, diagnosis, CBCT findings, intra- and post-operative complications were extracted from the documents. Also, **Visual Analogue Scale (VAS)** on a 10-cm line was used to quantify the surgeon's satisfaction with **the intra-operative navigation imaging** and image quality using CBCT. Moreover, a 3-month follow-up after FESS was performed by acquiring patients' satisfaction based on VAS score via telephone.

Surgical plane, Prisman et al.,2011 described and it briefly is explained to form "CBCT images were resliced in real-time to represent a plane parallel the plane created by the tip of the endoscope, at a distance from the endoscope controlled by the user. This plane represents the radiologic equivalent of the endoscope" (14).

For description of the groups, descriptive statistical methods were used and data were expressed as mean \pm standard deviation or frequency and percentage. Kruskal-Wallis and U-Mann Whitney test were used to compare satisfaction scores in different groups. Statistical Package for the Social Sciences (SPSS) software version 16.0 (SPSS Inc., Chicago, IL). P-value \leq 0.05 was considered statistically significant.

Results

During 3 months, 39 patients were included. The mean age was 40.74 ± 5.75 and 20 patients (51.28 percent) were male. Final diagnoses included **32 nasal polyposis (82.1 percent)**, 4 fungal sinusitis

(10.6 percent), 1 cerebrospinal fluid leak (2.6 percent), 1 Ameloblastoma (2.6 percent) and 1 Meningioma (2.6 percent). Two surgeons performed this operation separately; one of the surgeons performed 20 (51.28 percent) FESS and the other performed 19 (48.71 percent). The most common indication for CBCT was revision surgery for polyposis (66.6 percent). A sample CBCT image of one of the patients is shown in Figure 1. None of the patients developed any major intra-operative and post-operative complications.

The mean satisfaction of the surgeons of CBCT guided FESS was 8.69 ± 0.92 . The satisfaction scores between the two surgeons were not statistically significant ($p=0.58$). Furthermore, the satisfaction scores between different genders ($p=0.77$) and diagnoses ($p=0.2$) were not statistically significant. After the 3-month follow up, the surgeons' satisfaction score with surgery outcome was 8.21 ± 1.89 .

Discussion

In the current study, it was found that both surgeons were highly satisfied with the **intra-operative navigation imaging** accuracy and image quality. Furthermore, implementation of this technique led to no major complications during or after the operation. This CBCT guided FESS was shown capable regarding FESS of the patients' demographic information and the final diagnosis.

FESS is the most regularly performed surgery in Ear Nose and Throat practices for the treatment of medically refractory chronic rhinosinusitis with and without polyposis and dental sinusitis which are often unrecognized and labeled as chronic rhinosinusitis (15). FESS is also a crucial surgical approach to epistaxis management, antrochoanal polyps, skull-base surgery and sinonasal tumors (16, 17). FESS is usually performed to restore nasal patency without excessive exposure, improved delivery of washes, medications and olfactory stimuli, removing inflammatory foci and maintaining natural mucociliary pathways (18). Albeit the increasing popularity of FESS, the

procedure is fraught with potential morbidity due to intracranial and orbital complications. Complications of FESS are either major or minor including complications include **cerebrospinal fluid (CSF)** leak or orbital hematoma, intracranial injury, orbital hematoma, blindness, diplopia, extraocular muscle injury, or death (6, 19, 20). In order to reduce these complications by increasing surgeons' orientation of the anatomy IGS was proposed(21).

Recently, CBCT is also proposed as one of the modalities capable of providing guidance during FESS. The relatively low radiation dose, compact design, increased feasibility and high-quality bone definition has made CBCT an appropriate modality for paranasal sinuses, in line with this issue as the inflammatory sinus diseases are often recurrent and leads to repetitive imaging acquisitions, in such patients CBCT provides a good spatial resolution with a reduced field of view (22, 23). It has been already shown that about 75 percent of head and neck surgeons do not know about the utilization of CBCT in their field as inflammatory sinus disease is often recurring and results in repetitive imaging requests, in such cases CBCT provides good spatial resolution with reduced field of view (1). The effective dose in CBCT ranges from 13 to 500 μSv , which most fall into 30 to 80 μSv and the image quality can vary depending on the radiation dose; images with higher radiation often produce better image qualities. In comparison, standard panoramic radiography delivers $\sim 13 \mu\text{Sv}$ and multidetector CT delivers $\sim 860 \mu\text{Sv}$ (24). In a study by Alspaugh et al. the spatial resolution of paranasal images using CBCT and multidetector CT were compared and it was concluded that 12 line pairs per centimeter could be achieved with an effective dose of 0.17 mSv in CBCT compared to the 0.87 mSv for 11 line pairs per centimeter spatial resolution in a **multi-detector computed tomography (MDCT)** (25). In another study by Rafferty et al. investigating application of C-arm CBCT in endoscopic sinus surgery it was concluded that soft tissue and spatial contrast was sufficient to be used as an **assistive intra-operative navigation imaging** guide for frontal recFESS surgery (26). This was also similar to that found in our study, supporting the use of CBCT

guided FESS. Utilization of intra-operative CBCT in study of Batra et al. was found to be successful to visualize stent locations and residual bony partitions, leading to surgical revisions.

Beside all these capabilities, there are still ongoing controversies about the use of CBCT. This technology is limited by the lack of experience in this field and especially relatively inadequate literature. The ACR Practice Guideline for CT of the head and neck recommends that bone and soft tissue algorithms be used for imaging studies (27). Because of low CBCT radiation dose, only the bony details can be inspected while soft tissue lacks the required details to be examined (28, 29). However, in current study, all required approaches in FESS using aided **intra-operative navigation imaging by** CBCT were performed precisely with minimal complications, therefore the soft tissue details shown in CBCT images seem to be sufficient to guide the surgeon during FESS.

The main limitation of the current study was a semi-qualitative and subjective assessment of **intra-operative navigation imaging** and image quality in CBCT. Furthermore, the comparison between CT and CBCT is a multi-aspect issue, so choosing whether CBCT could be used or not depends on the patients' clinical condition and surgeon's **intra-operative navigation imaging** preferences. The other limitation was the low number of patients with diagnoses other than polyposis, which makes it relatively difficult to investigate and generalize CBCT performance.

Conclusion

The surgeons performing FESS in the current study have recognized CBCT as a reliable and accurate modality for image-based guidance. Furthermore, the outcome and complication of FESS using CBCT **intra-operative navigation imaging** were similar to what observed using CT **intra-operative navigation imaging**. However, the current study lacks the essential prerequisites to lead to a change in IGS protocol, this study has provided a limited set of data to support capabilities of CBCT in IGS.

Conflict of Interest

None declared.

Funding

This study was supported by Iran University of Medical Sciences, Tehran-Iran.

References

1. Lata S, Mohanty SK, Vinay S, Das AC, Das S, Choudhury P. "Is Cone Beam Computed Tomography (CBCT) a Potential Imaging Tool in ENT Practice?: A Cross-Sectional Survey Among ENT Surgeons in the State of Odisha, India. *Indian J Otolaryngol Head Neck Surg.* 2018;70(1):130-6.
2. Jiang R-S, Hsu C-Y. Revision functional endoscopic sinus surgery. *Annals of Otolaryngology & Laryngology.* 2002;111(2):155-9.
3. Dalziel K, Stein K, Round A, Garside R, Royle P. Endoscopic sinus surgery for the excision of nasal polyps: A systematic review of safety and effectiveness. *Journal of Laryngology and Otology.* 2006;120(5):506-19.
4. Stankiewicz JA, Lal D, Connor M, Welch K. Complications in endoscopic sinus surgery for chronic rhinosinusitis: a 25- year experience. *The Laryngoscope.* 2011;121(12):2684-701.
5. McMains KC. Safety in endoscopic sinus surgery. *Current Opinion in Otolaryngology & Head and Neck Surgery.* 2008;16(3):247-51.
6. DelGaudio JM, Evans SH, Sobol SE, Parikh SL. Intracranial complications of sinusitis: what is the role of endoscopic sinus surgery in the acute setting. *American Journal of Otolaryngology.* 2010;31(1):25-8.

7. Prulière-Escabasse V, Coste A. Image-guided sinus surgery. *European annals of otorhinolaryngology, head and neck diseases*. 2010;127(1):33-9.
8. Kingdom TT, Orlandi RR. Image-guided surgery of the sinuses: current technology and applications. *Otolaryngologic Clinics of North America*. 2004;37(2):381-400.
9. Ramakrishnan VR, Orlandi RR, Citardi MJ, Smith TL, Fried MP, Kingdom TT, editors. The use of image-guided surgery in endoscopic sinus surgery: an evidence-based review with recommendations. *International forum of allergy & rhinology*; 2013: Wiley Online Library.
10. Nithianathan S, Brock K, Daly M, Chan H, Irish J, Siewerdsen J. Demons deformable registration for CBCT-guided procedures in the head and neck: convergence and accuracy. *Medical physics*. 2009;36(10):4755-64.
11. Alamri HM, Sadrameli M, Alshalhoob M, Alshehri M. Applications of CBCT in dental practice: A review of the literature. *General dentistry*. 2012;60(5):390-400; quiz 1-2.
12. Liang X, Lambrechts I, Sun Y, Denis K, Hassan B, Li L, et al. A comparative evaluation of cone beam computed tomography (CBCT) and multi-slice CT (MSCT). Part II: On 3D model accuracy. *European journal of radiology*. 2010;75(2):270-4.
13. Miracle A, Mukherji S. Conebeam CT of the head and neck, part 2: clinical applications. *American journal of neuroradiology*. 2009;30(7):1285-92.
14. Prisman E, Daly MJ, Chan H, Siewerdsen JH, Vescan A, Irish JC. Real-time tracking and virtual endoscopy in cone-beam CT-guided surgery of the sinuses and skull base in a cadaver model. *Int Forum Allergy Rhinol*. 2011;1(1):70-7.
15. Bassiouni A, Naidoo Y, Wormald PJ. When FFESS fails: the inflammatory load hypothesis in refractory chronic rhinosinusitis. *The Laryngoscope*. 2012;122(2):460-6.
16. Khalil H, Nunez DA. Functional endoscopic sinus surgery for chronic rhinosinusitis. *Cochrane database of systematic reviews*. 2006(3).

17. Psaltis AJ, Schlosser RJ, Banks CA, Yawn J, Soler ZM. A systematic review of the endoscopic repair of cerebrospinal fluid leaks. *Otolaryngology--Head and Neck Surgery*. 2012;147(2):196-203.
18. Rhee JS, Arganbright JM, McMullin BT, Hannley M. Evidence supporting functional rhinoplasty or nasal valve repair: a 25-year systematic review. *Otolaryngology-head and neck surgery*. 2008;139(1):10-20.
19. Suzuki S, Yasunaga H, Matsui H, Fushimi K, Kondo K, Yamasoba T. Complication rates after functional endoscopic sinus surgery: Analysis of 50,734 Japanese patients. *The Laryngoscope*. 2015;125(8):1785-91.
20. Hopkins C, Browne JP, Slack R, Lund VJ, Topham J, Reeves BC, et al. Complications of surgery for nasal polyposis and chronic rhinosinusitis: the results of a national audit in England and Wales. *The Laryngoscope*. 2006;116(8):1494-9.
21. Dalgorf DM, Sacks R, Wormald P-J, Naidoo Y, Panizza B, Uren B, et al. Image-guided surgery influences perioperative morbidity from endoscopic sinus surgery: a systematic review and meta-analysis. *Otolaryngology--Head and Neck Surgery*. 2013;149(1):17-29.
22. Mathew R, Omami G, Hand A, Fellows D, Lurie A. Cone beam CT analysis of Haller cells: prevalence and clinical significance. *Dentomaxillofacial Radiology*. 2013;42(9):20130055.
23. Prisman E, Daly MJ, Chan H, Siewerdsen JH, Vescan A, Irish JC, editors. Real-time tracking and virtual endoscopy in cone-beam CT-guided surgery of the sinuses and skull base in a cadaver model. *International forum of allergy & rhinology*; 2011: Wiley Online Library.
24. Ludlow JB, Ivanovic M. Comparative dosimetry of dental CBCT devices and 64-slice CT for oral and maxillofacial radiology. *Oral Surgery, Oral Medicine, Oral Pathology, Oral Radiology, and Endodontology*. 2008;106(1):106-14.

25. Alspaugh J, Christodoulou E, Goodsitt M, Stayman J. TH- D- L100J- 04: Dose and Image Quality of Flat- Panel Detector Volume Computed Tomography for Sinus Imaging. *Medical Physics*. 2007;34(6Part23):2634-.
26. Rafferty MA, Siewerdsen JH, Chan Y, Moseley DJ, Daly MJ, Jaffray DA, et al. Investigation of C- arm cone- beam CT- guided surgery of the frontal recFESS. *The Laryngoscope*. 2005;115(12):2138-43.
27. Mukherji S, Gujar S, Jordan J. ACR Practice Guideline for the Performance of Computed Tomography (CT) of the Extracranial Head and Neck in Adults and Children. *ACR Practice Guideline 2006 (Res 12, 17, 35)*. 2009.
28. De Vos W, Casselman J, Swennen G. Cone-beam computerized tomography (CBCT) imaging of the oral and maxillofacial region: a systematic review of the literature. *International journal of oral and maxillofacial surgery*. 2009;38(6):609-25.
29. Schulze R, Heil U, Groß D, Bruellmann D, Dranischnikow E, Schwanecke U, et al. Artefacts in CBCT: a review. *Dentomaxillofacial Radiology*. 2011;40(5):265-73.

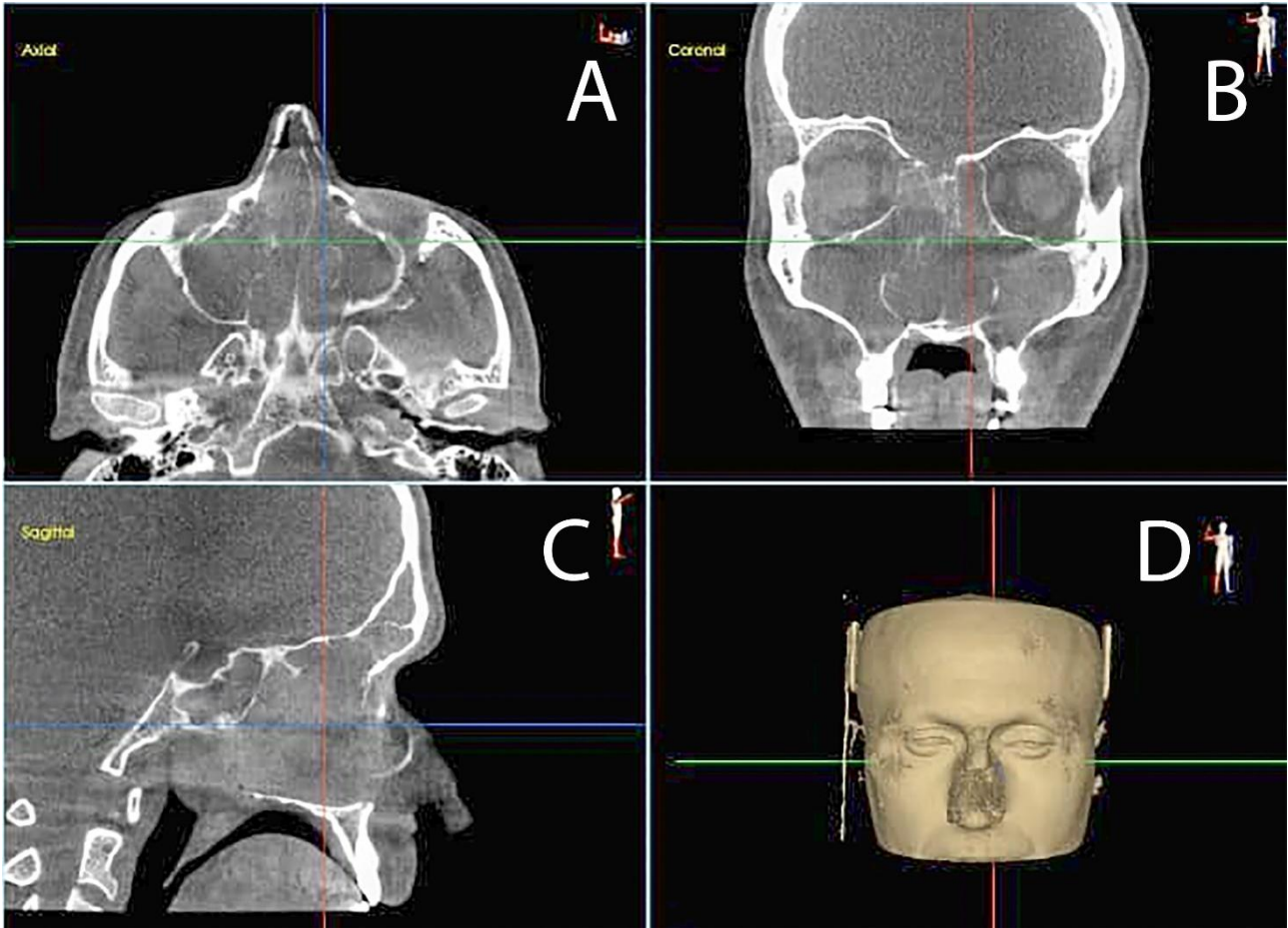


Figure 1. Axial (A), coronal (B), sagittal (C) and 3D re-construction of the images acquired using CBCT of a patient with polyposis and chronic rhinosinusitis.