

## **Original Research Article**

Value of strain Elastography ultrasound in differentiation of benign and malignant breast masses with histopathological correlation

### **ABSTRACT**

#### **Background:**

Breast cancer is currently one of the leading causes of cancer deaths in women. Early detection and accurate classification of suspicious masses as benign or malignant is important for arriving at an appropriate treatment plan. Elastography has shown potential in differentiating benign from malignant breast tumors.

**Objective:** To evaluate the usefulness of Strain Elastography ultrasound in differentiation of benign and malignant breast masses taken histopathology as Gold Standard.

**Methods:** This cross-sectional study was carried out in the Department of Radiology and Imaging, BIRDEM, Dhaka, from July 2017 to June 2019. A total of 92 female patients with breast masses were enrolled in this study. Strain Elastography Ultrasound and histopathology were done in all these patients. Statistical analyses of the results were obtained by using window-based computer software devised with Statistical Packages for Social Sciences (SPSS-22)

**Results:** The validity test of B-mode sonography for differentiation of benign and malignant breast mass has sensitivity 95.0%, specificity 71.2%, accuracy 81.5% and positive predictive values 71.7% and negative predictive value 94.9%. Strain Score has sensitivity 85.0%, specificity 92.3%, accuracy 89.1%, positive predictive values 89.5% and negative predictive values 88.9%. Strain ratio has sensitivity 87.5%, specificity 94.2%, accuracy 91.3%, positive predictive values 92.1% and negative predictive values 90.7%. The validity test of Combined (B-mode sonography and Elastography) has sensitivity 97.5%, specificity 96.2%, accuracy 96.7%, positive predictive values 95.1% and negative predictive values 98.0%. The areas under the curve (AUCs) from the receiver operating characteristic (ROC) curves were 0.948 for ACR-BIRADS classification, 0.986 for Strain score, 0.956 for strain ratio and 0.990 for combination.

**Conclusion:** The combination of strain elastography with B-mode sonography has the potential to improve the differentiation of benign and malignant breast masses.

**Keywords:** Breast, elastography, strain ratio, ultrasound, Masses

## INTRODUCTION

Breast cancer is the commonest cancer in women both in the developed and developing world [1]. As suggested by the American Cancer Society, breast self-examination and clinical breast examination (palpation) are the most frequently used diagnostic tools for detecting breast abnormalities [2]. Breast screening and diagnostic breast imaging also provide early diagnosis of breast cancer [3]. Mammography, the primary screening modality for breast cancer detection, has a sensitivity of 67.8% and an accuracy of 0.70 as described in Berg et al. However, its sensitivity drops from 100% in fatty breasts to about 45% for extremely dense breasts. Therefore, additional imaging modalities whose sensitivity is not affected by breast density are necessary for supplemental detection [4]. Magnetic resonance (MR) imaging and ultrasound has been utilized to supplement mammography. Due to patient claustrophobia, time and financial constraints, in one study only 57.9% of the patients with an elevated risk of breast cancer agreed to undergo MR imaging after mammography and ultrasound scanning. Thus, ultrasound has emerged as a useful modality in the workup of patients with suspected breast masses [5]. Its traditional role has been to differentiate between solid and cystic masses and to guide biopsy procedures. However, Ultrasonography is strongly subjective and poorly specific [6]. It has also been suggested that ultrasound strain imaging, which is becoming commercially available on clinical ultrasound systems, may improve the specificity of ultrasound to differentiate benign from malignant masses. Because of the need for sensitive, noninvasive methods to differentiate breast masses, emerging Ultrasound based approaches are immensely important.

Breast biopsy remains the gold standard for definitive diagnosis of suspicious breast lesions. Although the total number of females referred for interventional diagnostic procedures represents a small percentage of any screened population, the healthcare resources consumed by such females are disproportionately high. Further, the pathological result is benign up to 75% of all cases. Therefore a reliable, noninvasive, cost effective method helping to differentiate benign from malignant breast lesions, thus reducing the number of unnecessary interventional diagnostic procedures, would be valuable [6].

In recent years, a variety of manufacturers have begun to incorporate elastography, a real-time tissue stiffness measuring technique in ultrasound equipment [7]. Over the last 20 years, sonoelastography has developed from a technically complex examination method to one that is simple to carry out and reproduce and that can be integrated into clinical examination procedures. Various manufacturers of ultrasound devices have integrated elastography as a standard feature [8]. The fifth edition of the breast imaging and reporting data system (BI-RADS), an ultrasound atlas, was updated to include the assessment of the elasticity of breast lesions using elastography [10]. Ultrasound has a complementary role to mammography in breast cancer diagnosis. At

the same time in younger patients as well as pregnant women ultrasound is the preferred method of choice in lesion detection and characterization. Greyscale sonography has assigned characteristics that grade the probability of a breast solid mass being either benign or malignant. Although breast imaging modalities have high sensitivity rates, there is still a need for higher specificity in imaging to rule out malignancy in incidentally found breast lesions. Especially ultrasonography (US) examination can detect more malignant masses with lower specificity, which leads to a high number of unnecessary biopsies. US Elastography shows the high number of specificity which could be an adjunct to B-mode Ultrasonography to increase accuracy in the discrimination of benign and malignant breast masses. Ultrasound elastography is an extension of clinical palpation based on the fact that malignant lesions are stiffer than their benign counterparts. Using elastography, tissue stiffness (or hardness) can be measured and converted into an image. It has been used to increase diagnostic accuracy by reducing the number of false positives on B mode ultrasound, therefore obviating unnecessary biopsies [9]. It is against this background that we set out to study strain elastography and in particular, compare the diagnostic accuracy of the qualitative (strain score) and semi-quantitative (strain ratio) methods in a bid to reduce the number of unnecessary biopsies currently done. We did not this kind of study prior to Bangladesh, for this reason, we choose this topic as my research topic.

## Materials and Methods

A cross-sectional study was conducted from July 2017 to June 2019. The study was carried out in the Department of Radiology and Imaging, Bangladesh Institute of Research and Rehabilitation in Diabetes, Endocrine and Metabolic Disorders (BIRDEM), Dhaka. A total of 92 patients were enrolled by using a convenient sampling method; the age of all participants was between 20-75 years. Female patients with breast masses referred to the Radiology and Imaging Department, BIRDEM for ultrasonography. Inclusion criteria include a female patient with a clinically suspected breast mass and Exclusion criteria includes History of FNAC or biopsy of breast mass before ultrasonography, Painful breast masses, and previous breast surgery. The biopsy was performed for all patients.

## RESULTS

**Table 1: Distribution of the study patients by ultrasonographic diagnosis (n=92)**

Ultrasonographic variable	Number of patients	Percentage
<b>ACR-BIRADS classification</b>		
Category 0	-	-
Category 1	1	1.1
Category 2	26	28.3
Category 3	8	8.7
Category 4	23	25.0
Category 5	34	37.0

<b>Benign / Malignant</b>		
Benign	35	38.0
Malignant	57	62.0

Table 1 shows the distribution of the study patients by ultrasonographic diagnosis, it was observed that more than one third 37.0% of patients were ACR-BIRADS classification category 5. More than half 62.0% of patients were malignant and 35(38.0%) benign.

**Table 2: Distribution of the study patients by Histopathological Diagnosis (n=92)**

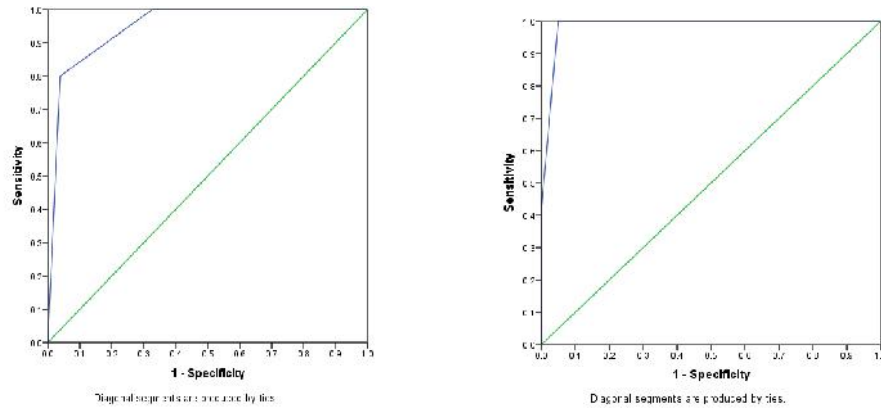
<b>Histopathological Diagnosis</b>	<b>Number of patients</b>	<b>Percentage</b>
Fibroadenoma	37	40.2
Fibrocystic disease	7	7.6
Lipoma	2	2.2
Breast abscess	1	1.1
Lactating adenoma	2	2.2
Duct ectasia	1	1.1
Phyllodes tumor	2	2.2
Ductal Carcinoma In Situ	5	5.4
Invasive Ductal Carcinoma	27	29.3
Lobular Carcinoma In Situ	1	1.1
Invasive Lobular Carcinoma	3	3.3
Medullary Carcinoma	4	4.3

Table 2: Distribution of the study patients by histopathological Diagnosis, it was observed that 37(40.2%) lesions were fibroadenoma, 27(29.3%) invasive ductal carcinoma and 7(7.6%) fibrocystic disease.

**Table 3: Sensitivity, specificity, accuracy, positive and negative predictive values of B-mode Ultrasonography, Elastography and combination of both in the differentiation of benign and malignant breast masses taken Histopathology as gold standard**

<b>Validity test</b>	<b>B-mode Ultrasonography</b>	<b>Elastography</b>		<b>Combined</b>
		<b>Strain Score</b>	<b>Strain Ratio</b>	
Sensitivity	95.0	85.0	87.5	97.5
Specificity	71.2	92.3	94.2	96.2
Accuracy	81.5	89.1	91.3	96.7
Positive predicative value	71.7	89.5	92.1	95.1
Negative predicative value	94.9	88.9	90.7	98.0

The validity test of B-mode sonography has sensitivity 95.0%, specificity 71.2%, accuracy 81.5% and positive predictive values 71.7% and negative predictive value 94.9%. The validity test of histopathology in the evaluation for Strain Score has sensitivity 85.0%, specificity 92.3%, accuracy 89.1%, positive predictive values 89.5% and negative predictive values 88.9%. The validity test of histopathology in the evaluation for strain ratio has sensitivity 87.5%, specificity 94.2%, accuracy 91.3%, positive predictive values 92.1% and negative predictive values 90.7%. The validity test of histopathology in the evaluation for combined has sensitivity 97.5%, specificity 96.2%, accuracy 96.7%, positive predictive values 95.1% and negative predictive values 98.0%.



**Figure 1: Receiver-operator characteristic (ROC) curve of ACR-BIRADS classification for differentiation of benign and malignant breast masses.**

**Table 4: Receiver-operator characteristic (ROC) curve of Elastographic strain ratio for differentiation of benign and malignant breast masses.**

	Cut-off value	Sensitivity	Specificity	Area under the ROC curve	95% Confidence interval (CI)	
					Lower bound	Upper bound
Strain ratio	2.45	87.5	94.2	.956	.912	1.000

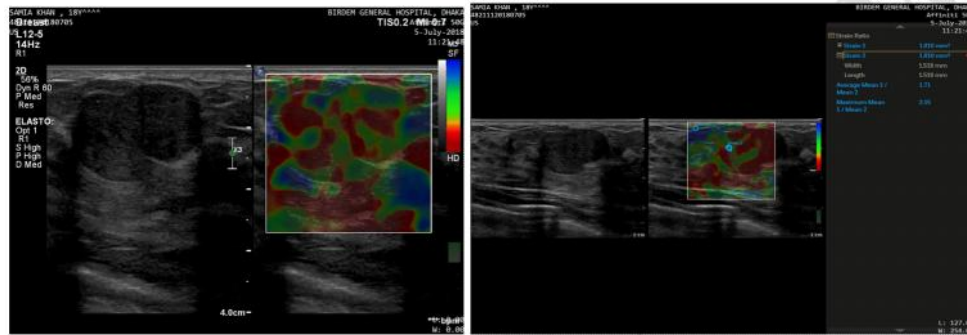
The area under the receiver-operator characteristic (ROC) curve for prediction of differentiation of benign and malignant is depicted in table 4. Based on the receiver-operator characteristic (ROC) curve, the strain ratio had the area under curve 0.956. The Receiver operator characteristic (ROC) curve was constructed by using strain ratio, which gave a cut-off value 2.45, with 87.5% sensitivity and 94.2% specificity for differentiation of benign and malignant breast masses.

**Table 5: Receiver-operator characteristic (ROC) curve of combined B-mode USG and Elastography for differentiation of benign and malignant breast masses**

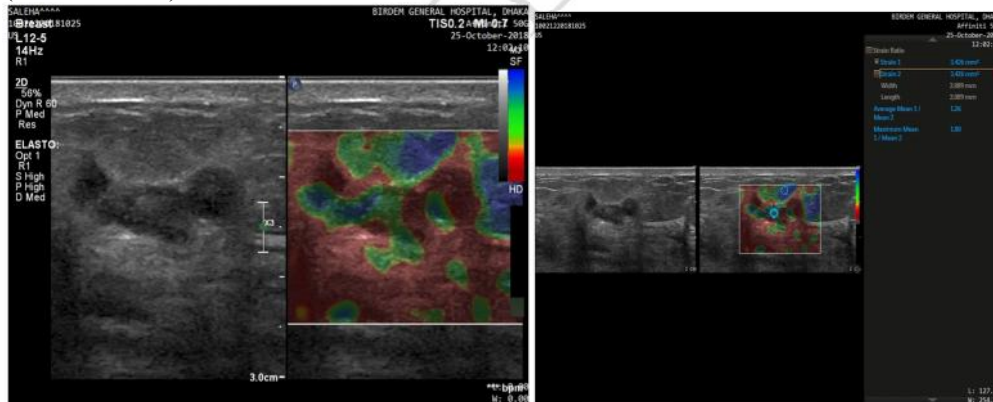
	Cut-off value	Sensitivity	Specificity	Area under the ROC	95% Confidence interval (CI)
--	---------------	-------------	-------------	--------------------	------------------------------

				curve	Lower bound	Upper bound
Combined	7.040	.981	.200	.990	.976	1.000

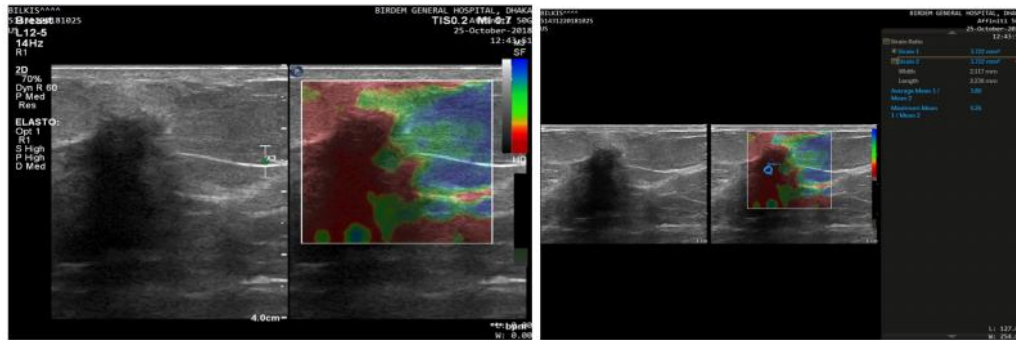
The area under the receiver-operator characteristic (ROC) curve for prediction of differentiation of benign and malignant is depicted in table 5. Based on the receiver-operator characteristic (ROC) curve, combined B-mode USG and Elastography had the area under curve 0.990. The receiver operator characteristic (ROC) curve was constructed by using combined B-mode USG and Elastography, which gave a cut-off value of 7.040, with 0.981 sensitivity and 0.200 specificities for differentiation of benign and malignant breast masses.



**Photograph-1:** B-mode USG images show BI-RADS - 2 lesion. Elastography images show Strain Score - 2 and Strain Ratio - 2.15. Histopathology revealed fibroadenoma (Case No. - 4)



**Photograph-2:** B-mode USG images show BI-RADS - 3 lesion. Elastography images show Strain Score - 2 and Strain Ratio - 1.80. Histopathology revealed breast abscess (Case No. - 15)



**Photograph-3:** B-mode USG images show BI-RADS - 5 lesion. Elastography images show Strain Score - 5 and Strain Ratio - 5.26. Histopathology revealed invasive ductal carcinoma (Case No. – 39)

## DISCUSSION

In this current study, it was observed that 29.5% of patients belonged to age 37-49 years. The mean was  $40.07 \pm 13.82$  years with ranged 15 to 65 years. The mean was  $40.07 \pm 13.82$  years with ranged 15 to 65 years. Kumar and Prasad [11] found most (80.0%) of the patients were in the age group of 15-35 years and the youngest patient was 15 years of age and the oldest was of 62 years. Mutala et al. [1] found the age ranged varied from 15 to 79 years with a median of 28 years, which are comparable with the present study. The above findings are almost similar to the current study. In another study Atabey et al. [3] done on 96 patients, where the mean age of their patients was 50 years with ranged varied from 19 to 87 years, which is higher with the present study.

In this present study, it was observed that 54.3% of patients had a lesion on the left side and 45.7% on the right side. 38.4% of patients belonged to the size of the lesion 21-30 (maximum diameter in mm). The mean size of the lesion was  $15.53 \pm 8.3$  (maximum diameter in mm) with ranged from 4 to 29 (maximum diameter in mm). The size of the lesion may affect the diagnostic accuracy of elastography. Some authorities state that lesions more than 3 cm in diameter may not be adequately evaluated (Institute of Advanced Medical Education, 2016). Mutala et al [1] experience from their study even the masses which were on the larger side of the scale did not affect the diagnostic performance of either method. Elastography correctly indicated benignity and malignancy respectively in a  $7 \times 4.5$  cm fibroadenoma and a 5 cm ductal cancer.

Regarding the Echogenicity of the lesion it was observed in this current study that hypoechoic was more common (64.1%) followed by 21.7% isoechoic, 13.1% complex/heterogeneous and 1.1% anechoic. Similarly, Chao et al (2007) study found hyperechoic 42.9%, heterogeneous echogenicity in 35.7% and isoechoic in 21.4%. In this present study, it was observed that 22.8% of patients had involved surrounding parenchyma of the lesion. In another study, Chao et al (2007) found 42.9% of their study, which differs from the present study. Regarding the Posterior acoustic phenomenon of the lesion, it was observed in this current study that 9.8% of lesions

showed posterior acoustic enhancement, 7.6% had posterior acoustic shadowing, 3.3% had combined pattern and 79.3% had no posterior acoustic feature. Chao et al 2007 found 7.1% had posterior enhancement and 7.1% had a mixture of enhancement and shadowing, bilateral edge shadowing was evident in 14.3% cases and 71.4% tumors had no posterior acoustic feature. Posterior enhancement is considered an indeterminate sonographic feature, whereas bilateral edge shadowing is characteristic of benign tumors, and posterior shadowing is a feature of malignant tumors [12].

In this present study, it was observed that 41.3% of patients had edge shadow, 8.7% had microcalcifications, 13.0% had a subcutaneous layer of the breast involved and 5.4% had retro mammary space of the breast involved. Chang et al. [7] study found micro-calcifications in 18.0% of their study patients. The parenchyma is primarily composed of fibroglandular tissue, with little or no subcutaneous fat in the young non-lactating breast. With increasing age and parity, more and more fat gets deposited in both the subcutaneous and retro mammary layers [13]. Chao et al [7] study found that 14.3% had bilateral edge shadowing.

Regarding the involvement of axillary lymph node, it was observed in this present study that 29.3% of patients had enlarged malignant lymph node, 8.7% had enlarged benign lymph node, 33.7% had no lymph node and 28.3% had normal lymph node. It appears that a definite relationship exists between the level of blood flow in a malignant tumor and the presence of lymph node metastasis. Enlargement of lymph nodes can be due to a variety of benign and malignant causes. The most common malignant cause of abnormal axillary lymph nodes in breast cancer; however, when lymph nodes enlarge because of metastatic breast cancer, the primary tumor within the breast [14,15].

It was observed in this present study that 41.3% of patients had malignant and 58.7% had benign lesions in Elastographic evaluation. Mutala et al. [1] found 31.4% and 68.6% were malignant and benign lesions respectively in elastographic evaluation, which support the present study. Similarly, in another study Abbey et al. [3] found 35.5% of patients had malignant and 64.5% had benign lesions in elastographic evaluation, which are comparable with the current study. Regarding the histopathological diagnosis, it was observed in this present study that most (40.2%) of the patients had fibroadenoma followed by 29.3% invasive ductal carcinoma and 7.6% fibrocystic disease, ductal carcinoma in situ 5.4%, medullary carcinoma 4.3%, invasive lobular carcinoma 3.3%, lipoma 2.2%, lactating adenoma 2.2%, thyroid tumor 2.2%, breast cyst 1.1%, duct ectasia 1.1% and lobular carcinoma in situ 1.1%. Mutala et al. [1] study observed fibroadenoma 66.0%, invasive ductal carcinoma 25.0%, benign breast lesion 1.7%, ductal papilloma 1.7%, gynaecomastia 1.7%, lipoma 1.7%, granulomatous mastitis 0.9% and mastitis 0.9%, which is comparable with the current study. Similarly, Ozsoy et al. [5] found the most common malignant tumor was invasive ductal carcinoma 57.0% and the most common benign tumor was fibroadenoma 21.0%. In combined evaluation, it was observed in this study that true positive 39 cases, false-positive 2 cases, false-negative 1 case, and true negative 50 cases are identified by histopathological evaluation.



In this study, it was observed that the validity test of B-mode sonography for differentiation of benign and malignant breast masses has sensitivity 95.0%, specificity 71.2%, accuracy 81.5% and positive predictive values 71.7% and negative predictive value 94.9%. The validity test of Strain Score for differentiation of benign and malignant breast masses has sensitivity 85.0%, specificity 92.3%, accuracy 89.1%, positive predictive values 89.5% and negative predictive values 88.9%. The validity test of strain ratio for differentiation of benign and malignant breast masses has sensitivity 87.5%, specificity 94.2%, accuracy 91.3%, positive predictive values 92.1% and negative predictive values 90.7%.

The validity test of Combined (B-mode sonography and Elastography) for differentiation of benign and malignant breast masses has sensitivity 97.5%, specificity 96.2%, accuracy 96.7%, positive predictive values 95.1% and negative predictive values 98.0%. In this study based on the receiver operator characteristic (ROC) curves, B-mode USG had the area under curve 0.948, which gave a cut-off value 4, with 95.0% sensitivity and 63.5% specificity for differentiation of benign and malignant breast masses. Similarly, Alam et al. [16] study showed the areas under the curves for B-mode sonography 0.901.

In this study based on the receiver operator characteristic (ROC) curves, strain score had the area under curve 0.986, which gave a cut-off value 4 having sensitivity 85.0% and specificity 92.3% for prediction of differentiation of benign and malignant breast masses. Mutala et al. [1] demonstrated that the strain score ROC curve value of three or greater was considered positive with a sensitivity of 86.0% and specificity of 96.0%.

Based on the receiver-operator characteristic (ROC) curves, strain ratio had the area under curve 0.956, with the best cut-off value of strain ratio 2.45, which had sensitivity 87.5% and specificity 94.2% for differentiation of benign and malignant breast masses. Mutala et al. [1] study showed the areas under the curve was 0.976 for strain score with a cut-off point at 4.2 gave a sensitivity of 93.0% and specificity of 96.0%. Stachs et al. [8] study showed strain ratio at a cut-off of <2.0 for benign tumors and >2.0 for malignant tumors, sensitivity 90.7% and specificity 59.2%.

Based on the receiver-operator characteristic (ROC) curves in this present study, it was observed that the combination of B-mode USG and elastography had the area under curve 0.990, with a cut-off value 7.040, having sensitivity 98.0% and specificity 20.0% for differentiation of benign and malignant breast masses.

## **CONCLUSION**

This study was undertaken to evaluate the usefulness of Strain elastography ultrasound in the differentiation of benign and malignant breast masses taken histopathology as Gold Standard. Breast mass was more common in the 4th and above decade. Ellipsoid, well-circumscribed, and hypoechoic were more common in B-mode ultrasound. Fibroadenoma and invasive ductal carcinoma were more common in histopathological diagnosis. B-mode Ultrasonography, Strain Score and Strain Ratio are highly sensitive, accurate and useful methods in the differentiation of malignant and benign breast masses. Therefore it can be concluded that the

combination of strain elastography parameters with conventional ultrasound can increase the probability of proper diagnosis in the case of breast masses. Implementation of elastography in conventional ultrasound examination should reassure examiners on the use of short-term or routine follow-ups instead of unnecessary biopsies in cases of benign and probably benign lesions.

## References

1. Mutala, T.M., Ndaiga, P. and Aywak, A., 2016. Comparison of qualitative and semiquantitative strain elastography in breast lesions for diagnostic accuracy. *Cancer Imaging*, 16(1), p.12.
2. Xu, H., Rao, M., Varghese, T., Sommer, A., Baker, S., Hall, T.J., Sisney, G.A. and Burnside, E.S., 2010. Axial-shear strain imaging for differentiating benign and malignant breast masses. *Ultrasound in medicine & biology*, 36(11), pp.1813-1824.
3. Atabey, A.O., Aribal, E., Ergelen, R. and Kaya, H., 2014. Value of strain elastography ultrasound in differentiation of breast masses and histopathologic correlation. *The journal of breast health*, 10(4), p.234.
4. Xu, H., Varghese, T., Jiang, J. and Zagzebski, J.A., 2012. In vivo classification of breast masses using features derived from axial-strain and axial-shear images. *Ultrasonic imaging*, 34(4), pp.222-236.
5. Ozsoy, A., Acar, D., Barca, A.N., Aktas, H., Araz, L., Ozkaraoglu, O. and Yuksel, E., 2016. Diagnostic performance of real-time strain sonoelastography in BI-RADS 4 and 5 breast masses. *Diagnostic and interventional imaging*, 97(9), pp.883-889.
6. Olgun, D.Ç., Korkmazer, B., Kılıç, F., Dikici, A.S., Velidedeoğlu, M., Aydoğan, F., Kantarcı, F. and Yılmaz, M.H., 2014. Use of shear wave elastography to differentiate benign and malignant breast lesions. *Diagnostic and Interventional Radiology*, 20(3), p.239.
7. Chang, J.M., Won, J.K., Lee, K.B., Park, I.A., Yi, A. and Moon, W.K., 2013. Comparison of shear-wave and strain ultrasound elastography in the differentiation of benign and malignant breast lesions. *American Journal of Roentgenology*, 201(2), pp.347-356.
8. Stachs, A., Hartmann, S., Stubert, J., Dieterich, M., Martin, A., Kundt, G., Reimer, T. and Gerber, B., 2013. Differentiating between malignant and benign breast masses: factors limiting sonoelastographic strain ratio. *Ultraschall in der Medizin-European Journal of Ultrasound*, 34(02), pp.131-136.
9. Barr, R.G., Destounis, S., Lackey, L.B. 2012. Evaluation of breast lesions using sonographic elasticity imaging: a multicenter trial. *Journal of Ultrasound Med.* 31(2):281–287.
10. Fleury, E.D.F.C., 2015. The importance of breast elastography added to the BI-RADS lexicon classification. *Revista da Associação Médica Brasileira*, 61(4), pp.313-316.

11. Kumar, N. and Prasad, J., 2019. Epidemiology of benign breast lumps, is it changing: a prospective study. *International Surgery Journal*, 6(2), pp.465-469.
12. Chao, T.C., Chao, H.H. and Chen, M.F., 2007. Sonographic features of breast hamartomas. *Journal of ultrasound in medicine*, 26(4), pp.447-452.
13. Howlett, D.C., Marchbank, N.D.P. and Allan, S.M., 2003. Sonographic assessment of the symptomatic breast—a pictorial review. *Journal of Diagnostic Radiography and Imaging Vol*, 5(1). Institute of Advanced Medical Education. Breast elastography: Principles of Strain and Shear-Wave Elastography. Online CME. Accessed 19 Apr 2016.
14. Abe, H., Schmidt, R.A., Kulkarni, K., Sennett, C.A., Mueller, J.S. and Newstead, G.M., 2009. Axillary lymph nodes suspicious for breast cancer metastasis: sampling with US-guided 14-gauge core-needle biopsy—clinical experience in 100 patients. *Radiology*, 250(1), pp.41-49.
15. Yang, W.T., Chang, J. and Metreweli, C., 2000. Patients with breast cancer: differences in color Doppler flow and gray-scale US features of benign and malignant axillary lymph nodes. *Radiology*, 215(2), pp.568-573.
16. Alam, F., Naito, K., Horiguchi, J., Fukuda, H., Tachikake, T. and Ito, K., 2008. Accuracy of sonographic elastography in the differential diagnosis of enlarged cervical lymph nodes: comparison with conventional B-mode sonography. *American journal of roentgenology*, 191(2), pp.604-610.