

Case Report

The superior mesenteric artery syndrome : a rare complication after post-traumatic spine surgery.

ABSTRACT:

Superior mesenteric artery syndrome is a rare complication of post-traumatic spine surgery. The third portion of the duodenum is compressed between the abdominal aorta and the superior mesenteric artery: duodenal (intestinal) occlusion and sometimes arterio-mesenteric occlusion occur. We report the case of a young male patient, in whom this syndrome occurred after spinal surgery. He had fractures in the dorso-lumbar vertebrae. The patient had undergone an osteosynthesis. On post-operative day 3, he had vomiting. Abdominal CT revealed the findings indicative of superior mesenteric artery syndrome: gastric dilatation and complete halt of the third part of the duodenum. We chose conservative treatment: the rest of the digestive tract, early parenteral nutrition, and correction of fluid and electrolyte imbalances. These treatments did not ameliorate the condition and thus we performed laparotomic gastro-jejunal bypass, which completely ameliorated the condition. The patient was discharged on the 7 postoperative day. We here summarize the clinical features and treatment fundamentals of this disorder

Key words: Superior mesenteric artery, duodenal obstruction, post traumatic spin surgery

Introduction :

The superior mesenteric artery syndrome is a rare syndrome due to the compression of the third portion of the duodenum by a vascular clamp formed by the superior mesenteric artery and the aorta, forming an angle of closure(1). Vascular compression of the duodenum was first described by Rokitsky in 1842, the first successful surgical procedure (duodenojejunosomy) was performed by Stavely in 1908(2,3). This syndrome can be secondary to several surgical such as a correction of a spinal deformity (dorsal kyphosis, scoliosis), post-traumatic surgery of the dorsal spine, also it can be secondary to medical circumstances (anorexia nervosa, extensive burns, sd of malabsorption)(4). We report an early case of Superior mesenteric artery syndrome following post-traumatic dorsolumbar spine surgery.

Case Présentation:

A24 years old, male, involed in a public road accident ,and presented with paraplegia after traumatism of the dorsal rachis.At the clinical examination: paraplegic patient, holds the bar, does not hold the mangazini, spinal syndrome at the positive dorsal level,with soft abdomen.

Dorsolumbar CT shows fracture of the right transverse process of D8, fracture of the transverse process of D9, communitated fracture of the vertebral body and the posterior arch of D10 with posterior wall recoil and intracanal fragment with another fragment facing the

transverse process of D11. Communicated fracture of the vertebral body of L1 with posterior wall recoil and displacement of a fragment at the medullary canal. Fracture of the left transverse process of L2. Right spinal costo-dislocation of D11 (figure 1a).

Patient had benefited from an osteosynthesis with the placement of 10 screws, 5 on each side D8 D9 D12 L1 L3 (figure 1b).

On the 3rd postoperative day the patient had postprandial vomiting with abdominal pain. On abdominal examination, there was abdominal bloating with lapping on an empty stomach. An abdominal CT scan was performed, had shown significant gastric and duodenal distension (D1 and D2) upstream of a transitional zone located at D3 passing between the aorta and the superior mesenteric artery with an estimated aorto-mesenteric angle of 11° (figure 2). Pancreas of normal size at the level of these different portions repressed by gastric distension without any noticeable defect of enhancement (figure 2). Serum electrolytes shows hyponatraemia 126 mEq/l, a kalaemia 3.5 mEq/l, and a correct renal assessment. A medical treatment of conditioning, with a nasogastric aspiration and correction of the internal balance sheet were required. Patient had benefited from a sub-mesocolic gastrojejunal bypass in anisoperistaltic omega with jejuno-jejunal anastomosis at the foot of the loop. The postoperative sequelae were simple with disappearance of vomiting, transit resumed at 3rd day postoperatively. On the 7th day postoperative serum electrolytes were normalized and the patient was satisfied fit and discharged to continue follow-up on out patient basis.

Discussion :

Superior mesenteric artery syndrome is caused by a reduction in the aorto-mesenteric angle(5,6), which can range from 6 to 15°. Several studies have found a frequency of aorto-mesenteric clip syndrome of 1% after spinal surgery (7), apart from scoliosis correction which varies from 0.5 to 4.7% (8).

The importance of the morphotype is identified as a risk factor for the occurrence of this syndrome. According to Shah et al., the taller and thinner the subjects are, the more likely they are to close their aorto-mesenteric clamp after posterior surgical correction or plaster (9). In the literature, the symptoms of this condition occur late, within a week after surgery. In our patient, the onset of signs of high occlusion was particularly early on the third day. The aggravation of vomiting episodes and the appearance of abdominal distension beyond 72 hours should be investigated, especially in subjects at risk.

The abdominal CT scan provides a diagnosis in relation to water-soluble transit, which is often poorly tolerated by the patient. The diagnosis is also confirmed by the measurement of the angle of the clamp on the scanner images with injection of contrast product. According to the literature, this angle is normally between 45° and 60°, whereas in the case of aorto-mesenteric forceps syndrome, the angle closes to between 6° and 15° (1, 10, 11). In our case

the scanner was efficient in making the positive diagnosis, and measuring the aorto-mesenteric angle which was 11 °.

Oesojejunal fibroscopy is useful to eliminate an intra luminal gastric obstacle, shows extrinsic compression and its location in the third duodenum.

Angiography is useful to measure the vascular angle and to determine the indication for possible surgical treatment (12). Studies suggest that medical treatment is recommended first. It consists of resting the gastrointestinal tract in combination with parenteral nutrition and correction of fluid and electrolyte disorders for several weeks (4,10). This therapeutic option aims at a weight gain for the patient, favorable to an increase in retroperitoneal fat around the mesenteric artery in order to open the angle of the forceps until the symptoms disappear (13,14).

At present, medical treatment is more and more recommended (15,16,17), although it increases the cost and length of hospitalization. Its effectiveness has been reported by Altioik et al in a series of 17 cases, only one of which required surgical treatment(15) . In our case, surgery was considered necessary because of hydroelectrolytic disorders. According to Kadji et al, surgical treatment is necessary in 75% of cases (14). The surgical options to be considered are lysis of the Treitz ligament, gastrojejunostomy and duodenojejunostomy. Recently, a laparoscopic approach has also been reported (18, 19, 20-21). In 1927, Wilkie concluded that duodenojejunostomy was the treatment of choice (22). In 2015, researchers at Cleveland Clinic reported the results of the largest series of patients who underwent minimally invasive duodenojejunostomy for Superior mesenteric artery syndrome , where all patients experienced symptomatic improvement immediately after surgery (23). The medical treatment is of great interest in the pre-surgical preparation in our case. Our patient benefited from a gastrojejunostomy at 3rd day of symptomatology with good clinical and biological improvement. The patient did well following surgery, she was gradually advanced to a soft diet and was discharged home on post-operative day 7 without complications. Motor rehabilitation was required for his paraplegia.

Conclusion :

Superior mesenteric artery syndrome is a rare complication of traumatic spine surgery. In this case our patient presented vomiting and abdominal pain on the 3rd day postoperative. Diagnosis was confirmed by abdominal CT scan. The management is multidisciplinary and the prognosis is generally favorable with rapid medical and surgical interventions.

Disclaimer regarding Consent and Ethical Approval:

As per university standard guideline, participant consent and ethical approval have been collected and preserved by the authors

References :

1. Welsch T, Büchler MW, Kienle P. Recalling Superior Mesenteric Artery Syndrome. Digestive Surgery. 2007Apr;24(3):149-56.
2. Von Rokitsansky CA. Handbook der Pathologischen Anatomie. 1st ed. Vienna: Wren, Braumuller and Seidel; 1842.
3. Stavely AL. Acute and chronic gastromesenteric ileus with cure in a chronic case by duodenojejunostomy. Bull John Hopkins Hosp. 1908;19:252.
4. Traore MM, Leye PA, Bah MD, et al. [Early form of Wilkie's syndrome: a rare complication of scoliosis surgery, about a case and review of the literature]. The Pan African Medical Journal. 2016 ;25:90
5. Salem A, Al Ozaibi L, Nassif SM, Osman RA, Al Abed NM, Badri FM. Superior mesenteric artery syndrome: a diagnosis to be kept in mind (case report and literature review). Int J Surg Case Rep. 2017;34:84-6.
6. Mansberger AR Jr., Hearn JB, Byers RM, Fleisig N, Buxton RW. Vascular compression of the duodenum. Emphasis on accurate diagnosis. Am J Surg. 1968;115:89-96.
7. Zadegan F, Lenoir T, Drain O et al. Syndrome de la pince aorto-mésentérique après correction d'une déformation rachidienne: À propos d'un cas et revue de la littérature. Rev Chir Orthop Réparatrice Appar Mot. 2007 Apr; 93(2):181-5.
8. Tsirikos AI, Anakwe RE, Baker ADL. Late presentation of superior mesenteric artery syndrome following scoliosis surgery: a case report. J Med Case Reports. 2008 Jan ; 2 : 9.

9. Shah MA, Albright MB, Vogt MT, Moreland MS. Superior mesenteric artery syndrome in scoliosis surgery : weight percentile for height as an indicator of risk. *J Pediatr Orthop*. 2003 Sep-Oct;23(5):665-66.
10. Ooi GC, Chan KL, Ko KF, Peh WE. Computed tomography of the superior mesenteric artery syndrome. *Clin Imaging*. 1997 May-Jun ;21(3):210-212.
11. Fall M et al. Le syndrome de la pince aorto-mésentérique chez l'enfant : à propos d'un cas primitif. *Pan Afr Med J*. 2014 Oct 15;19:151.
12. Welsh T, Büchler MW, Kienle P. recalling superior mesenteric artery syndrome. *Dig Surg*. 2007;24:149-56.
13. Loeb T, Loubert G, Morsly R, Gabillet JM, Pasteyer J. Syndrome de l'artère mésentérique supérieure. *Ann Fr Anesth Réanim*. 1999 Nov;18(9):1000-4.
14. Kadji M, Naouri A, Bernard P. Syndrome de la pince aorto-mésentérique: à propos d'un cas. *Ann de chir*. 2006 Jul-Aug;131(6-7):389-392.
15. Walker C, Kahanovitz N. Recurrent superior mesenteric artery syndrome complicating staged reconstructive spinal surgery : Alternative methods of conservative treatment. *J Pediatr Orthop*. 1993 Feb;3(1):77-80.
16. Adson DE, Mitchell JE, Trenkner SW. The superior mesenteric artery syndrome and acute gastric dilatation in eating disorders: a report of two cases and a review of literature. *Int J Eat Disord*. 1997 Mar;21(2):103-114.
17. Hutchinson DT, Bassett GS. Superior mesenteric artery syndrome in pediatric orthopedic patients. *Clin Orthop*. 1990 Jan; (250):250-7.
18. Pottorf BJ, Husain FA, Hollis HW Jr, Lin E. Laparoscopic management of duodenal obstruction resulting from superior mesenteric artery syndrome. *JAMA Surg*. 2014 Dec; 149(12): 1319–22.
19. Sun Z, Rodriguez J, McMichael J, Walsh RM, Chalikonda S, Rosenthal RJ, et al. Minimally invasive duodenojejunostomy for superior mesenteric artery syndrome: a case series and review of the literature. *Surg Endosc*. 2015 May; 29(5): 1137–44.
20. Shinji S, Matsumoto S, Kan H, Fujita I, Kanazawa Y, Yamada T, et al. Superior mesenteric artery syndrome treated with single incision laparoscopy-assisted duodenojejunostomy. *Asian J Endosc Surg*. 2015 Feb; 8(1): 67–70.
21. Kirby GC, Faulconer ER, Robinson SJ, Perry A, Downing R. Superior mesenteric artery syndrome: a single centre experience of laparoscopic duodenojejunostomy as the operation of choice. *Ann R Coll Surg Engl*. 2017 Jul; 99(6): 472–5.
22. Wilkie D. Chronic duodenal ileus. *Am J Med Sci*. 1927; 173(5): 643–8.
23. Sun Z, Rodriguez J, McMichael J, Walsh RM, Chalikonda S, Rosenthal RJ, et al. Minimally invasive duodenojejunostomy for superior mesenteric artery syndrome: a case series and review of the literature. *Surg Endosc*. 2015 May; 29(5): 1137–44.

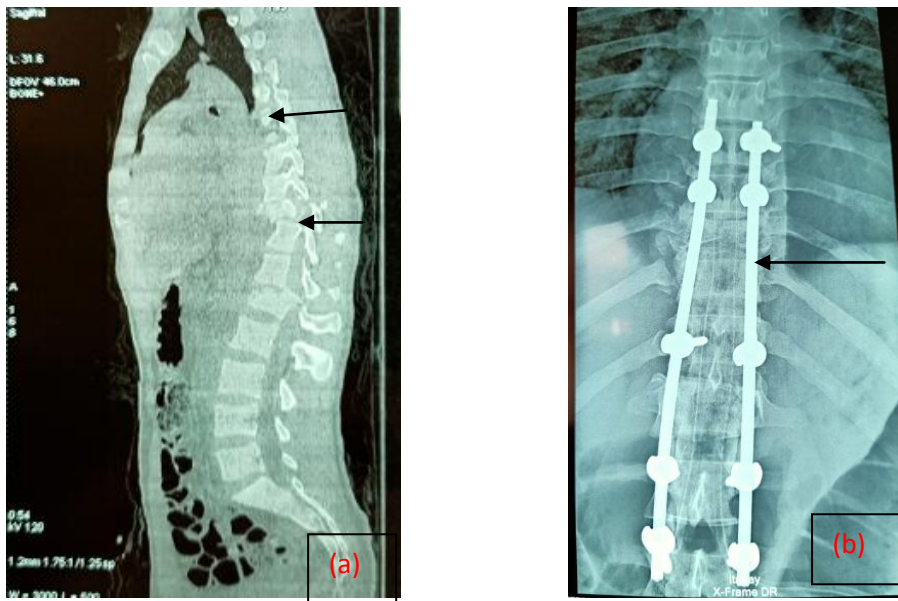


figure1: communal fractures of the Dorsolumbar Spine before (a) and after (b) placement of osteosynthesis material

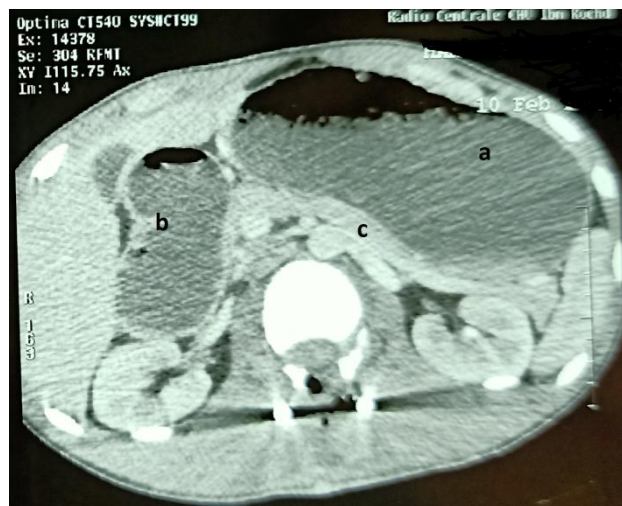

figure 2:CT scan showing gastric and duodenal dilatation compressing the pancreas

a: stomach b: duodenum c: pancreas