

Retrohyaloidal macular haemorrhage following a Valsalva manoeuvre: case report and review of literature

ABSTRACT :

A pre-retinal haemorrhage can complicate several pathologies including Valsalva retinopathy. It can cause symptomatic visual disturbances that lead the patient to seek medical attention. We report the case of a 39-year-old patient, with no particular pathological history, who has a sudden drop in visual acuity in her right eye. This symptomatology appeared a few minutes after defecation following constipation. The ophthalmological examination found a corrected visual acuity in the right eye that was quantified by counting the fingers at close range. The fundus revealed a macular haemorrhage suspended in a pigeon's nest. The diagnosis of spontaneous right retrohyaloidal haemorrhage secondary to cephalic venous hyper pressure was retained. A Yag laser membranotomy was performed at a distance from the fovea. The evolution was favourable with an increase in visual acuity to 6/10. The main aetiology of retrohyaloidal haemorrhages is rarely venous cephalic hypertension. However, Valsalva's retinopathy should always be considered in case of effort with chest blockage in inspiration.

Keywords: Retro-hyaloidal haemorrhage, Macula, Valsalva retinopathy, membranotomy, Nd:YAG laser.

Introduction:

Several pathologies can cause pre-retinal haemorrhage: proliferative diabetic retinopathy, arterial or venous retinal macro-aneurysms, Valsalva retinopathy, hemopathies, venous branch occlusions, or post-traumatic origin [1]. Valsalva retinopathy is a single, rarely multiple, usually unilateral pre-macular haemorrhage described in 1972 by Thomas Duane [2]. Therapeutic abstention and monitoring are recommended initially because its evolution is often spontaneously favourable. If there is no or partial macular haemorrhage, an Nd-YAG laser membranotomy is considered.

We report a case of massive pre-macular haemorrhage with no aetiology found with excellent visual recovery, obtained after Nd-YAG laser membranotomy.

Presentation of Case:

Female, 39 years old, with a rapidly progressive decrease in visual acuity of the right eye, limited to a finger count at one meter. There was no medical history or evidence of oral anticoagulant use, non-steroidal anti-inflammatory drugs, pre-existing hemostasis or hematuria.

Decreased visual acuity in the right eye is described a few minutes after a bowel movement in a context of constipation.

The corrected visual acuity in the right eye was quantified by counting the fingers at close range. Bio-microscopic examination of the anterior segment was normal. After dilation, the examination of the fundus found a pigeon's nest haemorrhage, with a horizontal upper level and a lower edge with an upper concavity [Fig1]. It masked the macula and the lower perimacular area. Its dimension was important, it measured about 6 papillary diameters. In a thin slit, the examination confirmed his retro-hyaloid position.

Fluorescein angiography was performed and found no retinal vessel abnormalities in the arterial tortuosity syndrome [Fig 2]. The OCT showed a single membrane (the posterior hyaloid and the fused internal limiting membrane) covering the pre-retinal haemorrhage [Fig 3].

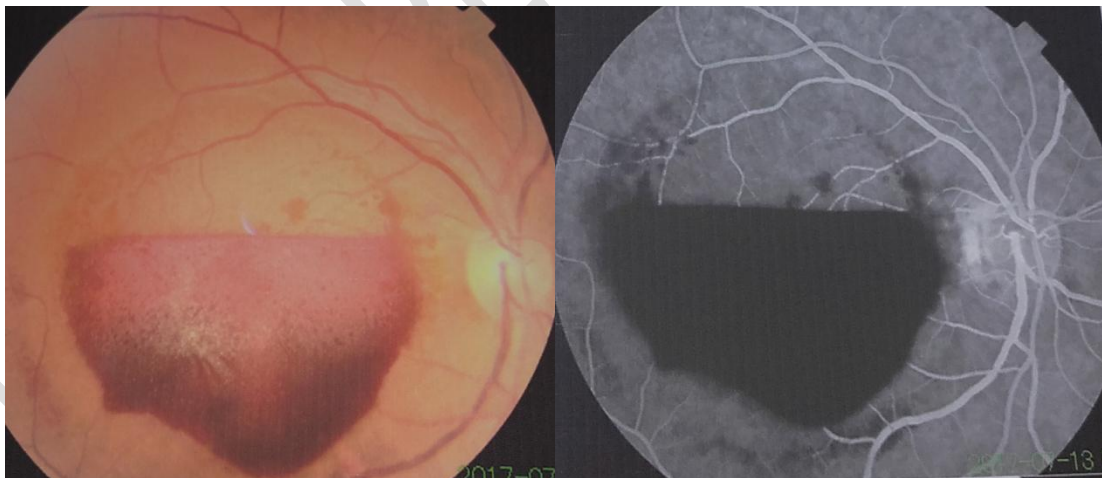


Fig 1: Fundus of the right eye: voluminous retrohyaloid macular and lower peri-macular hematic collection

Fig 2: Fluorescein angiography: the absence of retinal vessel abnormalities eliminating arterial tortuosity syndrome.

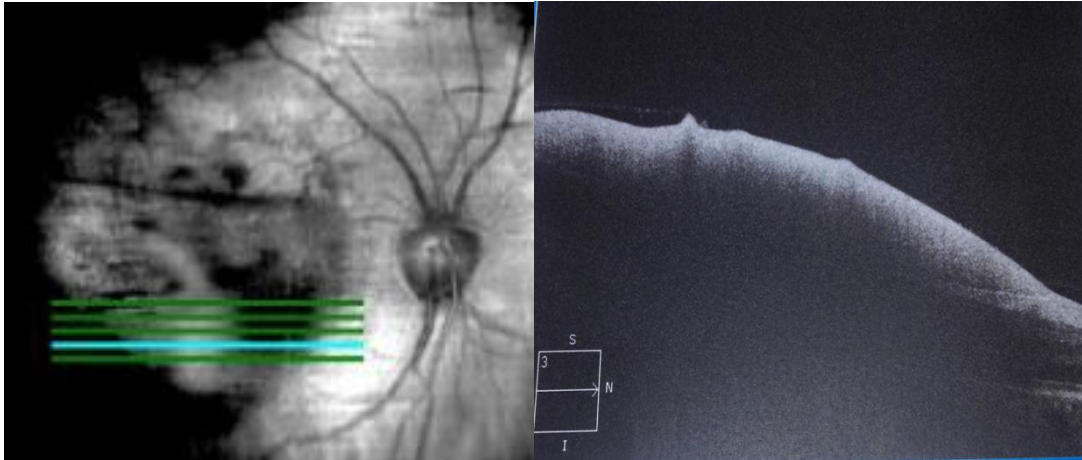


Fig 3: Initial macular optical coherence tomography in the horizontal section of the lower part of the hematic collection: hyper-reflective membrane (merged ILM and posterior hyaloid) covering the hypo-reflective pre-retinal hematoma.

The hypothesis of a drug or toxic aetiology was ruled. Blood pressure was normal at 120/70 mmHg. The electrocardiogram and ultrasound of the neck vessels showed no lesions. The blood test did not show diabetes, bleeding disorders or inflammatory syndrome. Liver workup was normal. This clinical, radiological and biological assessment made it possible to eliminate other etiologies of pre-retinal haemorrhage and to make the diagnosis of retrohyaloidal macular haemorrhage, secondary to venous cephalic hyper pressure explained by the Valsalva manoeuvre. The diagnosis of Valsalva's retinopathy is retained.

In the absence of regression of the pre-macular haemorrhage after one month of observation, Nd-YAG laser treatment was performed, creating a drainage hole in the posterior hyaloid and the internal limiting membrane (ILM). Laser impacts were made on the lower part of the hemorrhagic pocket at 1.5 papillary diameters of the fovea (to facilitate drainage), the power was gradually increased until perforation of the posterior hyaloid at 7 mJ with visualization of a hematic flux in the vitreous cavity.

48 hours after the Yag laser membranotomy, the patient reported an improvement in right visual function. The first check-up was done 15 days later, he regained visual acuity in his right eye at 6/10 in distance vision and Parinaud 3 in near vision. The fundus showed resorption of pre-retinal haemorrhage with some lower pre-macular hematicus and the presence of residual lower intravitreal haemorrhage [Fig 4]. Two months later after the stabilization of corrected visual acuity at 8/10 P2. The control of macular OCT revealed two distinct hyper-reflective membranes: the inner limiting membrane covering optically space and corresponding to pre-retinal haemorrhage after laser drainage and the posterior hyaloid overlying the first membrane [Fig 5].

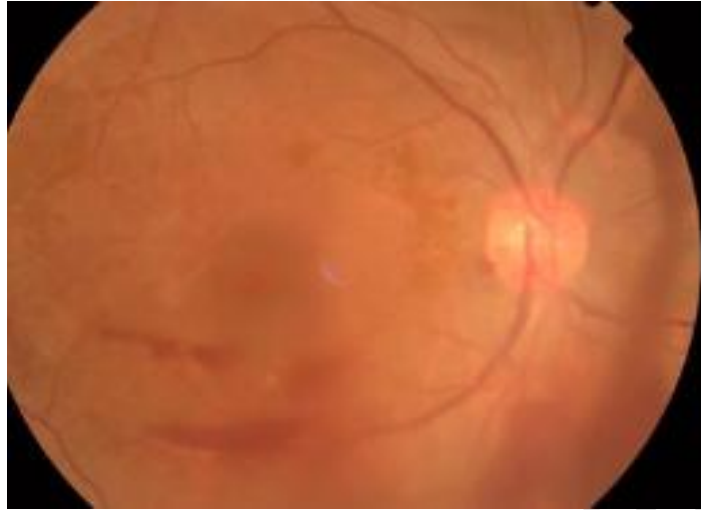


Fig 4: Right fundus after one month of Yag laser membranotomy: Resorption of the retro-hyaloid macular hematoma with the persistence of intramuscular pre-retinal haemorrhage and residual intravitreal haemorrhage.

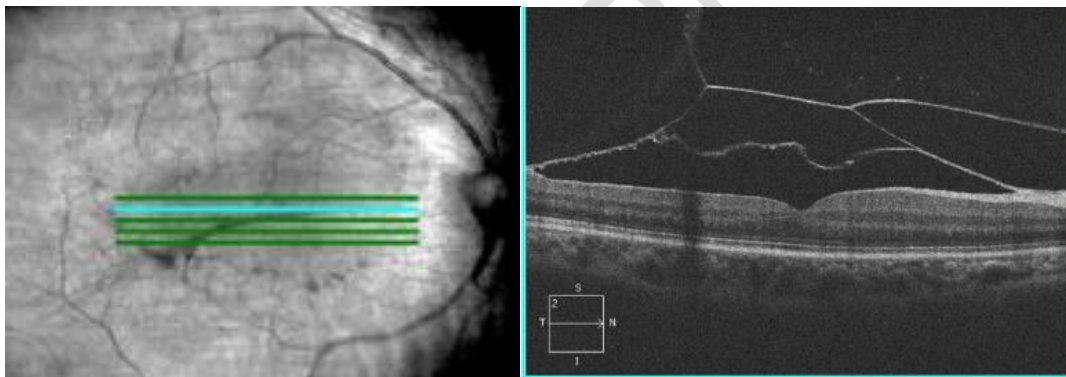


Fig 5: Macular optical coherence tomography in horizontal section, one month after Yag laser membranotomy: Two hyper-reflective membranes: the inner limiting membrane delimiting an optical space corresponding to the drained retro-hyaloid hematoma and a second one (the posterior hyaloid) overlying the first one.

Discussion:

Spontaneous haemorrhages in the hyaloid cavity affect 7 cases per 100,000 inhabitants per year [3]. However, these figures would be underestimated as they do not take into account patients with asymptomatic bleeding who do not come for a consultation. Vitreal haemorrhages following a Valsalva manoeuvre are rarely described in the literature [3].

Valsalva retinopathy (VR) is a rare disease, affecting young active subjects, never followed for ophthalmologic or systemic pathology [4].

Pre-retinal haemorrhages often sit in the space between the internal limiting membrane (ILM) and the posterior hyaloid. More rarely, they are located between the retinal nerve fibre layer and the ILM [1]; this location has been described in Valsalva retinopathy and Terson syndrome [5,6].

The pathophysiological mechanism of retrohyaloidal haemorrhages following the Valsalva manoeuvre is a thoracic blockage in pulmonary hyper pressure associated with an increase in intra-abdominal pressure. This has repercussions on cephalic and therefore retinal venous circulation and consequently an increase in intraocular venous pressure [4].

The causes of the Valsalva manoeuvre are multiple: sneezing, constipation, scuba diving. There are physiological adhesions of the vitreous to the retinal vessels. Under the effect of retinal venous hyper pressure, vitreous traction on a vein causes it to rupture, the vein ruptures in the vitreous cavity or the retrohyaloid space. This pathophysiological mechanism is confirmed by the literature, which mentions that the vessel responsible for the haemorrhage is a vein generally located in the upper temporal quadrant [4, 7].

M.H. Errera et al [9] showed in his case report, the interest of optical coherence tomography to locate a macular haemorrhage. The OCT makes it possible to highlight the site of the haemorrhage: pre- or sub-retinal, which is an aid to the management of the haemorrhage [1]. In Valsalva retinopathy, the bleeding is located between two membranes of different optical reflectivity: the nerve fibre layer and the ILM (the most hyper-reflective) [8]. However, the diagnostic difficulty in OCT of bleeding under the ILM lies in the fact that this type of bleeding forms a dome showing only a single membrane the ILM and posterior hyaloid fused [9].

In Valsalva retinopathy, the spontaneous functional prognosis is often favourable. However, the toxicity of haemoglobin, especially if it remains in contact with the layer of retinal nerve fibres for a long time, could have a deleterious effect on functional recovery capacity [4,10], hence the need to monitor these patients closely and to decide, if necessary, on appropriate treatment to facilitate haematological drainage [17].

Three therapeutic approaches are to be considered when faced with pre-retinal macular haemorrhage: initially, no treatment with close monitoring, opening of the posterior hyaloid (membranotomy) with a YAG or Argon laser and vitrectomy associated with drainage. The therapeutic decision depends on the evolution of visual acuity and essentially on whether or not the bleeding regresses spontaneously [9].

In 1988, Faulborn first performed a YAG laser membranotomy, which allows blood to drain into the vitreous cavity in the case of pre-macular retrohyaloid haemorrhage [11]. Early treatment by membranotomy with the Yag laser is not only inexpensive and minimally invasive but above all allows for a rapid improvement in visual acuity. The selected lesions must meet certain indications: The haemorrhage must be localized in the foveolar area [14]; the size of the haemorrhage must be greater than three papillary diameters to reduce the risk of macular complications induced by the mechanical trauma of laser impacts because the blood acts as a real shock absorber of the wave on the ILM [16]. The duration of bleeding progression should be three weeks less [4]. The laser must be applied in the lower area which is the most domed of the haematoma [4]. The power of the impacts must be increased progressively until the perforation of the membrane without exceeding 9 mJ [15]. After laser membranotomy, the patient should remain in a half-seated position to allow rapid emptying into the vitreous cavity and reduce the risk of rebleeding [4]. In another series, Oscar Kuruville et al [16] described the successful use of the Nd: YAG laser to drain three out of four acute cases of premacular haemorrhage due to Valsalva retinopathy.

Monitoring should be extended with a mean delay of 3 to 4 weeks [7,12] to detect the possible development of a secondary epi-retinal membrane [9,13]. Classically, visual acuity recovery is stable at fin for the first month. For lesions greater than or equal to nine papillary diameters, stabilization is delayed for up to three months [10].

Conclusion:

Valsalva retinopathy is a rare cause of retro-hyaloidal haemorrhage, affecting young patients with no specific systemic or local pathology that could affect the prognosis for recovery. However, this aetiology should be considered when there is a notion of closed glottis exhalation effort, preceding the decrease in visual acuity. In the vast majority of cases, the trend is favourable. The treatment consists of drainage by YAG laser membranotomy if the bleeding has not regressed after three weeks of simple monitoring.

Ethical Approval:

As per international standard, written ethical approval has been collected and preserved by the author(s).

Consent :

As per international standard, patient's consent has been collected and preserved by the authors.

References :

- [1] Errera M.H, Barale P.O, Danan-Husson A, et al. Preretinal hemorrhage: 2 cells report. Images in Ophthalmology 2007; 1:1
- [2] Duane TD. Valsalva hemorrhagic retinopathy. Trans Am Ophthalmol Soc 1972;70:298-313
- [3] Guigon-Souquet B, Salaun N, Macarez R, et al. Retrohyaloidal hemorrhage secondary to a Valsalva manoeuvre. J Fr Ophthalmol 2004; 27: 10
- [4] Matontia F, Donadieu V, Hoffart L, et al. Early Nd:YAG laser treatment of Valsalva retinopathy: results from five cases and literature review. Journal français d'ophtalmologie revue 2013 ; 36 :604-609
- [5] Meyer CH, Mennel S, Rodrigues EB, et al. Is the location of Valsalva hemorrhages submembranous or subhyaloidal? Am J Ophthalmol 2006;141(1):231
- [6] McCarron MO, Alberts MJ, McCarron P. A systematic review of Terson's syndrome: frequency and prognosis after subarachnoid haemorrhage. J Neurol Neurosurg Psychiatry 2004;75(3):491-3
- [7] Ulbig MW, Mangouritsas G, Rothbacher HH, et al. Long-term results after drainage of premacular subhyaloid hemorrhage into the vitreous with a pulsed Nd-Yag laser. Arch Ophthalmol 1998;116:1465-9
- [8] Tatlipinar S, Shah SM, Nguyen QD. Optical coherence tomography features of sub-internal limiting membrane haemorrhage and pre-retinal membrane in Valsalva retinopathy. Can J Ophthalmol 2007;42:129-30
- [9] Errera M.H, Barale P.O, Danan-Husson A, et al. Interest of optical coherence tomography to locate a macular hemorrhage: About two cases. J Fr Ophthalmol 2008; 31: e20
- [10] Durukan AH, Kerimoglu H, Erdurman C, et al. Long-term results of Nd:YAG laser treatment for premacular subhyaloid haemorrhage owing to Valsalva retinopathy. Eye 2008; 22: 214—8
- [11] Faulborn J. Treatment of a diabetic premacular hemorrhage with the Q-switched Neodymium:YAG laser. Spectrum ophthalmology 1988;2:33-5
- [12] Dahreddine M, Eldirani H, Mutsinzi E, et al. Retinal arterial macroaneurysm complicated by premacular hemorrhage: treatment by YAG laser disruption. J Fr Ophthalmol 2011;34: 131
- [13] Kwok AK, Lai TY, Chan NR. Epiretinal membrane formation with internal limiting membrane wrinkling after Nd:YAG laser membraneotomy after Valsalva retinopathy. Am J Ophthalmol, 2003; 136: 763-6
- [14] Khan MT, Saeed MU, Shehzad MS, et al. Nd:YAG laser treatment for Valsalva premacular hemorrhages: 6 month follow-up: alternative management options for preretinal premacular hemorrhages in Valsalva retinopathy. Int Ophthalmol 2008; 28:325—7
- [15] Jampol LM, Goldberg MF, Jednock N. Retinal damage from a Q-switched YAG laser. Am J Ophthalmol 1983; 96:326—9
- [16] Oscar Kuruvilla, Metasebia Munie, Manthan Shah, Uday Desai, et al. Nd:YAG Membranotomy for

Preretinal Hemorrhage Secondary to Valsalva Retinopathy. Saudi Journal of Ophthalmology 2014; 28: 145–151

- [17] Souteyrand G, Guièze R, Berrod J.-P, et al. Valsalva retinopathy with small bilateral pre-macular hematoma associated with leukemia: Treatment by Nd:YAG LASER. Journal français d'ophtalmologie 2014 ;37 :e107—e11

UNDER PEER REVIEW