

ADERMATOGLYPHIA: Challenges and Prospects in Diagnosis

ALADEH DIEPREBI A, ALTRAIDE DASETIMA D, OTIKE-ODIBI BOLAJI, BELEMA ABBEY
DERMATOLOGY UNIT, DEPARTMENT OF INTERNAL MEDICINE, UNIVERSITY OF PORT-
HARCOURT TEACHING HOSPITAL, ALAKAHIA, RIVERS STATE, NIGERIA

ARTICLE TYPE : REVIEW

FUNDING SOURCES: NONE

NO CONFLICT OF INTEREST.

NO ETHICAL ISSUES .

ABSTRACT: BIOMETRIC METHODS ARE INCREASINGLY BEING USED ALL OVER THE WORLD FOR INDIVIDUAL IDENTIFICATION AND AUTHENTICATION. MOST METHODS ARE COMPLEX, HOWEVER, THE USE OF FINGERPRINTS ARE LESS COMPLEX, CHEAPER, READILY AVAILABLE AND THUS WIDELY USED COMPARED TO OTHER MODALITIES. THERE ARE THREE BASIC FINGERPRINT PATTERNS WHICH ARE THE ARCHES, LOOPS AND WHORLS .THE AVAILABILITY OF FINGERPRINTING HAS EXPOSED MORE CASES OF ADERMATOGLYPHIA WHICH IS CLINICALLY DEFINED AS THE LOSS OF FINGERPRINTS. IT CAN BE CONGENITAL OR ACQUIRED, REVERSIBLE OR IRREVERSIBLE. DIAGNOSIS OF MOSTLY THE CONGENITAL FORMS WILL REQUIRE MOLECULAR GENETIC ANALYSIS WHICH MAY BE DIFFICULT TO ACCESS IN THIS PART OF THE WORLD AND VOLAR PAD BIOPSY WHICH INDIVIDUALS MAY NOT CONSENT TO. THE NEED FOR ALTERNATIVE MODALITIES OF IDENTIFICATION SHOULD BE IN PLACE IN CASES WHERE FINGERPRINTING IS AN ISSUE. THIS ARTICLE WILL HIGHLIGHT THE FINGERPRINT PATTERNS, THE PREVALENCE AND AETIOLOGY OF ADERMATOGLYPHIA. IT WILL ALSO REVIEW THE CHALLENGES FACED WHEN DIAGNOSING ADERMATOGLYPHIA AND FUTURE PROSPECTS WHICH INCLUDES OTHER ADVANCED BIOMETRIC METHODS FOR PATIENTS.

KEYWORDS: ADERMATOGLYPHIA, BIOMETRIC, FINGERPRINTING, WHORLS, LOOPS, ARCHES, PROSPECTS.

1. INTRODUCTION

THE SCIENTIFIC STUDY OF INTRICATE PATTERNS AND FINGERPRINTS FROM PALMS, FINGERS, SOLES AND TOES IS REFERRED TO AS DERMATOGLYPHICS[1]–[3]. THESE NATURALLY OCCURRING PATTERNS ARE UNIQUE TO AN INDIVIDUAL AND REMAIN UNCHANGED FROM BIRTH UNTIL DEATH[2], [4], [5]. THE FINGERPRINTS ARE NOT EVEN SIMILAR IN MONOZYGOTIC TWINS. FINGERPRINTING KNOWN AS DACTYLOGRAPHY IS THE SINGLE MOST WIDELY UTILIZED METHOD FOR INDIVIDUAL IDENTIFICATION AND AUTHENTICATION (I&A)[4], [5]. ADERMATOGLYPHIA IS CLINICALLY DEFINED AS THE CONGENITAL OR AN ACQUIRED LOSS OF THE EPIDERMAL RIDGE PATTERN[4], [6], [7].

IT CAN ALSO BE COMPLETE OR PARTIAL LOSS OF THE EPIDERMAL RIDGE PATTERN. IT CAN ALSO BE REVERSIBLE OR IRREVERSIBLE. IT IS ALSO CALLED “IMMIGRATION DELAY DISEASE”[5], [6], [8].

PATIENTS WITH THIS CONDITION ARE FACED WITH DIFFICULTIES WHEN UNDERGOING BIOMETRICS AND THIS CAN BE BURDENSOME AND DEPRESSING FOR PATIENTS ESPECIALLY IF IT IS IRREVERSIBLE AND MORE SO AS ALTERNATIVE METHODS OF IDENTIFICATION, AUTHENTICATION AND VERIFICATION ARE NOT READILY AVAILABLE.

2. HISTORICAL PERSPECTIVE

IN 1684, A LEARNED AND INGENIOUS PHYSICIAN, NEHEMIAH GREW, PUBLISHED THE FIRST DESCRIPTION OF THE EPIDERMAL RIDGES WHICH MAKE CHARACTERISTIC PATTERNS WHEN PRINTS ARE TAKEN OF FINGERTIPS[3], [9] IN 1880, THE FIRST PAPER ON FINGERPRINTS WAS PUBLISHED BY DR HENRY FAULDS EXPRESSING IT AS IMPORTANT FOR INDIVIDUALIZATION[10]. IN 1890, SIR GALTON DEMONSTRATED THE VALUE OF FINGERPRINTS FOR PERSONAL IDENTIFICATION AND THEIR PERMANENCE THROUGHOUT LIFE[9], [11]. ANOTHER RESEARCHER, JAUN VUCETICH IN 1892 FIRST USED FINGERPRINTS TO IDENTIFY CRIMINALS IN THE COURT ROOM[3]. DERMOLYPTICS WAS COINED BY CUMMINS AND MIDLO IN 1926, DERMA” MEANS SKIN AND “GLYPHIC” MEANS CARVINGS[5]. BAIRD (1964) DESCRIBED A KINDRED OF IRISH-AMERICAN EXTRACTION IN WHICH 13 OF 24 MEMBERS OF THREE GENERATIONS SHOWED AN ABSENCE OF DERMAL RIDGES[12].

IN 2007, A SWISS WOMAN WAS DENIED ENTRY INTO THE US BECAUSE SHE HAD NO FINGERPRINTS[6]. SIMILAR ISSUE WAS REPORTED IN BENUE STATE, NIGERIA, WHERE A CHRISTIAN PILGRIM WAS DENIED THE E-PASSPORT BY THE NIGERIAN IMMIGRATION[13].

OVER THE PAST 50 YEARS, A LOT OF WORK HAS BEEN DONE ON VARIOUS ASPECTS OF DERMOLYPTICS AND DEVELOPMENTAL DISORDERS. MOST PATIENTS WITH CHROMOSOMAL DISORDERS LIKE DOWN SYNDROME, EDWARD SYNDROME, PATAU SYNDROME HAVE ABNORMAL DERMOLYPTIC PATTERNS[5]

3. EPIDEMIOLOGY OF ADERMOLYPTIA

THERE IS DEARTH OF LITERATURE ON THE PREVALENCE OF ADERMOLYPTIA AS EXTENSIVE WORK HAS NOT BEEN DONE , HOWEVER, THE NEED FOR BIOMETRICS IN IDENTIFICATION AND AUTHENTICATION AND FORENSICS APPLICATION HAVE EXPOSED CASES OF ADERMOLYPTIA, SUCH THAT THERE IS INCREASING INTEREST.

HABER ET AL CONDUCTED A NATIONAL SURVEY IN LEBANON IN COLLABORATION WITH THE MINISTRY OF INTERNAL AFFAIRS IN 2014 WHICH RECORDED 0.18% OF ADERMOLYPTIA WITH A FEMALE PREDOMINANCE AND AN INCREASED INCIDENCE IN THE AGING POPULATION WITH DERMATITIS AS THE COMMONEST CAUSE[14].

TWO REKNOWN PROFESSORS OF THE UNIVERSITY HOSPITAL BASEL, SWITZERLAND STUDIED THE SWISS FAMILY WITH ADERMATOGLYPHIA AND FOUND THAT NINE(9) OUT OF THE SIXTEEN(16) MEMBERS HAD ADERMATOGLYPHIA, CONFIRMING THAT IT HAS A GENETIC AETIOLOGY[15].

LOSS OF FINGERPRINTS CAN BE CONGENITAL OR ACQUIRED[5], [6]. THE CONGENITAL FORM COULD BE PART OF A COMPLEX SYNDROME AND THE PREVALENCE WILL MIRROR THAT OF THE SYNDROME. INDIVIDUALS WITH COMPLETELY MISSING FINGERPRINTS AS AN ISOLATED FINDING IS EXTREMELY RARE. FOUR GENERATIONS WERE REPORTED TO HAVE THIS ISOLATED FORM OF ADERMATOGLYPHIA INHERITED IN AN AUTOSOMAL DOMINANT FASHION[8], [12]. THE ACQUIRED FORMS ARE MORE COMMON AND COULD RESULT FROM OTHER DERMATOLOGICAL CONDITIONS[5], [14], [16].

AT THE DERMATOLOGY UNIT OF THE UNIVERSITY OF PORT-HARCOURT TEACHING HOSPITAL, RIVERS STATE, NIGERIA, THERE HAS BEEN THREE RECORDED CASES OF ADERMATOGLYPHIA IN THE PAST FIVE(5) YEARS [PERSONAL COMMUNICATION] . THE MOST RECENT BEING A 21 YEAR FEMALE UNDERGRADUATE WHO HAD INABILITY OF FINGERPRINTS TO BE CAPTURED DURING BIOMETRIC SCREENING BY JOINT ADMISSIONS AND MATRICULATION BOARD, BANK VERIFICATION NUMBER AND NATIONAL IDENTITY CARD REGISTRATION AT DIFFERENT TIMES. SHE ALSO FOUND IT DIFFICULT TO USE THE FINGERPRINT APPLICATION AS A MEANS OF SECURING HER ANDROID PHONE.

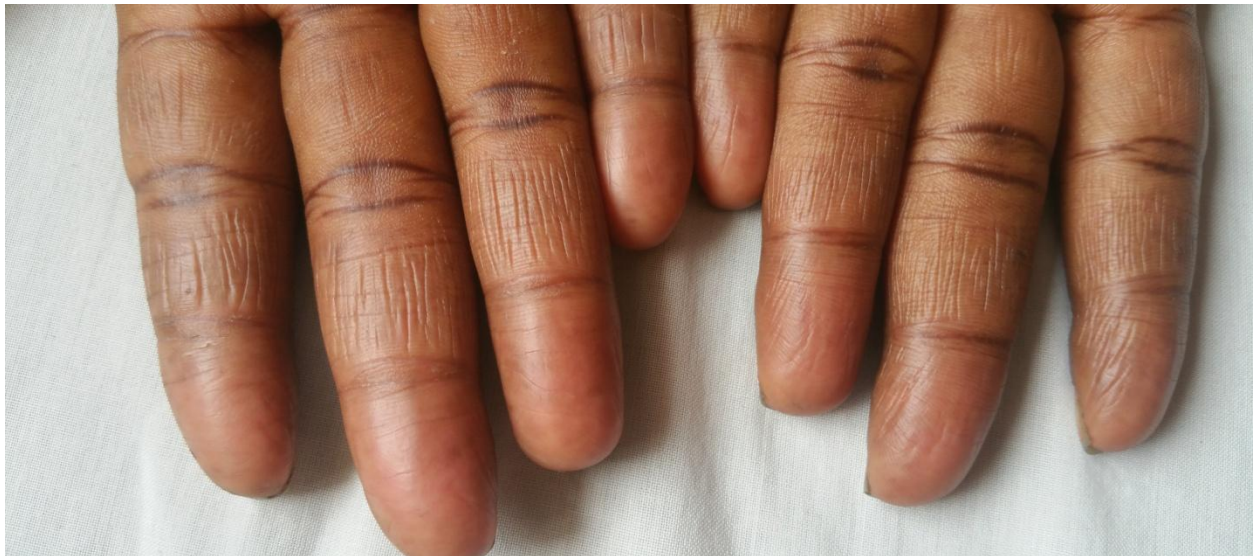

FIGURE 1: ISOLATED CONGENITAL ADERMATOGLYPHIA IN A 21-YEAR-OLD FEMALE UNDERGRADUATE PATIENT SHOWING FINGERS OF BOTH HANDS.

4. FINGERPRINT PATTERNS

THE FINGERPRINT PATTERN OF THE EPIDERMAL RIDGES FORM WHORLS, ARCHES, AND LOOPS THAT ARE THE BASIS FOR EACH PERSON'S UNIQUE FINGERPRINTS[3], [4] THESE, LIKE DNA ARE UNIQUE TO EVERY INDIVIDUAL AND ARE USED AS MEANS OF IDENTIFICATION AND AUTHENTICATION. THEY ARE UNIQUE AND DIFFICULT TO ALTER MAKING THEM LIFELONG MARKERS FOR IDENTIFICATION OF INDIVIDUALS.

THERE ARE THREE BASIC FINGERPRINT PATTERN.

- WHORL
- ARCHES
- LOOP

THE CLASSIFICATION OF FINGERPRINT PATTERN IS BASED ON THE NUMBER OF TRIRADII PRESENT[2][17]. A TRIRADIUS IS THE MEETING PLACE OF THREE SYSTEMS OF RIDGE WHOSE ELEMENT LIE APPROXIMATELY PARALLEL TO ONE ANOTHER AT THIS POINT. TYPICALLY A TRIRADIUS OCCURS AT THE BASE OF EACH DIGIT EXCEPT THE THUMB. THESE ARE CALLED THE DIGITAL TRIRADII AND ARE DESIGNATED A,B,C,D[1]–[3], [17], [18].

OTHER LANDMARKS OF IMPORTANCE INCLUDE THE CORE, THE RADIANTS AND THE DELTA. A CORE IS THE APPROXIMATE CENTER OF THE PALM. IN RIDGE COUNTING THE POINT OF CORE (NOT THE WHOLE CORE) IS USED. THE RADIANTS ARE RIDGES THAT ARISE FROM TRIRADIUS AND ENCLOSE THE PATTERN AREA WHILE THE DELTA IS THE POINT ON A RIDGE, AT OR IN FRONT OF AND NEAREST THE CENTRE OF DIVERGENCE OF THE TYPE LINES[1]–[3], [17], [18].

WHORL: IT IS DISTINGUISHED BY CONCENTRIC DESIGN. THE MAJORITY OF THE RIDGES MAKE CIRCUITS AROUND THE CORE. TRUE WHORLS TYPICALLY POSSESS TWO TRIRADII. THERE ARE ALSO COMPOSITE PATTERNS IN WHICH TWO OR MORE DESIGNS ARE COMBINED IN ONE PATTERN AREA. IT CONTAINS TWO OR MORE DELTAS AND IS SEEN IN ABOUT 25 TO 35 % OF FINGER PRINT PATTERNS. THERE ARE SIX TYPES OF WHORLS: CONCENTRIC WHORL, SPIRAL WHORL, MIXED WHORL, CENTRAL POCKET WHORL, TWIN WHORL AND ACCIDENTAL WHORLS[1]–[3], [17], [18].

ARCHES: IN THIS PATTERN, THE RIDGES PASS FROM ONE MARGIN OF THE DIGIT TO THE OTHER WITH A GENTLE, DISTALLY BOWED SWEEP. IT IS SEEN IN 5% OF FINGERPRINT PATTERN. THERE IS NO TRIRADIUS. THERE ARE FOUR TYPES OF ARCH PATTERNS: PLAIN ARCHES, RADIAL ARCHES, ULNAR ARCHES AND TENTED ARCHES[1]–[3], [17], [18].

LOOPS: IT POSSESSES ONLY ONE TRIRADIUS. THE RIDGES CURVE AROUND ONLY ONE EXTREMITY OF THE PATTERN, FORMING THE HEAD OF THE LOOP. FROM THE OPPOSITE EXTREMITY OF THE PATTERN, RIDGES FLOW TO THE MARGIN OF THE DIGIT, THIS EXTREMITY OF THE PATTERN MAY THUS BE DESCRIBED AS 'OPEN'. ACCORDING TO THIS, LOOPS MAY FURTHER BE OF TWO TYPES, ULNAR LOOP AND RADIAL LOOP. IT IS SEEN IN ABOUT 60 TO 70% OF FINGER PRINTS[1]–[3], [17], [18].

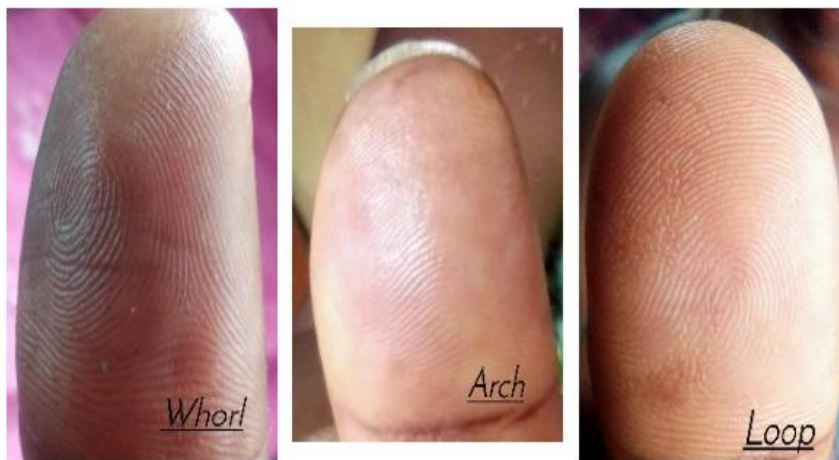


FIGURE 2: MAGNIFYING GLASS IMAGE OF THE THREE FINGERPRINT PATTERNS: WHORLS, ARCH AND LOOP.

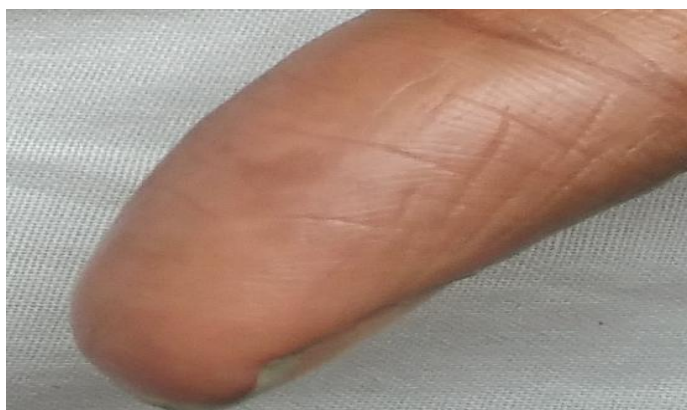

FIGURE 3: MAGNIFYING GLASS IMAGE OF THE LEFT THUMB OF A 21-YEAR OLD FEMALE WITH ADERMATOGLYPHIA.

DERMATOGLYPHICS IS NOT LIMITED TO FINGERPRINTS ALONE AS EPIDERMAL RIDGE PATTERNS CAN ALSO BE SEEN ON THE PALMS, TOES AND SOLES. PALMAR PRINT CONFIGURATIONS INCLUDE THENAR AREA, HYPOTHENAR AREA, INTERDIGITAL AREA, PALMAR CREASES, A-B RIDGE COUNT AND THE ATD ANGLE. IN ANALYZING FINGER AND PALMAR PRINTS, OTHER PATTERNS OF IMPORTANCE INCLUDE THE TOTAL FINGER RIDGE COUNT, THE ABSOLUTE RIDGE COUNT, THE POSITION OF THE AXIAL TRIRADII AND THE TOTAL NUMBER OF PALMAR TRIRADII[18]–[20] THESE PATTERNS ARE ALTERED IN VARIOUS GENETIC AND NON-GENETIC CONDITIONS.

5. IMPORTANCE OF FINGERPRINTS

FINGER PRINT CONFIGURATIONS ARE IMPORTANT DERMATOLOGICAL LANDMARKS WITH SUBSTANTIAL APPLICATIONS IN MEDICINE, FORENSICS, ANTHROPOLOGY, AND SECURITY[3], [4], [18], [21]. THE EPIDERMAL RIDGES USUALLY DEVELOP AROUND 10 TO 17 WEEKS POST-FERTILIZATION, AND THEIR FORMATION IS INFLUENCED BY GENETIC AND ENVIRONMENTAL COMPONENTS[3], [9], [22]. THESE PATTERNS WHEN FORMED ARE NOT ALTERED EXCEPT SKIN IS DAMAGED TO THE DEPTH OF 1MM.

THE EPIDERMAL RIDGES ARE IMPORTANT FOR GRASPING AND TO PREVENT SLIPPAGE. THIS EXPLAINS WHY AN INDIVIDUAL WITH ADERMATOGLYPHIA HAVE DIFFICULTIES WITH FINE Pincer GRASP.

DERMATOGLYPHIC ANALYSIS HAVE BEEN USED IN AIDING THE DIAGNOSIS OF SOME DISEASE CONDITIONS ESPECIALLY THOSE WITH STRONG HEREDITARY BASIS AND IS EMPLOYED AS A METHOD FOR SCREENING FOR ANOMALIES OR CHROMOSOMAL ABERRATIONS WHERE UNUSUAL PATTERNS HAVE BEEN SHOWN TO CORRELATE WITH SOME GENETIC DISORDERS . IT HAS ALSO BEEN USED IN CLINICAL CONDITIONS IN WHICH NEITHER A SINGLE GENE NOR A CHROMOSOMAL BASIS HAS BEEN DISCOVERED. DERMATOGLYPHICS IS AN IMPORTANT TOOL IN DIAGNOSING PHYSIOLOGICAL, MEDICAL, FORENSIC AND GENETIC CONDITIONS AND IS EMERGING AS A CLINICAL INSTRUMENT AND GENETIC TOOL OF SIGNIFICANCE.

THE UNIQUENESS OF FINGERPRINTS ARE ALSO IMPORTANT IN IDENTIFYING DEAD PATIENTS IN BLAST INJURIES, ACCIDENTAL EXCHANGE OF NEWBORN BABIES, IMPERSONATION AND PATERNITY ISSUES.

FINGERPRINT BIOMETRICS ARE USED FOR IDENTIFICATION DURING BANKING TRANSACTIONS, NATIONAL REGISTRATION, IMMIGRATION, FORENSICS, BUILDING AND DOOR ACCESS, PHONE ACCESS ETCETERA.

6. CONGENITAL AND ACQUIRED CAUSES OF ADERMATOGLYPHIA
ABSENCE OF FINGERPRINTS CAN BE CONGENITAL OR ACQUIRED[5]. THE CONGENITAL CAUSE INCLUDE THE ISOLATED CONGENITAL ADERMATOGLYPHIA AND ADERMATOGLYPHIA AS PART OF SYNDROMIC MANIFESTATION OF CONGENITAL DISEASES. THE ISOLATED CONGENITAL FORM IS SAID TO BE AN AUTOSOMAL DOMINANT CONDITION LINKED TO A MUTATION OF THE SMARCD1 GENE[4], [6], [23].

THESE CONGENITAL DISEASES MOSTLY DUE TO ECTODERMAL DYSPLASIAS INCLUDE BASAN SYNDROME, NAEGELI-FRANCESCHETTI-JADASSOHN SYNDROME , DERMATOPATHIA PIGMENTOSA RETICULARIS , RETICULATE ACROPIGMENTATION OF KITAMURA, ROTHMUND THOMAS SYNDROME[5], [7], [24], [25]

- **BASANS SYNDROME: AUTOSOMAL DOMINANT ECTODERMAL DYSPLASIA** CHARACTERIZED BY RAPIDLY HEALING CONGENITAL ACRAL BULLAE, CONGENITAL MILIA AND LACK OF FINGERPRINTS. OTHER FEATURES SEEN IN THIS CONDITION INCLUDE HYPOHIDROSIS, PALMOPLANTAR KERATODERMA, AND NAIL DYSTROPHY. A MUTATION IN THE SMARCD1 GENE WAS RECENTLY REPORTED TO CAUSE BASAN SYNDROME.

- **NAEGELI-FRANCESCHETTI-JADASSOHN SYNDROME: AUTOSOMAL DOMINANT FORM OF ECTODERMAL DYSPLASIA DUE TO KERATIN 14 MUTATION, CHARACTERIZED BY RETICULAR SKIN PIGMENTATION, DIMINISHED FUNCTION OF THE SWEAT GLANDS, ABSENCE OF TEETH, REDUCED PALMAR DEMOGLYPHICS AND HYPERKERATOSIS OF PALMS AND SOLE.**
- **DERMATOPATHIA PIGMENTOSA RETICULARIS: AUTOSOMAL DOMINANT ECTODERMAL DYSPLASIA CHARACTERIZED BY A TRIAD OF GENERALIZED RETICULATE HYPERPIGMENTATION, NON CICATRICAL ALOPECIA AND ONYCHODYSTROPHY. PATIENTS ALSO HAVE ADERMATOGLYPHIA, THIN BRITTLE NAILS AND LACK OF SWEAT GLANDS.THIS DISEASE IS DUE TO KERATIN 14 MUTATION.**
- **RETICULATE ACROPIGMENTATION OF KITAMURA: AUTOSOMAL DOMINANT DISORDER ASSOCIATED WITH MUTATIONS IN DISINTEGRIN AND ADAM 10 GENE. THIS CONDITION CONSISTS OF LINEAR PALMAR PITS AND PIGMENTED MACULES 1 TO 4 MM IN DIAMETER ON VOLAR AND DORSAL PART OF THE HANDS AND FEET.**
- **ROTHMUND THOMAS SYNDROME: THIS IS AN AUTOSOMAL RECESSIVE POIKILODERMA CHARACTERIZED BY SPARSE HAIR, EYE LASHES AND EYEBROWS, SLOW GROWTH SMALL STATUE, ABNORMAL TEETH, NAILS AND GI PROBLEMS IN INFANCY.**

**ACQUIRED CAUSES CAN BE GROUPED INTO DERMATOLOGICAL AND NON-
DERMATOLOGICAL CAUSES[5], [14], [26]**

DERMATOLOGICAL	NON- DERMATOLOGICAL
Allergic and irritant contact dermatitis Atopic dermatitis Dyshidrotic eczema Cutaneous LE Epidermolysisbullosa Pemphigus vulgaris Psoriasis KeratodermaBlennorrhagica Palmar warts, Leprosy Pyoderma/Impetigo Coxsackie A Tineamannum Erythema multiforme Steven Johnson Syndrome Toxic Epidermal Necrolysis Serum sickness Primary hyperhidrosis	Trauma Burns Amputations Caustic abrasions Denervation injuries Capecitabine Chemotherapy Topical Steroids Retapumulin Atovastatin

Lichen Acrodermatitis	
--------------------------	--

7. METHODS OF ANALYZING FINGERPRINTS
THERE ARE VARIOUS METHODS OF FINGER PRINTING. THESE INCLUDE

- **TRANSPARENT ADHESIVE TAPE METHOD: DRY COLOURING PIGMENTS LIKE CHALK, INK OR GRAPHITE ARE APPLIED ON HANDS.**
- **PHOTOGRAPHIC METHOD: POLAROID CAMERA IS USED TO CAPTURE THE MAGNIFIED IMAGE**
- **NUMERICAL METHOD: ALGORITHM OF SYNTHESIS OF IMAGES OF FINGERPRINTS IS USED TO CREATE ALL POSSIBLE ARRANGEMENTS OF RIDGES CALLED MINUTIAE.**
- **FAUROT INKLESS METHOD: COMMERCIALLY AVAILABLE PATENTED SOLUTION IS USED TO RECORD PRINTS ON SENSITIZED PAPER.**
- **BIOMETRICS METHOD: AUTOMATIC SEPARATE MACHINES FOR FINGER AND PALM SCAN THE HAND TO RECORD PRINTS.**
- **INKPAD METHOD: THE FINGERS ARE PRESSED ON THE STAMP PAD TURN BY TURN AND RECORDED ON PAPER.**



FIGURE 4: INKPAD PRINT OF DIFFERENT FINGERPRINT PATTERNS: LOOP, WHORL AND ARCH.




FIGURE 4: INKPAD RIGHT THUMB PRINT OF THE 21-YEAR-OLD FEMALE PATIENT WITH ADERMATOGLYPHIA. NOTE THE ABSENCE OF EPIDERMAL RIDGE CONFIGURATION.

8. CHALLENGES

DIAGNOSING ADERMATOGLYPHIA IN NIGERIA IS QUITE CHALLENGING. PATIENT USUALLY PRESENT WITH DIFFICULTY IN CAPTURING FINGERPRINT DURING BIOMETRICS, FURTHER EVALUATION TO ENABLE THE ATTENDING PHYSICIANS GET A SPECIFIC CAUSE IS HALTED BY LACK OF MOLECULAR GENETIC TESTING. THIS IS THE PRIMARY INVESTIGATION TO ASCERTAIN WHETHER THE PATIENT HAS SMARCAD 1 GENE AND KERATIN 14 MUTATION WHICH ARE THE MAJOR GENE MUTATIONS SEEN IN ADERMATOGLYPHIA[8], [24]. THESE INVESTIGATIONS ARE NOT READILY AVAILABLE AND AS SUCH POSES A GRAVE SETBACK AT ARRIVING AT A DEFINITIVE DIAGNOSIS. OTHER INVESTIGATIVE MODALITIES LIKE VOLAR PAD BIOPSY ARE USUALLY DECLINED BY PATIENTS AS THEY SEE THE ABSENCE OF FINGER PRINTS AS A VARIANT OF NORMAL AND WILL RESIST ATTEMPTS FOR INVASIVE PROCEDURES. ANOTHER CHALLENGE IS TRACING OF FAMILY MEMBERS TO ASCERTAIN WHETHER THEY ALSO HAVE ADERMATOGLYPHIA.

PAUCITY OF DATA ON ADERMATOGLYPHIA IS ALSO AN ISSUE AS MOST PATIENTS WITH THE CONDITION DO NOT PRESENT TO A HEALTH CARE FACILITY EXCEPT WHEN IN NEED OF A MEDICAL REPORT. PATIENTS ARE USUALLY SEEN DURING BIOMETRICS IN THE BANKS, BORDERS OR IMMIGRATION OFFICES AND ACCESS TO THESE DATA ARE MET WITH SOME BUREAUCRACIES. THE PSYCHOSOCIAL IMPACT PATIENTS WITH ADERMATOGLYPHIA FACE DURING BIOMETRIC SCREENING IS ALSO ENOUGH TRAUMA TO MAKE THEM AVOID FURTHER ANALYSIS.

A MAJOR SETBACK WITH THE ACQUIRED FORMS OF ADERMATOGLYPHIA IS THE FACT THAT THE PATIENTS COME TO CLINIC WITH OTHER DERMATOLOGICAL AND NON-DERMATOLOGICAL COMPLAINTS AND PAY LITTLE OR NO ATTENTION TO THE

ABSENCE OF FINGERPRINTS AS IT IS NOT A PRIMARY CHALLENGE. THIS MAKES THE ATTENDING PHYSICIAN MISS OUT ON ACQUIRED CAUSES IN THE HOSPITALS.

9. PROSPECTS

ADVANCING TECHNOLOGY HAS MADE BIOMETRIC ANALYSIS OF INDIVIDUALS A COMMON TREND. DERMOLYPHICS IS A COMMONLY UTILIZED METHOD FOR DATA COLLECTION, BIOMETRIC ASSESSMENT AND VERIFICATION. IT CAN BE DEPLOYED FOR USE FOR A LARGE NUMBER OF INDIVIDUALS AS IT IS LESS COMPLEX COMPARED TO OTHER MODALITIES. IN PATIENTS WITH ADERMATOGLYPHIA, ALTERNATIVE BIOMETRIC MODALITIES SHOULD BE IN PLACE AS OPTIONS FOR VERIFICATION.

THESE ADVANCED DETECTION MODALITIES PLAY AN IMPORTANT ROLE IN APPLICATIONS LIKE VIDEO SURVEILLANCE, BORDER CONTROL, TO IDENTIFY SHOPLIFTERS IN STORES, CRIMINALS AND TERRORISTS IN URBAN AREAS, ELIMINATING VOTER FRAUD, COMPUTER SECURITY ETCETERA.

THE NIGERIAN IMMIGRATION SERVICE USE PHOTOGRAPHIC IMAGE OF THE FACE AND PALM PLUS FINGERS WITH A VALID DOCTORS' REPORT AS A MEANS OF IDENTIFYING INDIVIDUALS WITH ADERMATOGLYPHIA.

BACK UP BIOMETRIC METHODS SHOULD BE UNIQUE, READILY AVAILABLE, GENERALLY ACCEPTABLE, UNIVERSALLY PRESENT, WITH UNCHANGING AND QUANTIFIABLE RESULTS THROUGHOUT THE LIFESPAN OF THE INDIVIDUAL[21], [27], [28]. THESE CHARACTERISTICS MAKE IT DIFFICULT TO CHOOSE A PARTICULAR ALTERNATIVE. AVAILABLE BIOMETRIC METHODS THAT CAN BE USED AS BACK UP FOR PATIENTS WITH ADERMATOGLYPHIA INCLUDE PHYSIOLOGICAL SUBTYPES (FACE RECOGNITION, PALM PRINT, HAND GEOMETRY, IRIS AND RETINAL SCAN), AND BEHAVIORAL SUBTYPES (SIGNATURES, KEYSTROKE, AND VOICE AND GAIT PATTERNS)[5], [21], [28]–[30].

FACE RECOGNITION USES A SYSTEM WHERE COMPUTER APPLICATION AUTOMATICALLY IDENTIFIES A PERSON FROM A DIGITAL IMAGE OR A VIDEO SOURCE WITHOUT CONTACT OR TOUCHING. IT IDENTIFIES SUBJECTS BASED ON THEIR FACIAL CHARACTERISTICS LIKE DISTANCE BETWEEN CHEEKBONES AND EYE SOCKET POSITION[28], [31].

PALM PRINT RECOGNITION AND HAND GEOMETRY: PALMPRINTRECOGNITION INVOLVES IDENTIFYING INDIVIDUALS BASED ON LINES AND CREASES ON THE PALM OF THE HAND, THE AGGREGATE OF INFORMATION PRESENTED IN A FRICTION RIDGE IMPRESSION AND THEN EXTRACT THE MINUTE DETAIL[28]–[30]. HAND GEOMETRY UTILIZES MORE THAN 90 DIMENSIONAL MEASUREMENTS TO RECORD AN ACCURATE SPATIAL REPRESENTATION OF THE HAND OF A PERSON[28].

IRIS AND RETINAL SCAN: RETINAL SCANNING IS ELECTRONIC SCANNING OF THE RETINA, THE INNERMOST LAYER OF THE WALL OF THE EYEBAL WHILE IRIS

SCANNING UTILIZES A CAMERA MOUNTED SOMEWHERE BETWEEN THREE AND TEN FEET AWAY FROM AN INDIVIDUAL TO SNAP A HIGH DEFINITION PHOTOGRAPH OF EYES OF THE PERSON. IT THEN INTERPRETS >200 DIFFERENT POINTS[21], [28], [30].

ELECTRONIC SIGNATURE AND KEYSTROKE DYNAMICS: ELECTRONIC SIGNATURE MAKES A TRACE ON AN ELECTRONIC SCREEN OR DEVICE WHICH HAS SOFTWARE THAT ASSOCIATES A SERIES OF BIOMETRIC DATA (PRESSURE, STROKES, THE SPEED OF WRITING, ETC.) TO THE IDENTITY OF THE SIGNER WHILE KEYSTROKE DYNAMICS TECHNOLOGY RECORDS DWELL TIME (WHICH IS THE LENGTH OF TIME A PERSON HOLDS DOWN EACH KEY) AS WELL AS FLIGHT TIME (WHICH IS THE TIME IT TAKES TO MOVE BETWEEN KEYS)[21], [28], [30]..

OTHER HIGH-TECH BIOMETRIC PARAMETERS THAT HAVE BEEN STUDIED INCLUDE FINGER VEIN PATTERN, TONGUE PRINTING, ELECTROCARDIOGRAPHY AND RADIO-FREQUENCY IDENTIFICATION TECHNOLOGY[21], [30].

10. CONCLUSION

MORE CASES OF ADERMATOGLYPHIA ARE BEING SEEN BECAUSE OF INCREASED NEED FOR INDIVIDUAL IDENTIFICATION AND AUTHENTICATION USING BIOMETRIC METHODS IN COUNTRIES AROUND THE WORLD AND NIGERIA IN PARTICULAR. THE PSYCHOSOCIAL IMPACT OF THIS CONDITION CAN NOT BE OVEREMPHASIZED. WITH ADVANCING TECHNOLOGY, OTHER BIOMETRIC MODALITIES SHOULD BE MADE READILY AVAILABLE, UNIVERSALLY ACCEPTABLE AND EASILY REPRODUCED WHEN THE INDIVIDUAL IS CALLED UPON. THESE STANDADIZED ALTERNATIVE MODALITIES OF IDENTIFICATION SHOULD BE IN PLACE IN CASES WHERE FINGERPRINTING IS AN ISSUE.

REFERENCES

- [1] J. R. Miller, "Dermatoglyphics," *J. Invest. Dermatol.*, 1973.
- [2] J. Verbov, "Clinical significance and genetics of epidermal ridges--a review of dermatoglyphics.," *The Journal of investigative dermatology*, vol. 54, no. 4. pp. 261–271, 1970.
- [3] P. K. Bose and M. J. Kabir, "Fingerprint: A Unique and Reliable Method for Identification," *J. Enam Med. Coll.*, 2017.
- [4] T. Kanchan and K. Krishan, "Loss of fingerprints: forensic implications," *Egyptian Journal of Forensic Sciences*. 2018.
- [5] N. Sarfraz, "Adermatoglyphia: Barriers to Biometric Identification and the Need for a Standardized Alternative," *Cureus*, 2019.
- [6] O. Dereure, "Adermatoglyphia or 'immigration delay disease': The role of mutations in the SMARCAD1 gene," *Ann. Dermatol. Venereol.*, 2012.
- [7] "Adermatoglyphia," *Genetic Home Reference*, 2020. [Online]. Available: <https://ghr.nlm.nih.gov/condition/adermatoglyphia>. [Accessed: 25-May-2020].
- [8] B. Burger, D. Fuchs, E. Sprecher, and P. Itin, "The immigration delay disease: Adermatoglyphia-inherited absence of epidermal ridges," *Journal of the American Academy of Dermatology*. 2011.
- [9] D. T. Meva, C. K. Kumbharana, and A. D. Kothari, "The Study of Adoption of Neural Network Approach in Fingerprint Recognition," *Int. J. Comput. Appl.*, vol. 40, no. 11, pp. 8–11, Dec. 2012.
- [10] Faulds Henry, "On the Skin-Furrows of the Hand," *Nat. Res. J.*, vol. 22, p. 605, 1880.
- [11] S. M. Stigler, "Galton and identification by fingerprints," *Genetics*. 1995.
- [12] Baird Henry W, "Absence of fingerprints in four generations," *Lancet*, vol. 292, no. 7580, p. 1250, 1968.
- [13] Onyemocho A, Omala E, Onum E, and Anigilaje E, "Adermatoglyphia; A cause of serious delay in issuance of Immigration e-passport to a christian pilgrim in Nigeria: A case report," *Int. J. Adv. case reports*, vol. 2, no. 12, pp. 732–735, 2015.
- [14] Haber Roger, Helou Josaine, Korkomaz Joelle, Habre Maya, Ghanem Antoine, and Tomb Roland, "Absence of fingertips with focus on dermatological etiologies: National survey and review," *J. Clin. Dermatology*, vol. 3, no. 1, pp. 21–26, 2015.
- [15] Jim Mitchell, "What happens when you're born without fingerprints? What happens when you're born without fingerprints?," *Special Broadcasting Service*, 2017. [Online]. Available: <https://www.sbs.com.au/guide/article/2017/12/04/what-happens-when-youre-born-without-fingerprints>. [Accessed: 25-May-2020].
- [16] Kaur Jeewandeep and Bantra Arvinder Pal Singh, "Role of Dermatoglyphics in Medical Disorders," *ndian J. Fundam. Appl. Life Sci.*, vol. 3, no. 3, pp. 536–539, 2013.
- [17] G. Bhat, M. Mukhdoomi, B. Shah, and M. Ittoo, "Dermatoglyphics: in health and disease - a review," *Int. J. Res. Med. Sci.*, 2014.

- [18] G. Jain, "" Dermatoglyphics " - The Science of Lines and Patterns and Its Implications in Dentistry," *Int. J. Contemp. Med. Res.*, 2016.
- [19] Newman H H, "Finger prints, palms and soles: An introduction to dermatoglyphics. By Harold Cummins and Charles Midlo," *Am. J. Phys. Anthropol.*, vol. 2, no. 2, pp. 227–229, 1944.
- [20] B. W. Richards, "Dermatoglyphics in Medical Disorders," *J. Med. Genet.*, 1978.
- [21] A. K. Jain and A. Kumar, "Biometric Recognition: An Overview," 2012, pp. 49–79.
- [22] L. Entrance, S. N. Srihari, and H. Srinivasan, "Individuality of Fingerprints : Comparison of Models and Measurements," *New York*, 2007.
- [23] J. Noursbeck *et al.*, "A mutation in a skin-specific isoform of SMARCAD1 causes autosomal-dominant adermatoglyphia," *Am. J. Hum. Genet.*, 2011.
- [24] J. Noursbeck *et al.*, "A mutation in a skin-specific isoform of SMARCAD1 causes autosomal-dominant adermatoglyphia," *Am. J. Hum. Genet.*, vol. 89, no. 2, pp. 302–307, Aug. 2011.
- [25] Sybert Virginia P, *Genetic skin disorders*, 3rd ed. Oxford university press, 2017.
- [26] C. Mazza *et al.*, "Capecitabine and adermatoglyphia: trouble in border!," *Journal of the European Academy of Dermatology and Venereology*. 2017.
- [27] L. Entrance, S. N. Srihari, and H. Srinivasan, "Individuality of Fingerprints : Comparison of Models and Measurements," *New York*, no. June, 2007.
- [28] Omoyiola Bayo Olushola, "Overview of Biometric and Facial Recognition Techniques," *IOSR J. Comput. Eng.*, vol. 20, no. 4, pp. 1–5, 2018.
- [29] Sharma Vivek kr and Vasudeva Nisha, "A Review on Palm Print Recognition Techniques," *Int. J. Adv. Res. Comput. Sci. Softw. Eng.*, vol. 7, no. 3, 2017.
- [30] N. V. Boulgouris, K. N. Plataniotis, and E. Micheli-Tzanakou, *Biometrics: Theory, Methods, and Applications*. John Wiley and Sons, 2009.
- [31] Subban Ravi and Mankame Dattatreya P, "Human Face Recognition Biometric Techniques: Analysis and Review," in *Recent advances in intelligent informatics*, M. Thampi S, Ed. Switzerland: Springer International Publishing Switzerland , 2014, pp. 455–463.