

Case report

A rare case of recurrent breast malignant Phyllodes Tumor with lung ,axillary and mediastinal lymph nodes metastasis

ABSTRACT

Background: Phyllodes tumour (PT) is very rare fibroepithelial tumor of the breast and **divided** based on the World Health Organization into benign, borderline, and malignant subtypes. The most common type of phyllodes tumor is benign ,however malignant phyllodes tumors have important clinical implications, as they are more likely to **recur locally and potentially metastasize**. The most common sites of distant metastasis include the lung, bone, and liver.

Case presentation: A 34 year-old female presented with right nipple blood discharge with palpable right breast lump. Tru cut biopsy showed Atypical Cell and subsequently she underwent right wide local excision and histopathological examination showed malignant phyllodes tumor. She then presented again with recurrent ulcerated right breast lump. Repeated tru cut biopsy showed atypical cell for which she underwent simple mastectomy with final diagnosis of malignant phyllodes tumor. Two weeks after surgery, she presented with right axillary mass with anterior right chest wall mass. Further evaluation demonstrated that masses over right axillary, right anterior mediastinal and bilateral lung suggestive of metastasis.

Conclusion: We presented a rare case of aggressive malignant phyllodes tumor with recurrent and distant metastasis to bilateral lungs, axillary and mediastinal lymph nodes.

Keywords: Malignant phyllodes tumor, fibroepithelial neoplasm, wide local excision, mastectomy axillary clearance

INTRODUCTION

Phyllodes tumors are rare fibroepithelial neoplasms of the breast, **the occurrence is less than 1% all breast neoplasms**[1]. They are classified by WHO into benign, borderline and malignant variants based on stromal cellularity, cellular atypia and pleomorphism, mitotic index, stromal overgrowth, tumor margin, and the presence or absence of heterologous differentiation [2]. Triple assessment by clinical, radiological and histological examination are the initial assessment to evaluate PTs .

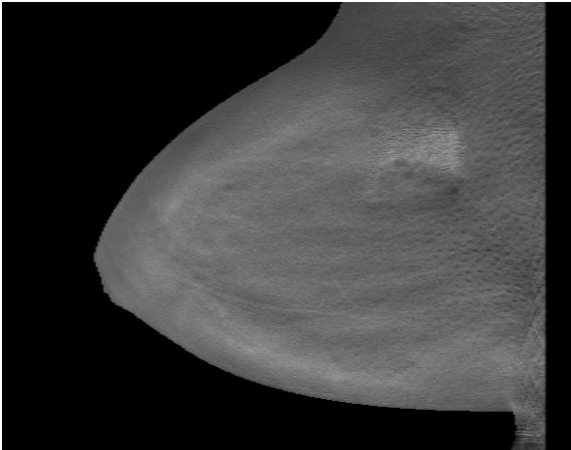
The current approach is **to prevent local relapse** and metastasis is by surgical resection with wide margins [3]. However, even with **adequate surgical resection**, the local recurrence rate remains as high as 8 to 36% for malignant phyllodes type [3]. Furthermore, recurrent phyllodes tumors can progress toward more malignant phenotypes, in which metastases have been estimated to occur up to 25% of patients .

The most common sites of metastases are the lungs and **bone ,however metastasize to axillary and mediastinal lymph nodes are very rare** [4]. Role of radiotherapy is still controversial ,however there is study showed that radiotherapy could prolong the time to local recurrence and decrease the local recurrence rate, with no significant influence on survival [3].Radiotherapy also may be effective in the prevention of metastasis .

CASE REPORT

34 years old Malay lady, no known medical illness ,presented to us with complaint of right nipple blood discharge for 2 days duration associated with pain .She also has right breast lump past 1 year duration , about 4x4 cm in size ,gradually increase in size. Otherwise she denied any abdominal pain, shortness of breath , bony pain and jaundice symptoms .**She attained her menarche** at 11 years old ,she is married ,blessed with 1 child and she breast fed her child up 2 years old. Otherwise she has no family history of malignancy and she is not on oral contraceptive pill or hormone replacement therapy .On examination ,she is alert pink not jaundice, not tachypneic, lung and abdominal examination are unremarkable . Right breast examination showed palpable lump at right upper outer quadrant , size about 5x4cm, regular and smooth surface with minimal tenderness ,no skin changes **and associated with bloody nipple discharge** .Otherwise contralateral left breast **is normal finding** . **There is no axillary lymph node palpable bilaterally**. Ultrasonography(USG) of the breast and Mammogram(MMG) done showed highly suspicious of right breast mass at 12 hour location, BIRADS 4C. Tru cut biopsy of right breast done and microscopically showed scatted

1(a)



1(b)

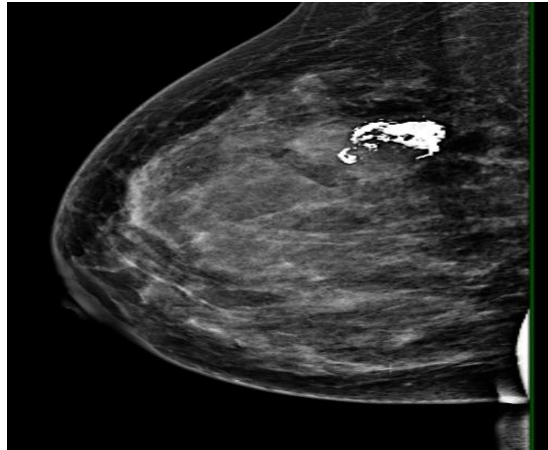
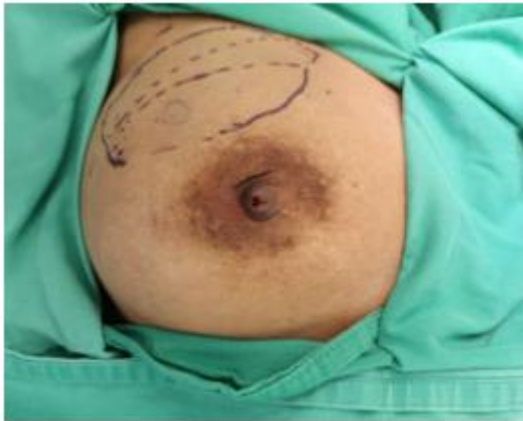


Figure 1: Images of 1 a) Digital breast tomosynthesis and 1b) Mammogram MLO view showed high density indistinct margin mass seen in middle upper quadrant of right breast with coarse calcification within.

This patient then underwent right breast wide local excision (WLE). Intraoperative finding noted breast lump palpable:5cmx 4cm at right upper quadrant of breast.

Intraoperative Finding:

2a)



2b)

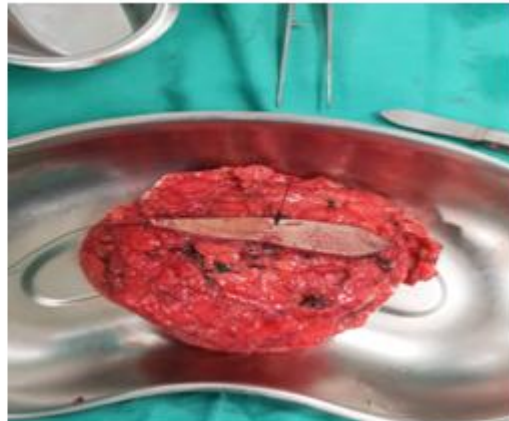

Figure 2: 2a) Marking of right breast WLE and 2b) is Wide local excision of breast specimen

Histopathological examination (HPE) of wide local excision showed malignant phyllodes tumour with malignant heterologous component with positive margin. **The Immunohistochemistry (IHC) performed and showed the malignant cells are Positive to Vimentin and CD 10, however there are negative for CKAE1/AE3, CK5/6, CK 7, p63, CD 34 , CD117 and BCL 2. The ER and PR and HER2 are also Negative .** Initial evaluation of CT thorax abdomen and pelvis showed no evidence of distance metastasis. She was planned for right simple mastectomy however she opted for radiotherapy to right chest wall and tumour bed .However she defaulted for follow up for initiation

of radiotherapy. Patient then presented again with recurrent of right breast lump and pain with ulceration of breast lump for 1 month duration 4 months after the surgery. On examination noted right breast lump at upper quadrant of breast 8cm x10 cm ,hard with ulcerated over the overlying skin. Otherwise no axillary lymph node palpable .Tru cut biopsy of the breast done and revealed atypical cells . Positron Emission Tomography (PET) Scan evaluation done and showed FDG avid primary malignancy in the right breast with possible local infiltration to the chest wall with no evidence of distant metastasis. She was proceeded with simple mastectomy .

HPE of simple mastectomy showed Malignant Phyllodes tumour which the tumour infiltrates into the skeletal muscle tissue with vascular invasion is present. Post operatively, patient was discharge well. Unfortunately patient presented again with right axillary mass and right anterior chest wall mass after 2 weeks of simple mastectomy surgery. On examination revealed multiple huge matted fixed right axillary lymph node with right anterior chest wall mass .Other examinations were unremarkable.

Histopathological Examination (HPE) of post right mastectomy specimen

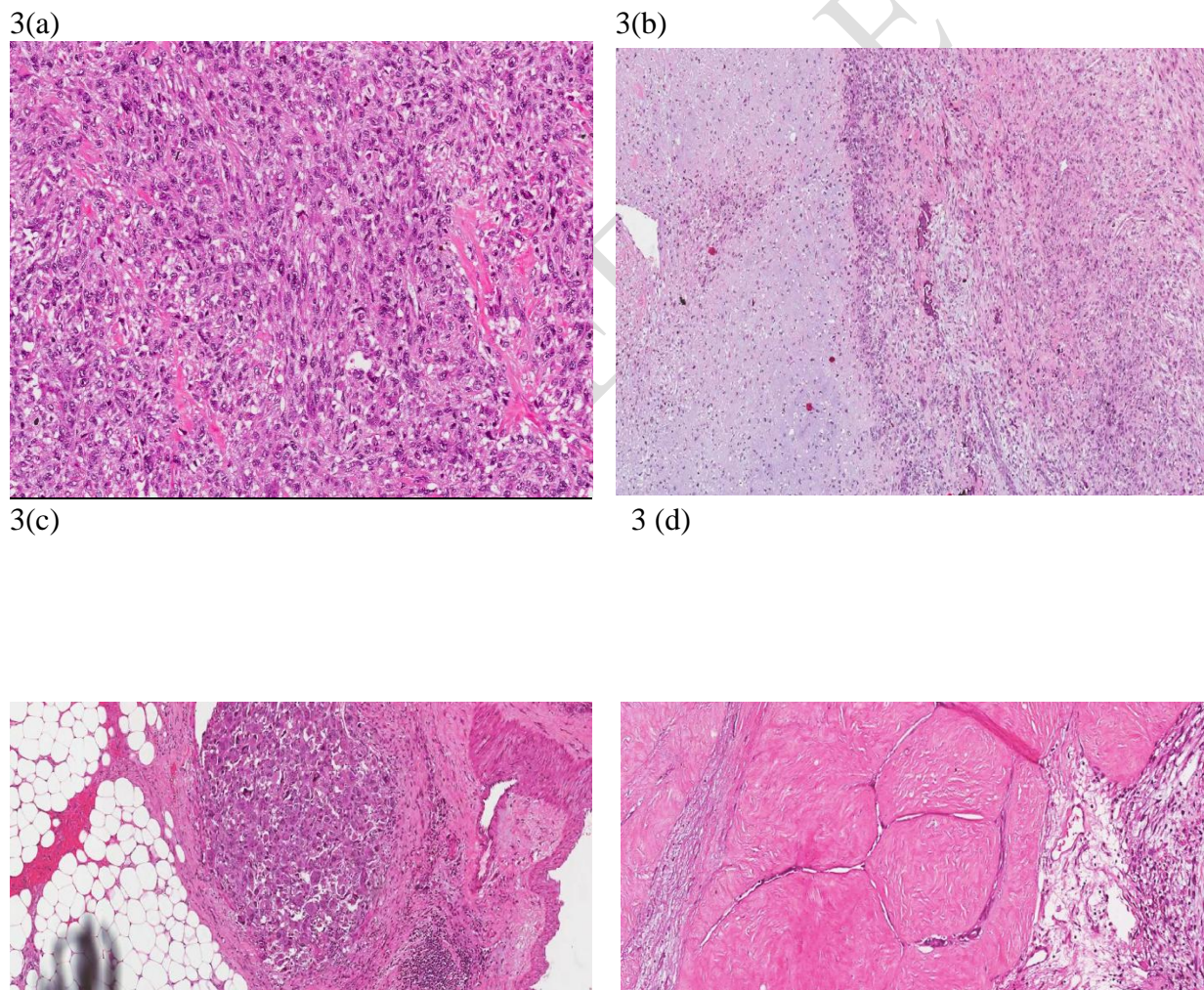
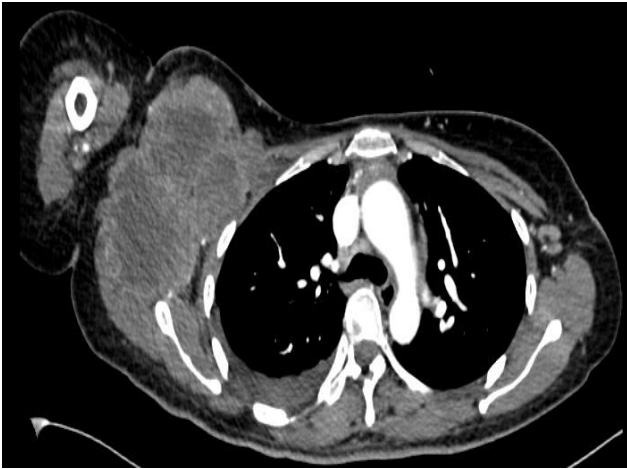

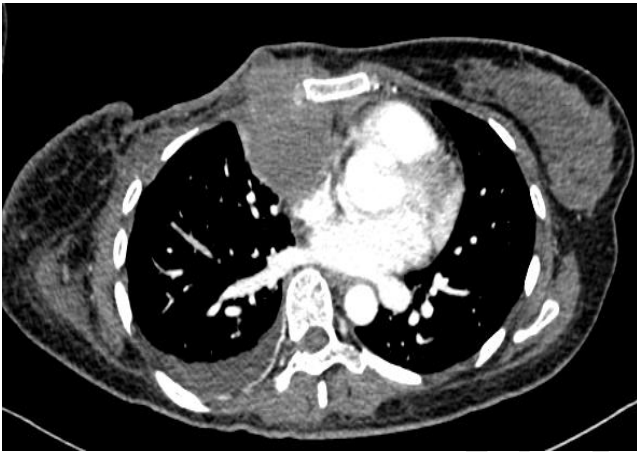
Figure 3 : Haematoxylin and Eosin (H&E) stain showing : 3(a) The tumour is composed of hypercellular pleomorphic spindle-shaped cells with areas of malignant heterologous differentiation (400x); 3(b) chondrosarcomatous (left) and osteosarcomatous (right) differentiations (200x). 3(c)

Lymphovascular invasion is present (400x). 3 (d) Remnant of left-like stromal fronds lined by benign epithelial cells are observed at the periphery of the tumour.

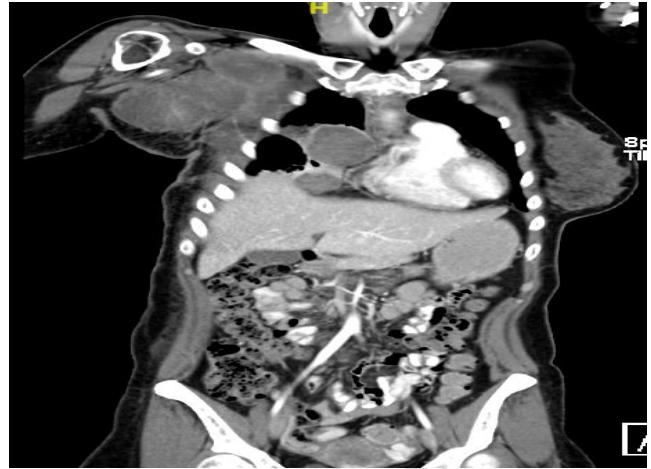4(a)



4(c)



4(b)



4 (d)

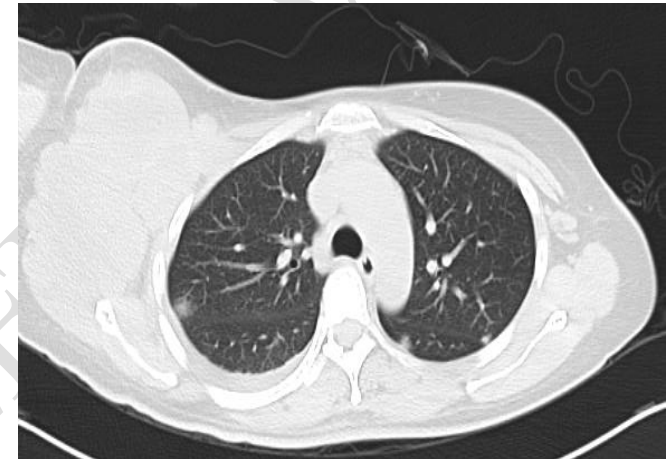


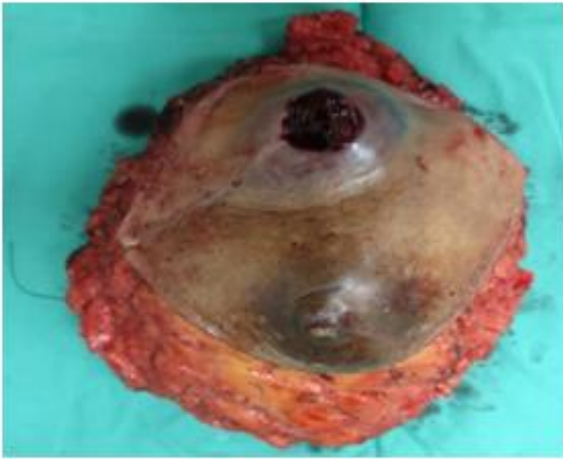
Figure 4: CT Scan showed (4a) axial view and (4b) coronal view of Right lobulated matted mass over axillary and right lateral chest wall suggestive of lymph nodes metastasis. 4(c) Right Anterior mediastinal mass suggestive of lymph nodes metastasis 4(d) Bilateral lung nodules suggestive of metastasis

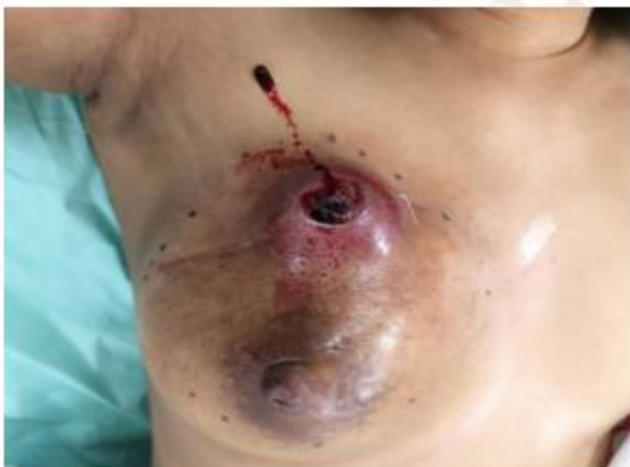

Figure 5: Pre-operative picture of recurrent right breast mass with ulcerated and fungated mass of breast.

Post Simple Mastectomy specimen

6a)



6b)

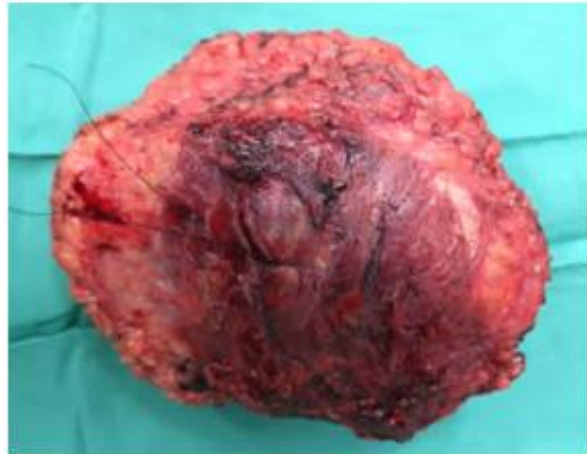

Figure 6: 6a) Anterior superior and inferior view and 6b) Deep margin view

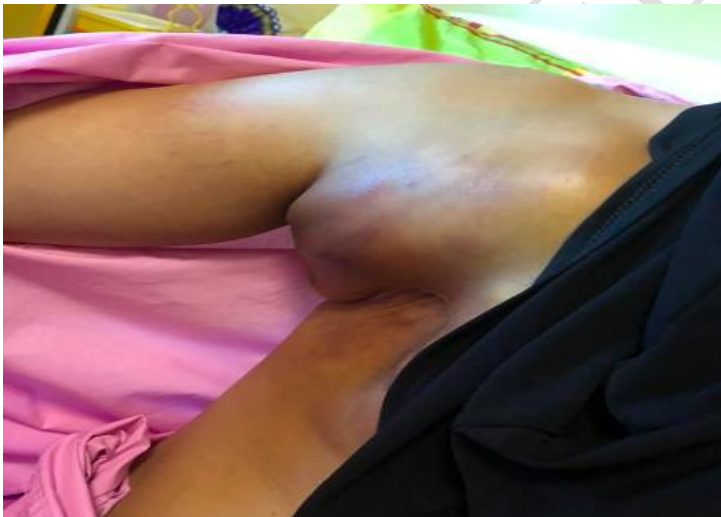

Figure 7: Huge Matted right axillary lymph node metastasizes with anterior chest wall mass

Blood investigations were within normal range. Contrast CT scan of neck, thorax and abdomen for re-staging done and showed huge lobulated matted mass over right axillary region ,right lateral chest wall mass ,right anterior mediastinal mass likely represent matted lymph nodes and bilateral lung metastasize.

Patient then was referred to oncology team for radiotherapy. She completed her radiotherapy treatment to right anterior chest wall , right axillary and anterior right mediastinum. She was discharge well after radiotherapy. Unfortunately she presented again with symptom of shortness of breath .She was diagnosed with respiratory failure secondary to COVID-19 disease. She succumbed death 2 weeks after completion of radiotherapy.

DISCUSSION

Phyllodes Tumor (PT) is a rare fibroepithelial neoplasms of the breast. PT account about less than 1% of all breast neoplasm . PT is fibroepithelial neoplasm mostly originate from the stroma in the terminal ducto-lobular unit in which includes both epithelial and cellular stromal component[5]. PT is spectrum of disease. The World Health Organization (WHO) classifies phyllodes tumour into three histologic subtypes which are benign about 70%-80% of cases, borderline about 20—25% cases and malignant about 5 – 10 % cases [6]. There are differentiated from benign to malignant types base on stromal cellularity, stromal cell mitotic activity, stromal nuclear atypia, stromal overgrowth and type of borders either infiltrating or pushing type. Clinical presentation of PT is typically large and rapidly growing tumor associated with dilated veins and blue discoloration .The median size of PT is 4cm and about 20% of PT might grow up to 10 cm large .PT commonly found in upper outer quadrant of breast . Patient might have background history of fibroadenoma. PT patient rarely present with nipple retraction and ulceration. There is about 10-15% of palpable axillary lymph node at initial presentation. In our case, she presented with bloody nipple discharge over affected breast which is very rare presentation. She also presented again with large and fast growing ulcerated breast mass in which typical presentation for PT. In order to investigate any breast lesion ,an ultrasonography (USG) or mammogram are gold standard for aid the diagnosis . Findings that suggestive of PT base on USG are lobulated shape with smooth margin ,low level of homogenous internal echoes and solid mass .Malignant features are includes posterior shadow or ill-defined margin with marked hypoechoic .In addition, mammogram commonly showed lobulated mass with rounded border with radiolucent halo and coarse calcification .In our case, the imaging findings are inconclusive of PT. Role of tissue diagnosis in PT either fine needle aspiration cytology (FNAC) or core biopsy. The FNAC is difficult to differentiate between fibroadenoma and phyllodes tumor because both are fibroepithelial .FNAC often inadequate for clear and differential diagnosis of PT[5]. However to differentiation malignant and benign ,the accuracy is about 63% by doing core biopsy. Apart from that, core biopsy provide extra architectural information and showed 99% sensitivity .In our case, even though we are performing core biopsy , the HPE came back as Atypical cells and still unable to rule out phyllodes tumor.

Histologically PT can be differentiated base on stromal hypercellularity, numbers of cellular pleomorphism, numbers of mitosis ,margin type and stromal pattern [7] [8]. Table 1 showed pathological

diagnosis and grading criteria of phyllodes tumor base on WHO classification:

	BENIGN	BORDERLINE	MALIGNANT
TUMOR BORDER	Well-defined	Well-defined, may be focally infiltrative	Infiltrative
STROMAL CELLULARITY	Mild, non-uniform or diffuse	Moderate, non-uniform or diffuse	Marked, usually diffuse
STROMAL ATYPIA	None or mild	Mild or moderate	Marked
MITOTIC ACTIVITY	<5 per 10 HPF	5-9 per 10 HPF	≥10 per 10 HPF
STROMAL OVERGROWTH	Absent	Absent or focal	Often present
MALIGNANT HETEROLOGOUS ELEMENTS	Absent	Absent	May be present

Table 1 showed pathological diagnosis and grading criteria of phyllodes tumor:

In our patient, after completed wide local excision and simple mastectomy , HPE are suggestive of malignant Phyllodes tumor with vascular invasion with positive surgical margin.

For the treatment of phyllodes tumors, the National Comprehensive Cancer Network (NCCN) guidelines recommend wide surgical excision with one centimeter margins, without axillary lymph node dissection [2].Figure 8 showed management algorithm of Phyllodes Tumor suggested by NCCN Guidelines[5][9].

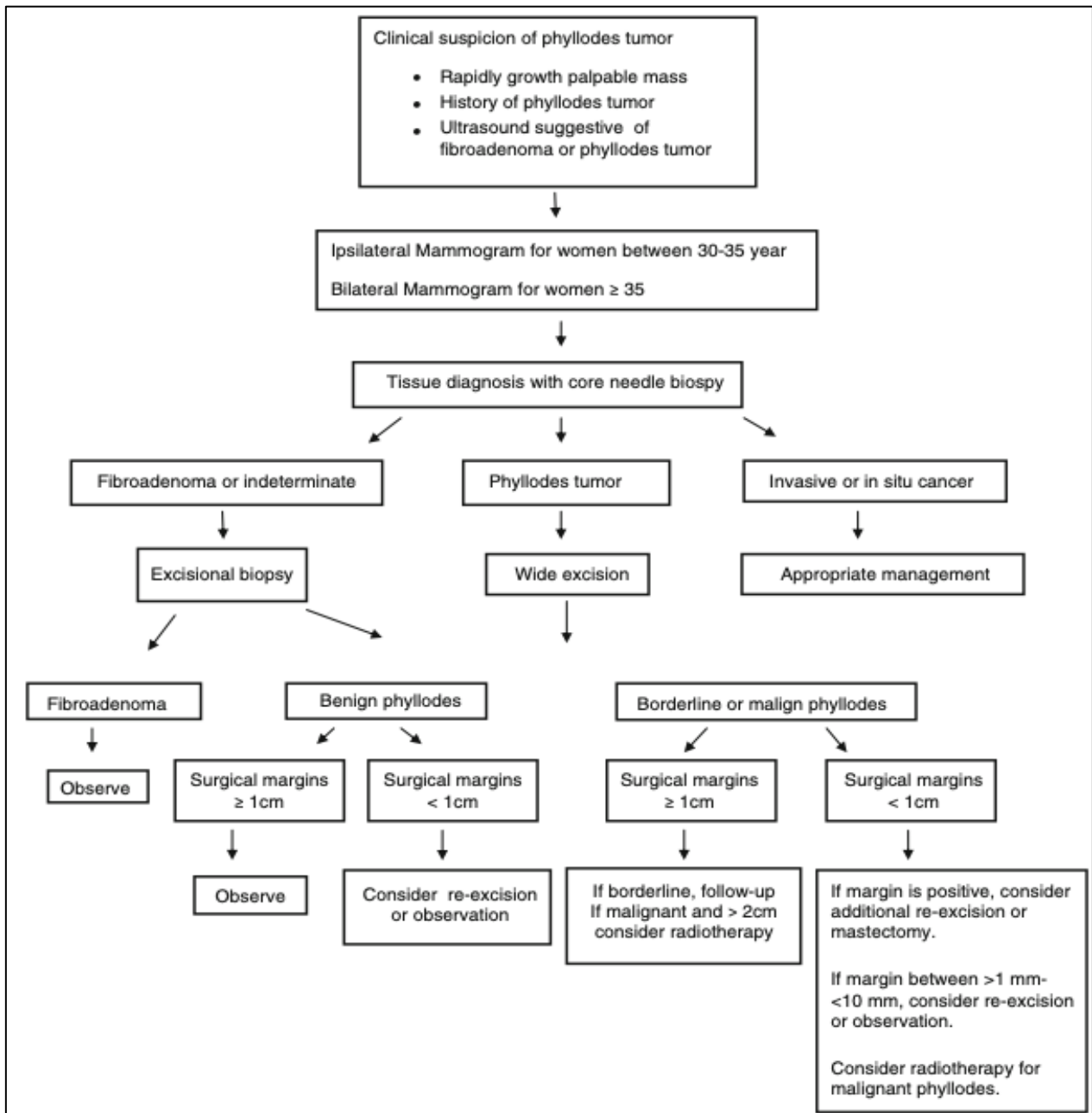


Figure 8:Management algorithm of Phyllodes Tumor

The current approach to preventing local relapse and metastasis is surgical resection with wide margins [10] [11]. However, even with wide surgical resection, the local recurrence rate remains as high as 8 to 36% . Recurrent PT can progress toward malignant phenotypes [12] .Metastases have been estimated to occur in up to 25% of patients[3].In our case, after first surgery of wide local excision, we advise for re-excision or mastectomy, however she opted for radiotherapy ,but she is defaulted radiotherapy. unfortunately she presented again within 4 months duration with recurrent of PT and underwent simple mastectomy surgery. HPE of simple mastectomy showed malignant

phyllodes tumor with positive margin .As suggested by NCCN guidelines, radiotherapy is considered and she completed a courses of radiotherapy treatment.

Distant metastasis occurred in 25% of malignant phyllodes .Most distant metastasis can be without local recurrence .The commonest sites are lungs about 66% followed by bones about 28% and brain about 9% [6]. The risk of metastatic influenced by tumor biology. Metastatic phyllodes tumors have a poor prognosis and no long-term survival. The duration of metastasis after surgery is 7 months to 6 years in literature[6] . However in our case, this patient came with recurrent of malignant phyllodes tumor with metastasis to right axillary lymph nodes region, right anterior chest wall, right anterior mediastinum lymph nodes and bilateral lungs within 4 months post-surgery.

Role of adjuvant Radiotherapy (RT) and Chemotherapy

Role of RT is controversial because of inadequate data from large prospective studies. This is due to low incidence of PTs and the limited utilization of adjuvant therapy. NCCN Guidelines recommended that adjuvant radiotherapy should be given in all malignant phyllodes tumor patient as RT could extend the time to local recurrence and decrease the local recurrence rate, with no significant influence on survival[3] . RT may be effective in the prevention of metastasis . In view of lack of clinical evidence ,chemotherapy is not recommended as a first-line treatment in patient with malignant phyllodes tumor.

CONCLUSION

Malignant spectrum of phyllodes tumor is very rare and metastasis is rarely occurred in all type of phyllodes tumors. Although the lungs and bones are the most common sites of metastasis, there can be simultaneous metastases to axillary lymph nodes and mediastinal lymph nodes like in our case. Contrast enhanced CT of neck, thorax and abdomen should be routinely done in malignant phyllodes tumors to look for metastasis. We concluded that for those PTs with high malignancy, radiotherapy should be recommended as adjuvant therapy without consideration of the surgery type as the risk of local recurrence and the possibility of distant metastasis is significantly increased.

REFERENCES

- [1] A. A. Shafi, B. AlHarthi, M. M. Riaz, and A. AlBagir, "Gaint phyllodes tumour with axillary & interpectoral lymph node metastasis; A rare presentation," *International Journal of Surgery Case Reports*, vol. 66, pp. 350–355, Jan. 2020, doi: 10.1016/j.ijscr.2019.12.026.
- [2] P. Pourghaderi, S. E. Chapin, A. M. Nouri, and Z. M Bamboat, "A rare case of recurrent phyllodes tumor of bilateral breasts with metastasis to the retroperitoneum and duodenum," *Medical Case reports and Reviews*, vol. 3, no. 1, 2020, doi: 10.15761/mcrr.1000138.
- [3] X. Chao *et al.*, "Adjuvant radiotherapy and chemotherapy for patients with breast phyllodes tumors: A systematic review and meta-analysis," *BMC Cancer*, vol. 19, no. 1. BioMed Central Ltd., Apr. 23, 2019. doi: 10.1186/s12885-019-5585-5.
- [4] R. Krishnamoorthy, T. Savasere, V. K. Prabhuswamy, R. Babu, and S. Shivaswamy, "Giant Malignant Phyllodes Tumour of Breast," *Case Reports in Oncological Medicine*, vol. 2014, pp. 1–5, 2014, doi: 10.1155/2014/956856.
- [5] F. Aydoğan, Y. Tasçi, and Y. Sagara, "Phyllodes tumors of the breast," in *Breast Disease: Management and Therapies*, Springer International Publishing, 2016, pp. 421–427. doi: 10.1007/978-3-319-26012-9_26.
- [6] S. Khanal, Y. P. Singh, A. Bhandari, and R. Sharma, "Malignant phyllodes tumor with metastases to lung, adrenal and brain: A rare case report," *Annals of Medicine and Surgery*, vol. 36, pp. 113–117, Dec. 2018, doi: 10.1016/j.amsu.2018.10.030.
- [7] C. Ditsatham and W. Chongruksut, "Phyllodes tumor of the breast: Diagnosis, management and outcome during a 10-year experience," *Cancer Management and Research*, vol. 11, pp. 7805–7811, 2019, doi: 10.2147/CMAR.S215039.
- [8] R. Fernández-Ferreira, A. Arroyave-Ramírez, D. Motola-Kuba, G. Alvarado-Luna, I. MacKinney-Novelo, and R. Segura-Rivera, "Giant Benign Mammary Phyllodes Tumor: Report of a Case and Review of the Literature," *Case Reports in Oncology*, vol. 14, no. 1. S. Karger AG, pp. 123–133, Jan. 01, 2021. doi: 10.1159/000510741.
- [9] R. H. Lurie *et al.*, "NCCN Guidelines Version 5.2020 Breast Cancer," 2020.
- [10] "Simultaneous bilateral invasive breast cancer with coexisting benign phyllodes tumor and lymph node metastasis".
- [11] A. A. Mangi, B. L. Smith, M. A. Gadd, K. K. Tanabe, M. J. Ott, and W. W. Souba, "Surgical Management of Phyllodes Tumors," 1999. [Online]. Available: <https://jamanetwork.com/>
- [12] B. Karczmarek-Borowska, A. Bukala, K. Syrek-Kaplita, M. Ksiazek, J. Filipowska, and M. Gradalska-Lampart, "A rare case of breast malignant phyllodes tumor with metastases to the kidney," *Medicine (United States)*, vol. 94, no. 33, p. e1312, Aug. 2015, doi: 10.1097/MD.0000000000001312.