

Cryptococcal Lymphadenopathy in an 18-year-old Male HIV-infected Patient: A Case Report

Abstract

Introduction: *Cryptococcal neoformans* is an encapsulated fungal pathogen which is contracted through inhalation of the infectious organisms which cause primarily pulmonary disease. The infection remains latent until the host becomes immunocompromised. The disease may disseminate to different sites; however most patients essentially present with brain and lung disease (meningitis and pneumonia, respectively). Cryptococcal lymphadenitis is therefore a very rare occurrence of this infection.

Objective: We describe the clinico-pathological features of an 18-year-old male with vertically transmitted HIV/AIDS infection who presented to our hospital with features of disseminated cryptococcal infection and notable lymph node involvement.

Case Presentation: An 18-year-old secondary school adolescent boy presented to our hospital with a 3-week history of fever, headache, body weakness and marked loss of body weight. He had been recently diagnosed with HIV infection and initiated on antiretroviral therapy (ART). On examination, he was weak, dehydrated and had multiple enlarged lymph nodes and facial skin papules. Notably, laboratory investigations revealed positive India ink test on cerebrospinal fluid (CSF) microscopy examination and culture, positive PAS stain for yeasts on lymph node histopathology and markedly prominent chest lymph nodes on the chest X-ray. A diagnosis of disseminated Cryptococcosis with lymph node involvement was made. He improved on Amphotericin B and oral fluconazole and a repeat CSF culture two weeks later was negative for *Cryptococcus neoformans*.

Conclusion: Cryptococcal lymphadenitis is a rare manifestation of Cryptococcal disease.

Key words: Cryptococcal lymphadenitis, Adolescent, vertical transmission, HIV/AIDS

Introduction:

Cryptococcus neoformans is present in the soil and in birds' droppings, it infects humans when inhaled[1]. Several virulence factors enable it to escape host defences; these include a polysaccharide capsule, melanin production and enzymes. These mechanisms are effective when *C. neoformans* infects hosts with intact immune systems, however, immunosuppressed individuals with deficient host defence mechanisms are afflicted with disseminated disease[2]. The polysaccharide capsule of *C. neoformans* is a major virulence factor, which prevents phagocytosis of cryptococci by alveolar macrophages and inhibits leukocyte migration and recruitment of inflammatory cells[2]. *C. neoformans* can undergo phenotypic switching which leads to changes in the structure and size of the capsule polysaccharide, providing a means to evade immune responses. Acapsular strains are less virulent in animal models[2].

Persons infected with HIV are susceptible to numerous opportunistic infections including cryptococcal disease[3]. HIV/AIDS is the commonest immunosuppressive disease in sub Saharan Africa where two thirds of the world's population living with HIV resides[4]. Numerous efforts have been made by governments including Rwanda to reduce the burden of this disease through scaling up of treatment, prevention and diagnostic capacity. This has been largely driven by huge capital investments by the Global Fund, the U.S. President's Emergency Plan for AIDS Relief (PEPFAR) and other funding agencies in the attempt to reduce new infections to zero. In Rwanda, current HIV prevalence is 3.1% among adults aged 15-49 years[5].

Cryptococcosis is common among ART naïve patients and those who have recently initiated ART and developed the immune reconstitution inflammatory syndrome (IRIS) and it is rapidly lethal when untreated. Previous studies in Rwanda showed that *Cryptococcal neoformans* meningitis was the leading cause of meningitis in HIV-infected patients[6]. All patients with cryptococcal meningitis (CM) tested positive for HIV-1 antibodies. The authors noted that CM was an important opportunistic infection in HIV-infected persons. Notably, many patients with disseminated cryptococcosis did not have lymphadenitis. Lymph node involvement in disseminated cryptococcosis is a very rare occurrence[7]. There are very few reports of cryptococcal lymphadenitis from Africa in the medical literature.

Case presentation

An 18-year-old male Rwandan presented to our Accident and Emergency department with a 3 week history of non-projectile vomiting, fever, mild generalized headache and body weakness. He reported that he had progressively lost weight, had anorexia and night sweats. He did not have any photophobia, cough, diarrhoea, abdominal pain, genitourinary symptoms, joint pain or swelling. He was a secondary school day student who lived with his parents and had been diagnosed with HIV/AIDS four months prior to presentation, with a baseline CD4 count of 8 cells per cubic millilitre. His past surgical history was unremarkable. He was initiated on Antiretroviral Treatment (ART) comprising Lamivudine 300 mg, Tenofovir 300 mg and Efavirenz 600 mg with prophylactic cotrimoxazole 960 mg once daily.

On physical examination, he had a good general appearance although weak and dehydrated. Temperature was elevated at 38°C, tachycardia (pulse rate 106 beats per minute) and a normal blood pressure (114/62 mmHg). His respiratory rate was 16 breaths per minute with an oxygen saturation of 96% (room air). He weighed 62 kg, was alert and well oriented in time, space and person. He had a dry buccal mucosa, no oral thrush, enlarged submandibular, lateral and posterior cervical lymph nodes which were non-tender, firm and mobile. He had right supra orbital and peri-oral umbilicated skin papules, his nerves were intact with no motor or sensory deficit. The lungs were clear on auscultation, the heart sounds were normal with no enlarged liver or spleen. All the other systems were unremarkable. Laboratory investigations showed raised ESR and liver function tests (see table 1). The neurological examination was negative for meningeal signs, CSF positive India ink staining and a positive culture for *Cryptococcus Neoformans*.

Lymph node biopsy showed granulomatous lesions on H & E staining and numerous encapsulated yeast forms which were confirmed on Periodic Acid Schiff (PAS) stain (Fig.2). A Chest radiography revealed right para-hilar and para-tracheal lymphadenopathies with right upper lobe reticular infiltrates (Fig.1) and the abdominal ultrasound done was essentially normal.

A diagnosis of disseminated *cryptococcal neoformans* infection involving the lungs, meninges, skin and the lymph nodes occurring in the setting of Immune Reconstitution Inflammatory Syndrome (IRIS) was made. The patient was initiated on treatment with induction phase intravenous Amphotericin B 0.3 - 0.5 mg/kg/day

and oral fluconazole 800 mg once daily for 14 days with very good clinical response, fever subsided and skin lesions resolved. The patient was discharged and continued on the consolidation phase of his treatment with fluconazole 400 mg once daily for 10 weeks. He continued on ART regimen and prophylactic cotrimoxazole as well. Two weeks later a repeat CSF culture was done which was negative for *Cryptococcal neoformans*. A year later, our patient is fully recovered and well controlled on ART.

Discussion and Review of the Literature

Cryptococcal disease (CD) is a common complication of HIV/AIDS patients in sub Saharan Africa. Although the incidence has reduced with the role out of antiretroviral therapy (ART), it is still seen in a number of patients presenting to emergency departments[8]. Our patient had disseminated cryptococcosis involving the skin, meninges and lymph nodes. AIDS associated lymphadenopathy is commonly due to non-specific follicular hyperplasia, opportunistic infections and malignancy [9]. Lymph node involvement is rarely a feature of disseminated cryptococcosis[2, 10, 11]. In our patient, the initiation of ART for confirmed vertically transmitted HIV infection led to development of the Immune reconstitution inflammatory syndrome (IRIS) and subsequent cryptococcosis.

IRIS is recognized as a complication of HIV treatment which occurs in a number of patients usually within the first three to four months of initiating ART [12]. In our patient, this phenomenon occurred four months post ART. In IRIS, there is restoration of immunity in very immunosuppressed individuals after initiating ART treatment, with a pathological inflammatory response that causes worsening of the clinical presentation. It occurs as a result of restored immunity to specific infectious organisms such as mycobacteria, cryptococcus, herpes zoster, viral hepatitis and cytomegalovirus infections [13].

Our review of the literature has shown very few reports of cryptococcal lymphadenitis[7], most are from the Western world and yet the highest burden of HIV/AIDS is in sub Saharan Africa (SSA). Only 4 cases of cryptococcal lymphadenitis were found in a study that examined 300 lymph node specimens (prevalence 1.3%) [14]. Another retrospective review of 15 cases of cryptococcal lymphadenitis found 10 in immunocompromised patients (8 with HIV/AIDS and 2 post renal transplant patients) [15]. Prior case reports include one case of a 38 year old woman whose HIV infection initially presented as CD with meningeal and lymph node involvement [9] whose presentation is similar to that of our patient. In contrast, there are reports of cryptococcal lymphadenitis at initial diagnosis of HIV infection, but without meningeal, lung or skin involvement [16].

Other reports of cryptococcal lymphadenitis in immunocompromised patients include a 26 year old man with cryptococcal lymphadenitis, but no meningitis, at initial diagnosis of AIDS [13], and a 34 year old male patient who presented with cryptococcal lymphadenitis in the setting of IRIS [17]. He had no meningeal involvement but had raised liver enzymes as was the case in our patient. The raised liver enzymes are thought to be a result of cryptococcal liver infection, which may present as hepatitis, cholangitis or microabscesses. It may also arise from the chronic inflammation secondary to retroviral disease (RVD) or medications [18, 19].

Studies have shown that one third of cryptococcal infections in patients with HIV occur as Immune

Reconstitution Inflammatory Syndromes (IRIS) [17]. Cryptococcal lymphadenitis is rare and commonly presents as cryptococcal IRIS[7, 17]. Due to the severity of this condition, the high mortality and morbidity in low and middle income countries, rapid diagnosis with CSF microscopy and culture, fine needle aspiration biopsy of enlarged lymph nodes, tissue granulomatous lesions and skin snips for skin lesions are recommended. Better patient outcomes have occurred with rapid ART initiation and antifungal therapy: Amphotericin B, 5-flucytosine and fluconazole. Cryptococcal lymphadenitis must be suspected in immunocompromised patients with enlarged lymph nodes. To our knowledge this is the first case of cryptococcal diseases with lymph node involvement reported from Rwanda.

References:

1. Gonzalez-Hein, G., G.-H. J, and D.J. M, *Isolation of Cryptococcus neoformans in dry droppings of captive birds in Santiago, Chile*. J Avian Med Surg 2010. **24**(3): p. 227-36.
2. Srinivasan, R., et al., *Cryptococcal lymphadenitis diagnosed by fine needle aspiration cytology: a review of 15 cases*. ActaCytol, 2010. **54**(1): p. 1-4.
3. Bowen, L., et al., *HIV-associated opportunistic CNS infections: pathophysiology, diagnosis and treatment*. Nat Rev Neurol, 2016. **12**(11): p. 662-674.
4. Kharsany, A. and Q. Karim, *HIV Infection and AIDS in sub-Saharan Africa: Current Status, Challenges and Opportunities*. The Open AIDS Journal, 2016. **10**: p. 34-48.
5. Kayirangwa, E., et al., *Current trends in Rwanda's HIV/AIDS epidemic*. Sex Transm Infect. 2006 Apr; 82: , 2006. **82**((Suppl 1)): p. i27-i31.
6. Bogaerts, J., et al., *AIDS-associated cryptococcal meningitis in Rwanda (1983-1992): epidemiologic and diagnostic features*. J Infect, 1999. **39**(1): p. 32-7.
7. Perfect, J., *Cryptococcosis* Infect Dis Clin North Am 1989. **3**(1): p. 77-102.
8. Michaels, S., R. Clark, and P. Kissinger, *Incidence and spectrum of AIDS-defining illnesses among persons treated with antiretroviral drugs*. Clin Infect Dis, 1999. **29**: p. 468-469.
9. Dogbey, P., M. Golden, and N. Ngo, *Cryptococcal lymphadenitis: an unusual initial presentation of HIV infection*. . BMJ Case Rep., 2013. **2013**(2013): p. doi: 10. 1136/bcr-2013-010316.
10. Shravanakumar, B., et al., *Cryptococcal Lymphadenitis Diagnosed by FNAC in a HIV Positive Individual*. JPGM, 2003. **49**(4): p. 370.
11. Philip, K., et al., *Disseminated cryptococcosis presenting with generalized lymphadenopathy*. J Cytol, 2012. **29**(3): p. 200-202.
12. Sethupathi, M. and K. Yoganathan, *Late Onset of Cryptococcal cervical lymphadenitis following immune reconstitution inflammatory syndrome in a patient with AIDS*. BMJ Case Rep., 2015: p. doi: 10. 1136/bcr-2014-206601.
13. Tahir, M., et al., *Immune reconstitution inflammatory syndrome in a patient with cryptococcal lymphadenitis as the first presentation of acquired immunodeficiency syndrome*. J Postgrad Med. , 2007. **53**(4): p. 250-2.
14. Kamana, N., et al., *Tuberculosis is the leading cause of lymphadenopathy in HIV-infected persons in India: Results of a fine-needle aspiration analysis*. Scand J Infect Dis 2010. **42**(11-12): p. 827-830.
15. Srinivasan R, G.N., Shifa R, Malhotra P, Rajwanshi A, ChakrabartiA. , *Cryptococcal lymphadenitis diagnosed by fine needle aspiration cytology: a review of 15 cases*. ActaCytol, 2010. **54**(1): p. 1-4.

16. Verma, A., S. Sinha, and A. Verma, *Cryptococcal lymphadenitis diagnosed on FNAC – Primary manifestation in AIDS patients*. Int J Med Sci Pub Health, 2016. **5**(12): p. 2641-2.
17. Putignani, L., et al., *Cryptococcal lymphadenitis as a manifestation of immune reconstitution inflammatory syndrome in an HIV-positive patient: a case report and review of the literature*. . Int J Immunopath Pharm 2008. **21**(3): p. 751-6.
18. Shukla, S., et al., *Liver dysfunction as the presenting feature of disseminated cryptococcosis*. S Afr J Infect Dis, 2016. **31**(2): p. 38-41.
19. Liu, P., Y. Yang, and Z. Shi, *Cryptococcal liver abscess: a case report of successful treatment with amphotericin-B and literature review*. Jpn J Infect Dis, 2009. **62**(1): p. 59-60.

Table 1: Showing laboratory investigation results.

White Blood Cell Count	8.3x10 ⁹ /L	4.00	11.00
Erythrocyte Count	5.09x10 ¹² /L	3.80	6.50
Haemoglobin	14.4gms/dl	10	18.00
Haematocrit	42.7vol%	36.00	54.00
MCV	84fl	76.00	96.00
MCH	28.2pg	27.00	32.00
MCHC	33.6gms/dl	31.00	35.00
Neutrophils (Absolute)	5.87x10 ⁹ /L	2	7.5
Lymphocytes (Absolute)	1.54x10 ⁹ /L	1.5	4
Monocytes (Absolute)	0.74x10 ⁹ /L	0.2	0.8
Eosinophils (Absolute)	0.11x10 ⁹ /L	0.04	0.4
Basophils (Absolute)	0.06x10 ⁹ /L	0.02	0.1
Platelet Count	389x10 ⁹ /L	150.00	450.00
Erythrocyte sedimentation Rate	34-mm/hr	0	20
Conjugated Bilirubin	0.0µmol/L	0.00	7.00
Total Protein	83gms/L	60.00	80.00
ALBUMIN	29gms/L	36.00	50.00
Alkaline Phosphatase	362 IU/L	53.00	128.00
Lactate Dehydrogenase	256 IU/L	135	225
Total Bilirubin	7.2µmol/L	6.00	24.00
Aspartate aminotransferase (AST)	26 IU/L	10.00	50.00
Alanine aminotransferase (ALT)	27 IU/L	10.00	50.00
Gamma GT	372 IU/L	11.00	50.00
Sodium	134 mmol/L	135.00	145.00
Potassium	5.1mmol/L	3.5	5.5
Chloride	93mmol/L	95.00	105.00
Total CO ₂	21mmol/L	18.00	29.00
Urea	6.9mmol/L	2.50	7.50

Creatinine

92mol/L

60

130

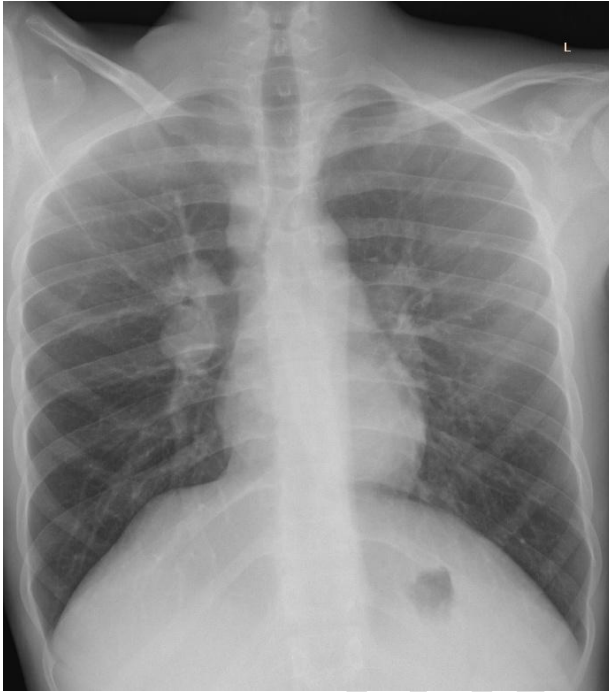


Figure 1: Posterior-Anterior X-ray shows right paratracheal & right para-hilar lymphadenopathy with right upper lobe reticular infiltrates suggestive of lung infection with cryptococcal pneumonitis

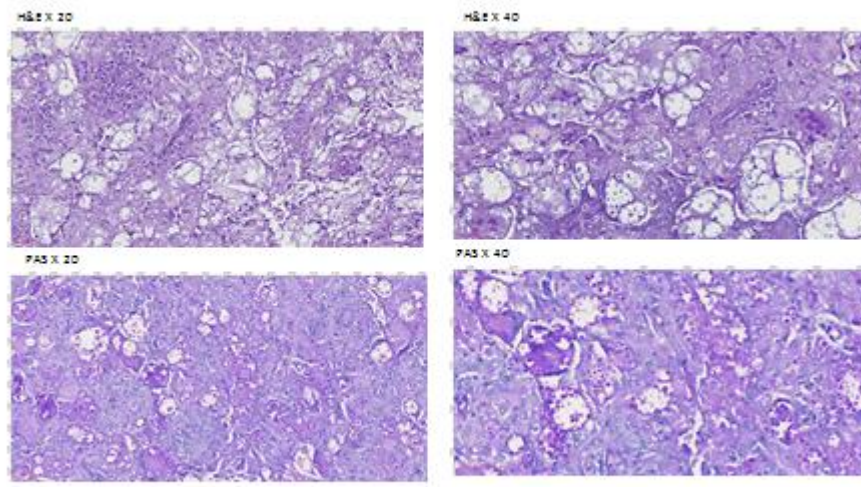


Figure 2: Shows a lymphohistiocytic background with several spherical structures surrounded by halos indicative of cryptococcus