

Comment [D1]:

- Authors please recheck for spelling and grammar mistakes.
- Authors please go through the authors guidelines in SDI and AJCRS web sites.

Unusual cause of colonic occlusion: large, twisted ovarian cyst compressing the sigmoid colon

Abstract:

Bowel obstruction is a common complication of advanced ovarian cancer, and is rarely described in benign cystic lesions. We report a case of colon obstruction secondary to torsion of a large benign ovarian cyst.

Case presentation: A 25-year-old woman without antecedents was admitted to hospital for sigmoid colon occlusive syndrome. A CT scan revealed a large cyst probably of ovarian origin, resulting in compression of the sigmoid colon. After conditioning, we performed an exploratory laparotomy, revealing a twisted and necrotic right ovarian cyst compressing the recto-sigmoid hinge with its root. A straight ~~annexectomy~~ adnexectomy was made, the histological findings confirmed the presence of a benign functional ovarian cyst. The hospital stay was uneventful and the symptoms of bowel obstruction were resolved immediately. ~~A torsion~~ Torsion of an ovarian cyst is not described as a cause of colon obstruction so far in the medical literature.

Comment [D2]:

- Immediately after abstract please write 4-8 keywords in MeSH terms in alphabetical order other than those mentioned in the title.

Introduction :

Bowel obstruction accounts for 42% of the complications of advanced ovarian cancer. Although ovarian teratomas and endometriosis can also cause bowel damage, this condition is rarely described in cystic ~~benign~~ benign lesions [1, 2]. We report one case of bowel obstruction due to a large, twisted functional ovarian cyst compressing the recto-sigmoid hinge.

Case Presentation:

A 25 year old woman with no pathological history, admitted urgently for an occlusive syndrome that has been evolving for 3 days. Clinical examination found tympanic abdominal distension with pelvic tenderness, the rectal ampulla was empty on rectal examination. A PSA objectively showed colicky water-aerobic levels. CT scan confirmed colonic occlusion upstream of a large cyst probably of ovarian origin measuring 18X12 cm (Figure 1). Exploratory laparotomy revealed the presence of a large ovarian cyst measuring 20 x 15 cm (Figure 2), twisted into two turns of coils with total necrosis of the right adnexa, compressing the recto-sigmoid hinge by its root, with the presence of a zone of constriction (Figure 3), causing colic and hial distension upstream. A right annexectomy was performed and the obstacle was removed (Figure 4). The postoperative course was straightforward. Histological examination was in ~~favour~~ favor of a functional benign ovarian cyst.

Discussion:

To our knowledge, this is the first reported case of a twisted benign ovarian cyst causing bowel obstruction in a patient during genital activity. There is no consensus definition [2, 3]. Adnexal torsion may be defined by the existence of at least one turn of the adnexa around an axis defined by the lumbo-ovarian ligament and tubo-ovarian ligament. It may involve the tube and the ovary, the ovary alone and less frequently, and the tube alone [4].

The diagnostic reference is the intraoperative visual finding, so the exact prevalence of adnexal torsions cannot be estimated since not all women with pelvic pain have systematic laparoscopy. In patients operated on in emergency for acute pelvic pain, it is estimated to be between 2.5 and 7.4% depending on the series. [1, 5]

The right side is most frequently affected, in 60% of cases on average. This could be explained by a right utero-ovarian ligament physiologically longer than on the left, however there is no anatomical data, or by the presence of the sigmoid on the left reducing the space required for torsion. Pelvic pain is the main reason for consultation in 96 to 100% of cases. The association with an occlusive syndrome is not described.

Conclusion:

Exploratory laparotomy has revealed a rare or even exceptional cause of colonic mechanical occlusion associated with torsion of a benign ovarian cyst.

Figures :

- Figure 1: CT image showing a large ovarian cyst in pelvic position exerting a mass effect on the recto-sigmoid hinge.
- Figure 2: Intraoperative image showing a large, twisted, necrotic ovarian cyst with colonic compression.
- Figure 3: Intraoperative image showing the area of constriction at the recto-sigmoid hinge after deterosiondistortion of the cyst.
- Figure 4: Image of the right adnexectomy specimen

References :

- [1] Mechera R, Menter T, Oertli D, Hoffmann H. Large ovarian cystadenofibroma causing large bowel obstruction in a patient with Klippel-Feil syndrome-A case report. *Int J Surg Case Rep.* 2016;20:17-20. doi: 10.1016/j.ijscr.2015.12.046. Epub 2016 Jan 7.
- [2] Mooney SJ, Winner M, Hershman DL, Wright JD, Feingold DL, Allendorf JD et al., Bowel obstruction in elderly ovarian cancer patients: apopulation-based study. *Gynecol Oncol.* 2013Apr;129(1):107–112. doi: 10.1016/j.ygyno.2012.12.028

Comment [D3]:

•The references should be in Vancouver style. For full details on this refer to the following link to university of Queensland
(<http://www.library.uq.edu.au/training/citation/vancouv.pdf>)

•In text citations of references must be within square brackets before punctuation in the order of their first appearance in the main text

•References list also must be numbered in square brackets

•References cited only in tables or figure legends should be numbered in accordance with the sequence established by the first identification in the text of the particular table or figure.

•The titles of journals should be in italics and abbreviated according to the style used in Index Medicus/NLM journal abbreviation directory.

- [3] Al-Harfoushi R, Abdulaziz el-H, Andrabi SI, Patterson B, Whiteside M. Ovarian teratoma presenting as small bowel obstruction in an elderly lady-A case report. *Int J Surg Case Rep.* 2011;2(1):6-8. doi: 10.1016/j.ijscr.2010.07.004.
- [4] Lanitis S, Korontzi M, Karaliotas C. Acute bowel obstruction in a premenopausal woman. *Gastroenterol* 2013 Jan;144(1):e5-6. doi: 10.1053/j.gastro.2012.08.040.
- [5] Chapron C, Fauconnier A, Fritel A, Dubuisson JB. Acute pelvic pain in women. Diagnostic orientation and course of action. In: CME Gynecology; 1998. p. 162-A-15.
1. R. Meeheraa, T. Menterb, D. Oertlia, H. Hoffmann. Large ovarian cystadenofibroma causing large bowel obstruction in a patient with Klippel-Feil syndrome—A case report. *Int J Surg Case Rep.* 2016;20:17-20.
2. S.J. Mooney, M. Winner, D.L. Hershman, J.D. Wright, D.L. Feingold, J.D. Allendorf, et al., Bowel obstruction in elderly ovarian cancer patients: a population-based study, *Gynecol. Oncol.* 129 (April (1)) (2013) 107–112.
3. R. Al-Harfoushi, E. H. Abdulaziz, S.I.H. Andrabi, B. Patterson, M. Whiteside. Ovarian teratoma presenting as small bowel obstruction in an elderly lady—a case report, *Int. J. Surg. Case Rep.* 2 (January (1)) (2011) 6–8.
4. S. Lanitis, M. Korontzi, C. Karaliotas, Acute bowel obstruction in a premenopausal woman, *Gastroenterology* 144 (January (1)) (2013) e5–e6.
5. C. Chapron, A. Fauconnier, A. Fritel, JB. Dubuisson. Acute pelvic pain in women. Diagnostic orientation and course of action. In: CME Gynecology; 1998. p. 162 A-15.

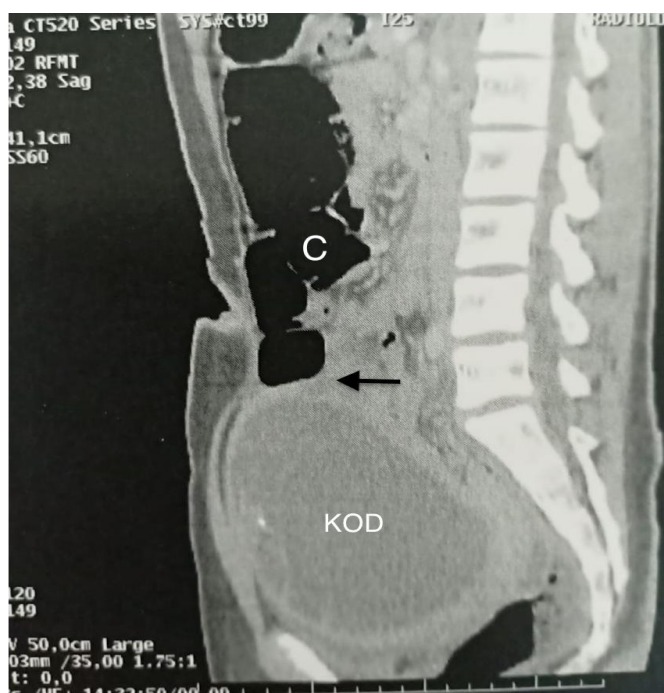
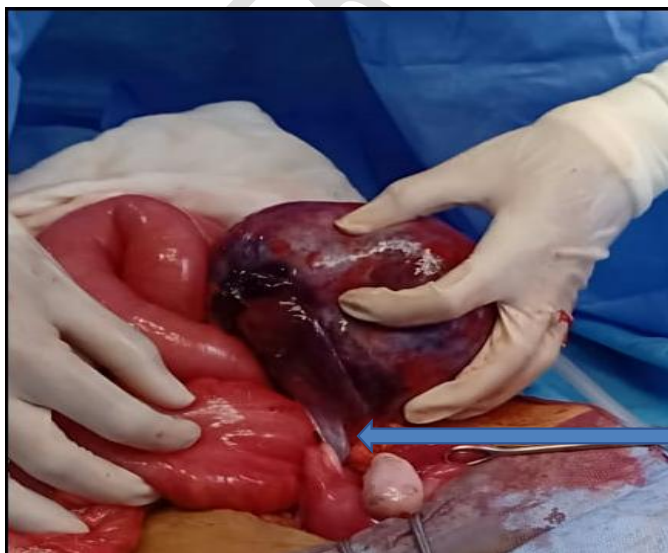


Figure 1: CT image showing a large pelvic ovarian cyst (KOD) with a mass effect on the recto-sigmoid hinge: (arrow)



Arrow indicating the torsion of the cyst with 2 turns of coils compressing the recto-sigmoid hinge.

Figure 2: Image showing a large, twisted, necrotic ovarian cyst with colonic compression.

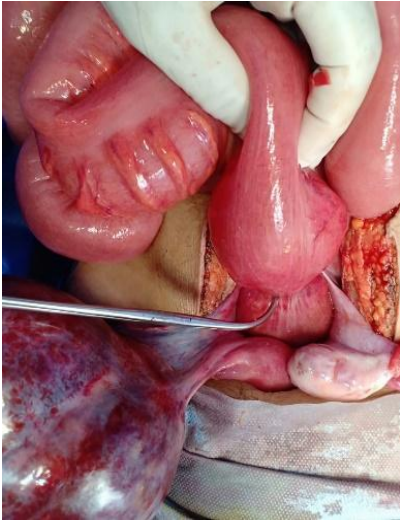


Figure 3: Image showing the area of constriction at the recto-sigmoid hinge.
Bengolea clamp indicating the strangulation zone

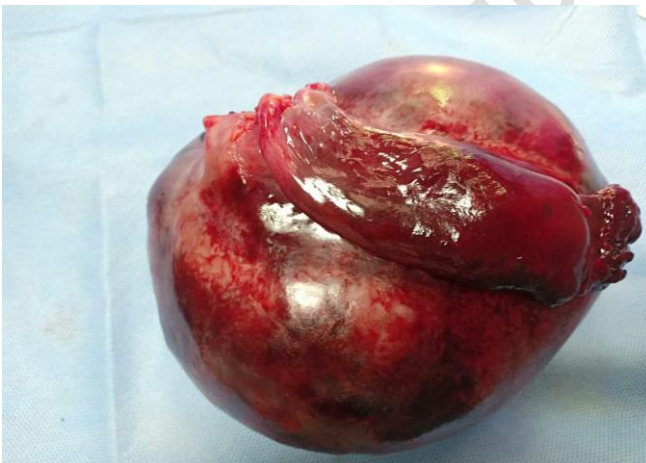

Figure 4: Image showing the right ~~adnexectomy~~ ~~annexectomy~~ specimen